

HALLUX RIGIDUS

*Nikolaus WULKER**

INTRODUCTION

The term hallux rigidus describes painful and decreased motion at the metatarsophalangeal joint of the great toe. This causes discomfort particularly when the toe is dorsiflexed at push-off during ambulation. Most commonly, degenerative arthritis of the metatarsophalangeal joint is the underlying condition. However, other disorders such as osteochondrosis dissecans of the first metatarsal head may also cause hallux rigidus.

The clinical condition of hallux rigidus was first described by Nicoladoni¹ in 1881 and by Davies-Colley². The term "hallux rigidus" was introduced by Cotterill³. "Halluk limitus" has also been used to describe painful limitation of dorsiflexion of the great toe^{4,5}, in particular if this is less advanced. Other terms for the same condition are hallux arthriticus⁶ and hallux equinus^{7,8}.

Hallux rigidus is slightly more common in women than in men^{9,10}, in particular at a younger age¹¹⁻¹³. Hallux rigidus often occurs bilaterally, particularly in younger patients^{12,14,15}.

CLINICAL AND RADIOGRAPHIC APPEARANCE

Stage I

Patients complain of impaired push-off of the great toe when walking. Clinical findings at this stage may be non-specific. Motion may be painful in all directions. Patients avoid the great toe during gait and walk over the lateral border of the foot. Radiographs at this stage usually reveal no abnormality, except for occasional flattening of the first metatarsal head.

Stage II

Degenerative arthritis initiates at the dorsal segment of the first metatarsophalangeal joint, where mechanical stress is most pronounced. On physical examination, dorsiflexion is markedly decreased or absent. Crepitus at the first

metatarsophalangeal joint may be palpable on forced dorsiflexion. An osteophyte is often palpable at the dorsal surface of the first metatarsal head and sometimes at the proximal phalanx. Dorsoplantar radiographs at this stage reveal joint space narrowing and subchondral bone density (Fig. 1a). Osteophytes at the lateral and medial border of the joint may be seen. Lateral radiographs demonstrate joint space narrowing (Fig. 1b), which is often limited to the dorsal portion of the joint, with normal or only slightly decreased width of the plantar joint space.

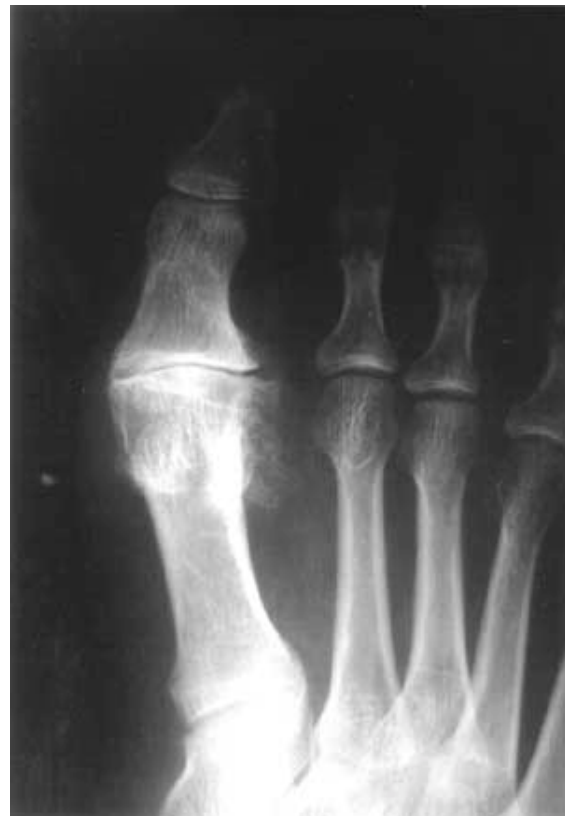

Figure 1a: Stage II hallux rigidus: a) The dorsoplantar radiograph demonstrates joint space narrowing with osteophyte formation at the lateral and medial aspect of the first metatarsal head.

* From the Orthopaedic Department, Hannover Medical School, Hannover, Germany.

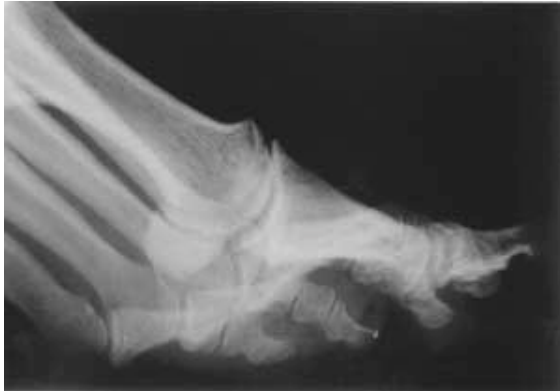

Figure 1b: Stage II hallux rigidus: b) On the lateral radiograph, joint space narrowing is most pronounced at the dorsal segment of the joint. The width of the plantar joint space is still preserved. Beginning osteophyte formation is noted at the dorsal aspect of the first metatarsal head.

Stage III

Degenerative arthritis of the first metatarsophalangeal joint has fully developed. Metatarsophalangeal joint motion is further decreased, at times with a plantarflexion contracture of the great toe. Crepitus is often found. A large osteophyte can usually be palpated at the dorsal aspect of the first metatarsal head, which may lead to pressure against the shoe and give raise to the clinical appearance of a dorsal bunion. Radiographs reveal advanced degenerative arthritis of the first metatarsophalangeal joint with complete obliteration of the joint space, including the dorsal segment (Fig. 2a,b). A large osteophyte at the dorsal surface of the first metatarsal head may fracture and remain as a loose fragment.

NONOPERATIVE TREATMENT

In the early stage of hallux rigidus, conservative treatment to decrease inflammation often yields pain relief for extended periods. Cold treatment with ice packs and sprays may be used. Topical analgesic medication may markedly diminish pain and inflammation. Other physical therapy applications, such as high frequency electric field treatment and ultrasound may also be used. If symptoms are more severe intraarticular injection treatment may be helpful.

Rehabilitation exercises are not usually helpful in hallux rigidus. Motion exercises are generally not able to overcome the limitation of dorsiflexion, and symptoms may be worsened, if a forceful attempt

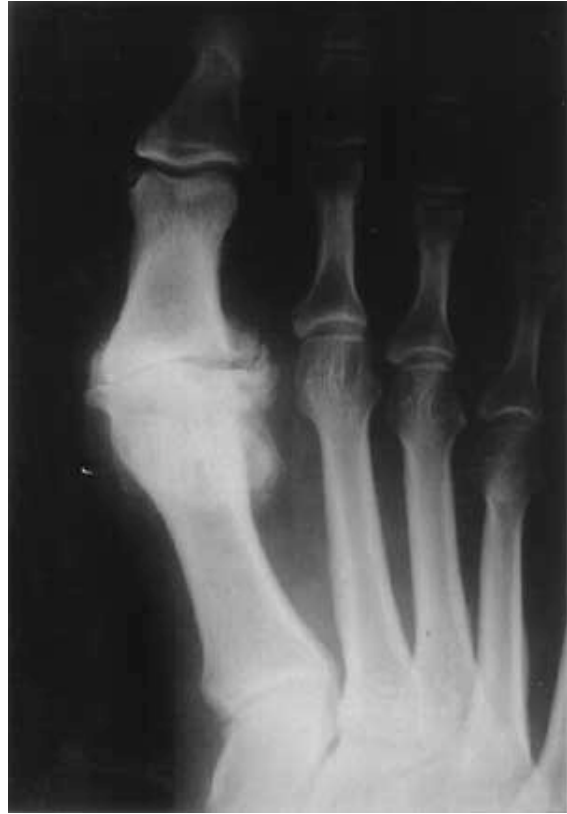

Figure 2a: Stage III hallux rigidus with complete destruction of the metatarsophalangeal joint. a) On the dorsoplantar radiograph, the joint is completely obliterated. Osteophytes are present at the lateral and medial aspect of the first metatarsal head.

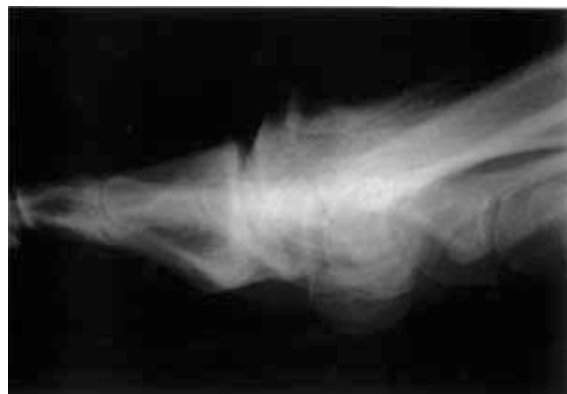

Figure 2b: Stage III hallux rigidus with complete destruction of the metatarsophalangeal joint. b) On the lateral radiograph, the entire joint space is destroyed. A large osteophyte is noted at the dorsal aspect of the first metatarsal head.

to restore a normal range of motion at the metatarsophalangeal joint is made.

Insoles with an in-built metal bar underneath the great toe absorb some of the energy at the

metatarsophalangeal joint during push-off. Transverse metatarsal bars, built into the sole under the metatarsal head region, decrease the load at the metatarsophalangeal joint.

SURGICAL TREATMENT OF HALLUX RIGIDUS

Hallux rigidus patients differ with respect to their age, their activities of daily living and with respect to their expectations from the operative intervention. Not one single procedure is suited for all patients. A decision making process is required to select the optimum treatment for each individual patient.

For the intermediate stage of hallux rigidus, cheilectomy is a relatively non-invasive surgical procedure that offers a high rate of success. Its major advantage is the fact that arthrodesis of the first metatarsophalangeal joint or resection arthroplasty are still possible, should they become necessary at a later time. In the experience of the author, other joint preserving procedures for the treatment of hallux rigidus, such as the dorsiflexion osteotomy of the proximal phalanx^{9,16,45}, are technically more difficult and have a higher incidence of complications, but are no more successful than cheilectomy. Dorsiflexion osteotomy, however, may be used in addition to cheilectomy.

In the late stage of hallux rigidus, operative techniques that preserve the metatarsophalangeal joint are no longer successful. Arthrodesis and occasionally resection arthroplasty of the first metatarsophalangeal joint are the treatment of choice. Arthrodesis allows the great toe to be fitted into regular shoes and to be used during push-off, without interfering during ambulation. Arthrodesis is the more functional procedure, compared to resection arthroplasty of the first metatarsophalangeal joint. In elderly and less active patient, resection arthroplasty may be used as an alternative.

Resection arthroplasty of the proximal phalanx has often been the preferred treatment for all stages and variants of hallux rigidus in Europe. As a joint destructive procedure, which permanently and severely compromises the function of the great toe, resection arthroplasty is indicated only in the exceptional hallux rigidus patient. Other techniques are much better suited to restore painfree function of the great toe on a long-term basis.

Regnauld¹⁷ used a resection arthroplasty to treat hallux rigidus, in which the base of the proximal

phalanx was shaped as a peg and fitted into the caved out diaphysis of that bone. In view of a recurrence rate of up to 80 percent¹⁸, this technique can not generally be recommended. Subcapital dorsiflexion osteotomy of the first metatarsal has also been recommended¹⁹⁻²¹, but this is technically more difficult than cheilectomy or osteotomy of the proximal phalanx. Removal of osteophytes alone for the treatment of hallux rigidus^{22,23} does not usually obtain long-term relief of symptoms.

Arthrodesis of the first tarsometatarsal joint was used by several authors who considered metatarsus primus elevatus, i.e. dorsiflexion deformity of the first metatarsal, the main aetiology of hallux rigidus^{19,24,25}. However, no proof of this aetiology exists and the sacrifice of a health joint is usually not warranted.

Of historical interest are the remodelling arthroplasty^{12,26,27}, using fascia lata to cover the surfaces of the metatarsophalangeal joint, and closed manipulation of the great toe under anaesthesia^{1,7,12,28,29}. Plantar soft tissue release^{2,28,30}, including transection of the short flexor muscles of the hallux and the plantar aspect of the joint capsule, is not usually successful to relieve long-term symptoms.

Endoprosthetic replacement of the first metatarsophalangeal joint has been more successful in hallux rigidus than in hallux valgus^{6,31,32}. However, the complication rate in hallux rigidus is still considerable^{6,32}. Silastic implants, which were initially developed by Swanson³³, are now used less frequently, after foreign body reactions, osteophyte formation, periarticular ossifications and new bone formation at the resection surfaces have increasingly been reported^{32,34,35}. In the experience of the author, the results of cheilectomy and of arthrodesis of the first metatarsophalangeal joint are more favourable than those of endoprosthetic replacement in hallux rigidus.

The most important contraindication to hallux rigidus surgery is compromised peripheral vascular perfusion. Palpation of both pedal pulses is mandatory before the operation.

CHEILECTOMY

Cheilectomy was first described by DuVries⁴ and subsequently recommended in particular by Mann and Clanton³⁶. This technique is only indicated in the intermediate stage of hallux rigidus, i.e. if

sufficient articular cartilage are still intact at the first metatarsal head and of the proximal phalanx. It does not obstruct subsequent arthrodesis or resection arthroplasty of the first metatarsophalangeal joint, should they become necessary at a later time.

Operative Technique

The incision is centred dorsally over the metatarsophalangeal joint and can be carried directly onto the bone, dividing the periosteum and the joint capsule. The first metatarsal head and the base of the proximal phalanx are exposed. The joint cartilage is examined following forced plantarflexion of the great toe. Most commonly, there will be worn cartilage at the dorsal aspect of the first metatarsal head and better preserved cartilage on the plantar side, usually the plantar two thirds of the head (Fig. 3a). Dorsally and occasionally laterally and medially, an osteophyte is often found. Sometimes, loose bodies within the joint must be removed. Synovectomy at the

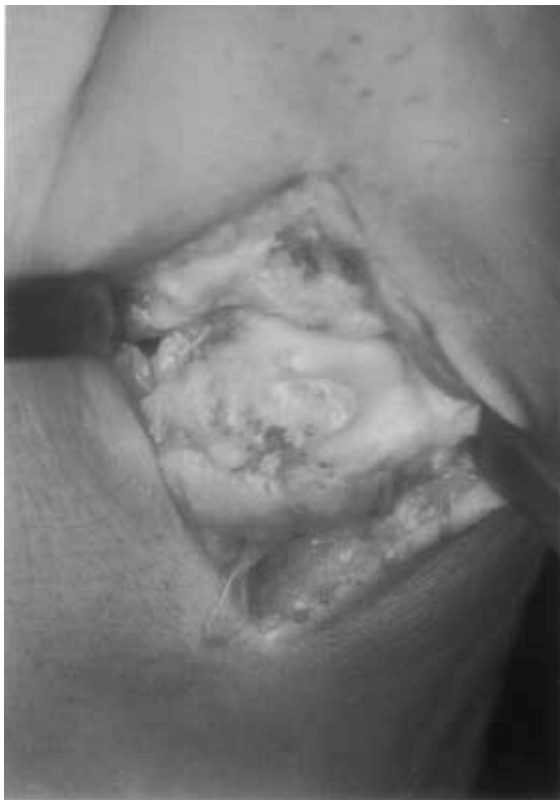

Figure 3a: Prior to cheilectomy, the preserved articular cartilage at the plantar segment of the first metatarsal head is clearly demarcated from the eburnated subchondral bone surface at the dorsal aspect.

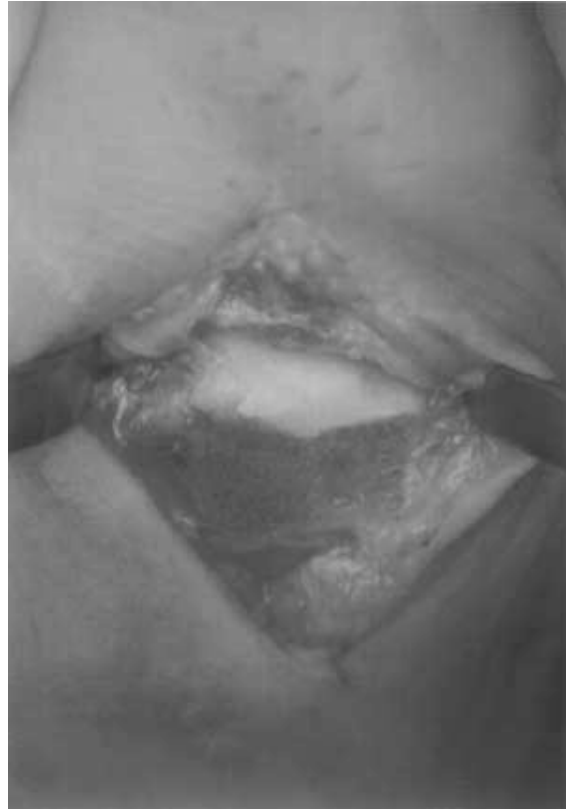

Figure 3b: Resection surface following cheilectomy.

exposed portion of the joint may have to be performed prior to bone resection.

Cheilectomy is performed with a small osteotome. The osteotomy begins at the dorsal surface of the first metatarsal head, proximal to an osteophyte which may be present, and is directed to the dorsal margin of the intact articular surface at the first metatarsal head (Fig. 4). Generally, the osteotomy is angled slightly in a plantar direction to the dorsal aspect of the first metatarsal diaphysis (Fig. 5). Approximately the dorsal one third of the first metatarsal head is removed (Fig. 3b). If more bone is resected, the first metatarsophalangeal joint may become unstable. If not enough bone is resected, there may still be painful bone contact, leading to continuing symptoms and to recurrence of hallux rigidus. Additional osteophytes at the medial and lateral aspect of the first metatarsal head and at the base of the proximal phalanx are also removed. Following bone resection, a periosteal elevator is used to divide adhesions between the sesamoids and the first metatarsal head. Following this maneuver, the great toe must be brought into approximately 60 degrees of dorsiflexion. If this

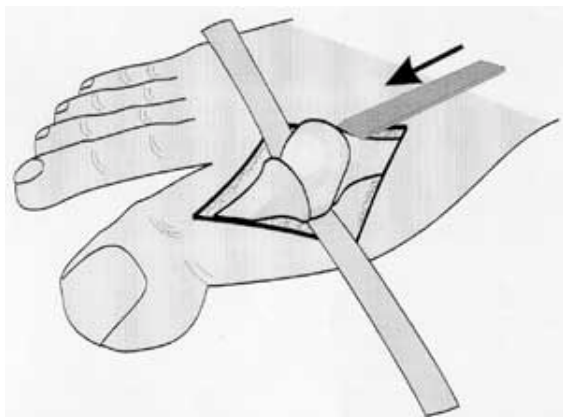


Figure 4: Technique of cheilectomy. An osteotome is used for resection of the dorsal one third of the first metatarsal head, including a dorsal osteophyte.

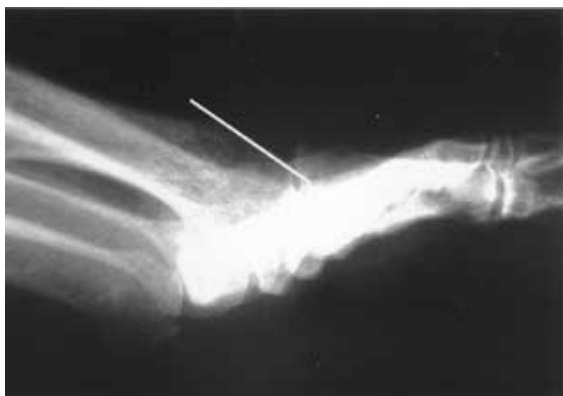

Figure 5: Postoperative lateral radiograph following cheilectomy. The resection surface (white line) is angled slightly in a plantar direction relative to the dorsal surface of the first metatarsal diaphysis.

can not be achieved without excessive force, the capsule must further be detached with a periosteal elevator, or more bone must be resected. The wound is closed in two layer.

Postoperatively, the patient is mobilized with full weightbearing of the operated foot immediately postoperatively. A postoperative shoe may be used until the wound has healed, but this is not mandatory. Passive and active motion exercises of the first metatarsophalangeal joint are begun on the first postoperative day. The sutures are removed 14 days after surgery. At this time, normal shoes can almost always be worn.

Results

In the author's experience of 28 cheilectomies reviewed after 12 to 48 months (mean 20 months)³⁷, 24 were satisfied with the procedure.

Four patients complained of pain after extended weight-bearing. Mean dorsiflexion of the first metatarsophalangeal joint increased from 12° preoperatively to 25° postoperatively. Dynamic pedobarography revealed an almost complete return of normal weight-bearing of the great toe.

Mann et al.³⁸ reported minor residual symptoms in three of 20 patients 68 months (seven to 156 months) postoperatively. Mean dorsiflexion at the metatarsophalangeal joint was 30 degrees. Gould³⁹ found 20 degrees or more of dorsiflexion in twelve patients two to four years following cheilectomy, with an average of 32 degrees. All patients were able to return to their activities prior to the onset of symptoms and all were able to wear normal shoes. Hattrupp and Johnson⁴⁰ followed 58 feet after 38 months (eight to 97 months). In early degeneration with small to medium size osteophytes and with a largely preserved width of the joint space, 85 percent of all patients were satisfied with the result. Mann and Clanton³⁶ examined 25 patients after 56 months (30 to 100 months). All except three were asymptomatic. Joint motion increased 20 degrees on average. No complications occurred.

ARTHRODESIS OF THE FIRST METATARSOPHALANGEAL JOINT

The first description of metatarsophalangeal joint fusion was by Broca in 1852⁴¹. Clutton⁴² recommended this technique in 1894 and reported a successful outcome in seven patients. Today, arthrodesis of the first metatarsophalangeal joint is the standard procedure for hallux rigidus with advanced destruction of the joint surfaces.

Operative Technique

The skin incision is midline at the dorsal aspect of the metatarsophalangeal joint. If the arthrodesis is stabilised with a dorsal plate, the incision reaches distally to the interphalangeal joint and for the same distance in a proximal direction. The incision can be carried through the periosteum and the capsule directly onto the bone. Osteophytes, which are commonly found at the first metatarsal head and at the proximal phalanx, are removed.

Position of the Arthrodesis

Following the arthrodesis, the great toe must be in a position to allow weightbearing at push-off during gait and to fit comfortably into a regular shoe. This requires ten to 15 degrees of dorsiflexion

relative to the sole of the foot, i.e. relative to the ground when walking (Fig. 6a). In women who wear high heeled shoes, the angle can be increased to 20 degrees. This dorsiflexion angle is smaller than the angle between the first metatarsal and the proximal phalanx, which is between 15 and 30 degrees. In addition one must take into consideration that the proximal phalanx is thicker at its proximal metaphysis than at the diaphysis. In a correct position of the arthrodesis, the angle between the dorsal surfaces of the first metatarsal and of the proximal phalanx is between zero and 10 degrees of dorsiflexion. The medial-lateral alignment of the great toe should be in 10 degrees of valgus, so that the great toe just touches the second toe (Fig. 6b).

The proximal osteotomy is made with an oscillating saw at a valgus angle of 10 degrees to the shaft axis of the first metatarsal. In the sagittal plane, it should be at a right angle to the bottom of the foot. Just enough bone is resected to obtain a flat surface of adequate size and to reach the cancellous bone of the first metatarsal head. If too much bone is resected, the great toe will be excessively shortened by the operation.

The surgeon then holds the great toe with one hand and places it in the position desired for the arthrodesis. The osteotomy at the proximal phalanx is made parallel to the osteotomy at the first metatarsal head. The arthrodesis is then temporarily stabilised with Kirschner wires, which must not interfere with the screws used for subsequent fixation.

Cone shaped bone surfaces were used by a number of authors⁴³⁻⁴⁹. This configuration adds to the stability of the arthrodesis but shortens the great toe. Wedge-shaped osteotomies were employed by Geiser⁵⁰ and by Harrison and Harvey⁵¹. Turan and Lindgren⁵² recommended flat osteotomy surfaces tilted 30 degrees into a

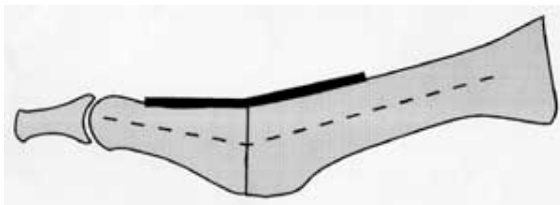


Figure 6a: Technique of arthrodesis of the first metatarsophalangeal joint. The position of the arthrodesis must be in slight dorsiflexion, relative to the bottom of the foot, and in some valgus. a) medial aspect.

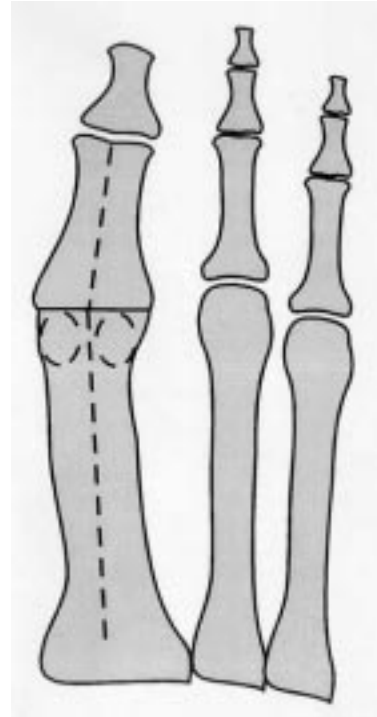


Figure 6b: Technique of arthrodesis of the first metatarsophalangeal joint. The position of the arthrodesis must be in slight dorsiflexion, relative to the bottom of the foot, and in some valgus. b) dorsal aspect.

lateral-proximal direction, to facilitate internal fixation with screws. Coughlin⁵³ and Holmes¹⁴ introduced cup-shaped power-driven reamers for convex reaming of the first metatarsal head and concave reaming of the base of the proximal phalanx. Bone resection is minimal, because the curvature of the reamers approximately corresponded to the natural shape of the articular surfaces.

Fixation of the arthrodesis

The most stable method of fixation is a dorsal one-third or one-quarter tubular small fragment plate, with additional interfragmentary screw fixation (Fig. 7)^{32,53}. The dorsal surface of the first metatarsal and the proximal phalanx are cleared of soft tissue. In the correct position of the arthrodesis, the plate has to be bent dorsally less than 10 degrees. This should be slightly less than the angle between the dorsal surfaces of the first metatarsal and the proximal phalanx, as this provides additional compression at the plantar side of the arthrodesis. Four or five hole one third or one quarter tubular plates or other small plates are equally well suited for fixation. Following removal of the temporary Kirschner wires, an

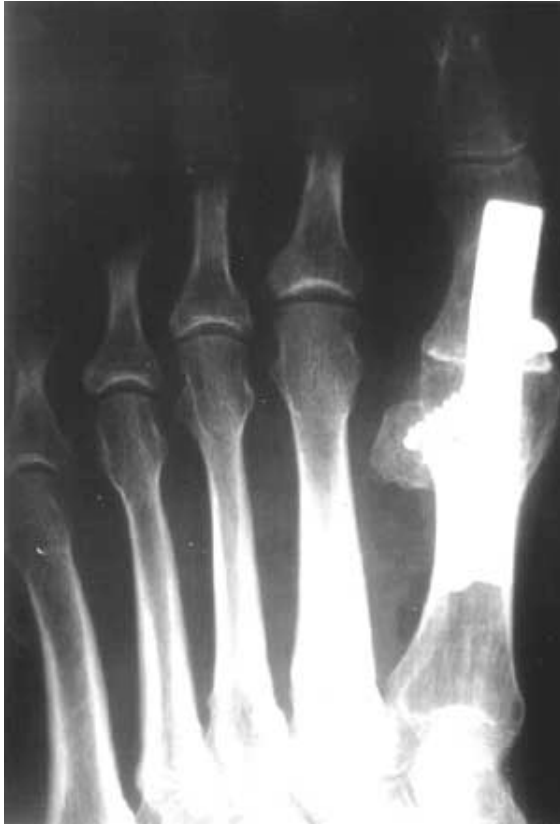

Figure 7a: Postoperative radiograph of arthrodesis with dorsal plate fixation. a) dorsoplantar radiograph.

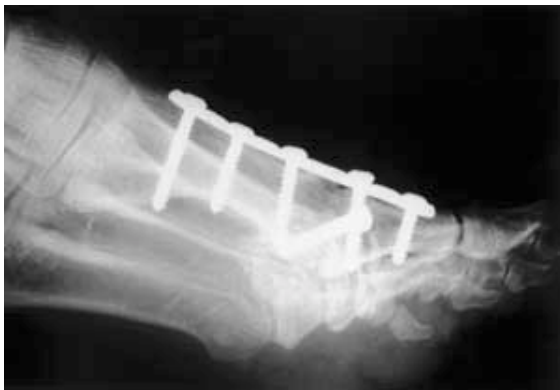

Figure 7b: Postoperative radiograph of arthrodesis with dorsal plate fixation. b) lateral radiograph.

additional small fragment lag screw is placed from distal to proximal, entering either medially or laterally at the proximal phalanx. The cortical bone of the proximal phalanx is usually quite thin.

Fixation with screws alone is an alternative^{43,44,47,50,52,54,55}, in particular if the

configuration of the bone surfaces provides some inherent stability, as in the cone or wedge shaped arthrodesis. McKeever⁴⁶ and Lipscomb⁵⁶ used a relatively long screw, which entered at the plantar surface of the proximal phalanx and reached almost to the first tarsometatarsal joint.

Other methods of stabilisation include external fixation^{51,57}, Steinmann pins or rush nails^{15,58,59}, Kirschner wires^{55,60-63}, wire sutures^{47-49,64}, absorbable sutures⁶⁵, bone pegs⁶⁶ and bone staples^{55,56}.

The wound is closed in two layers, in order to provide adequate soft tissue coverage. The skin is closed with interrupted sutures.

Postoperatively, the patient can be mobilised in a rigid postoperative shoe with full weightbearing immediately postoperatively, if dorsal plate fixation was used. The sutures are removed 14 days postoperatively. The postoperative shoe is used until six weeks after the operation. The metal implants may be removed after one year. In fixation with screws alone, temporary immobilization may be advised in view of the higher rate of nonunion with this technique.

Results

Henry and Waugh⁶⁷ performed plantar pressure measurements in 85 arthrodeses and compared the results to 85 patients following resection arthroplasty. In 80 percent of the arthrodeses, the great toe was put to use during push-off, compared to 40 patients following resection arthroplasty. An increased load under the second to fourth metatarsal heads was measured in 66 percent of the arthrodeses and 78 percent of the resection arthroplasties.

Geiser⁵⁰ reported 116 arthrodeses in 89 patients one to eleven years postoperatively. Most procedures were performed for hallux rigidus. The result was good and excellent in over 90 percent, only six patients were unsatisfied with the operation. In six patients, the arthrodesis was in an unfavourable position, Ten patients underwent simultaneous resection arthroplasty at the contralateral side. Of these, four patients favoured the arthrodesis, five were undecided and one patient favoured the resection arthroplasty.

Salis-Soglio and Gebler-Rothlaender⁶⁷ examined 95 arthrodeses with dorsal plate fixation in 76 patients after 38 months. 79 patients had an excellent and good subjective result, 14 percent

fair and seven percent poor. 70 percent of all patients active in sports could return to their previous athletic activity. Complications occurred in eleven percent, such as delayed wound healing, persistent swelling or venous thrombosis.

Complications

The incidence of pseudarthrosis depends on the method of fixation. Moynihan⁴⁷, who used only one screw, reported a rate of 13 percent. Chana et al.⁶⁵, who used only absorbable sutures, reported ten percent. If a dorsal plate was used, the incidence of pseudarthrosis was between zero and six percent^{36,53,67}. Most pseudarthroses cause only mild symptoms and do not require revision.

Degenerative arthritis of the interphalangeal joint was observed radiographically in 25 percent of arthrodeses twelve years postoperatively, 15 percent without symptoms and ten percent with symptoms⁶⁰. Coughlin⁵³ reported an increase of symptoms at the interphalangeal joint with increasing time postoperatively. Salis-Soglio⁶⁷ found no evidence of degeneration in 250 patients, more than three years on average after surgery.

REFERENCES

- Nicoladoni C. Über Zehenkontrakturen. Wiener klin Wochenschrif. 1881; 51: 1418-9.
- Davies-Colley N. Contraction of the metatarso-phalangeal joint of the great toe (hallux flexus). Br Med J 1887; 1: 728.
- Cotterill JM. Condition of stiff great toe in adolescents. Edinburgh Med J 1887; 33: 459-62.
- DuVries HL. Surgery of the foot. St. Louis: Mosby, 1959: 381-440.
- Muscarella VJ, Hetherington VG. Hallux limitus and hallux rigidus. In: Hetherington VJ. Eds. Hallux valgus and Forefoot Surgery. New York: Churchill Livingstone, 1994: 313-25.
- Wilson DW. Hallux valgus and rigidus. In: Helal B, Wilson D. Eds. The Foot. Edinburgh: Churchill Livingstone, 1988: 471-5.
- Mau C. Das Krankheitsbild des Hallux rigidus. Münch med Woch 1928; 75: 1193-6.
- Ritschl A. Die Beugekontraktur der grossen Zehe. Münch Med Wschr 1917: 617.
- Bonney G, Macnab I. Hallux valgus and hallux rigidus. J Bone Joint Surg 1952; 34-B: 366-85.
- Hardy RH, Clapham JCR. Observations on hallux valgus. J Bone Joint Surg 1951; 33-B: 376-91.
- Bingold AC, Collins DH. Hallux rigidus. J Bone Joint Surg 1950; 32-B: 214-22.
- Nilsonne C. Über Zehenkontrakturen. Wiener klin Wochenschrift. 1881: 51: 1418-9.
- Wilson CL. A method of fusion of the metatarsophalangeal joint of the great toe. J Bone Joint Surg 1958; 40-A: 384-5.
- Holmes GB. Hallux rigidus. In: Gould JS. Ed. Operative Foot Surgery. Philadelphia: Saunders, 1994: 23-7.
- Honig. Studie über Längenverhältnisse der Metatarsalia I und II bei Hallux valgus und Hallux rigidus. Zürich: Dissertation, 1938.
- Moberg E. A simple operation for hallux rigidus. Clin Orthop 1979; 142: 55-6.
- Regnauld B. The Foot. Pathology, Aetiology, Semiology, Clinical Investigation and Therapy. Berlin: Springer, 1986.
- Menge M, Maaz B, Pelster C. Ergebnisse nach Replantation der Großzehengrundglieds-Gelenkfläche nach Regnauld bei der Operation des Hallux valgus und des Hallux rigidus. Orthop Praxis 1984; 20: 588-94.
- Cavolo DJ, Cavallaro D, Arrington L. The Waterman osteotomy for hallux limitus. J Am Podiatry Assoc 1979; 69: 52-7.
- McMurray TP. Treatment of hallux valgus and rigidus. Br Med J 1936; 2: 218-21.
- Watermann H. Die Arthritis deformans des Großzehengrundgelenkes als selbständiges Krankheitsbild. Z Orthop Chir 1927; 48: 346-55.
- Elmslie RC. The treatment of hallux valgus and hallux rigidus. Lancet 1926; 2: 665-6.
- Saxl A. Die arthritische Verkrümmung und Versteifung der großen Zehe. Z Orthop Chir 1924; 45: 521-7.
- Lambrinudi C. Metatarsus primus elevatus. Proc R Soc Med 1938; 31: 1273-80.
- Lapidus PW. "Dorsal bunion", its mechanics and operative correction. J Bone Joint Surg 1940; 22: 627-37.
- Dickson FD, Diveley RL. Functional disorders of the foot. Their diagnosis and treatment. Philadelphia: JB Lippincott, 1939: 228-232.
- Schede F. Hallux valgus, Hallux flexus und Fußsenkung. Z Orthop 1927; 48: 564-71.
- Kingreen O. Die Beugecontractur der Großzehe und ihre Behandlung. Arch klin Chir 1927; 147: 782-8.
- Salis H. Die reine Beugekontraktur der Großzehe. Z Orthop Unfallchir 1923; 44: 376-82.
- Kleinschmidt O. Die operative Behandlung der typischen Beugekontraktur der großen Zehe. Zbl Chir 1920; 11: 243-6.
- Kampner SL. Total joint prosthetic arthroplasty of the great toe-a 12 year experience. Foot Ankle 1984; 4: 249-61.
- Grace DL. Implant arthroplasty of the metatarsophalangeal joints. J Bone Joint Surg 1984; 66-B: 772.
- Swanson AB. Implant arthroplasty in disabilities of the great toe. Instr Course Lect 1972; 21: 227-35.
- Christie AJ, Weinberger KA, Dietrich M. Silicone lymphadenopathy and synovitis. JAMA 1977; 237: 1463-4.
- Gordon M, Bullough PG. Synovial and osseous inflammation in failed silicone-rubber prostheses. J Bone Joint Surg 1982; 64-A: 574-80.

36. Mann RA, Clanton TO. Hallux rigidus: treatment by cheilectomy. *J Bone Joint Surg* 1988; 70-A: 400-6.
37. Rudert M, Wülker N, Drescher S. Die Cheilektomie zur Therapie des Hallux rigidus. *Orthop Praxis* 1996; 32: 848-52.
38. Mann RA, Coughlin MJ, DuVries HL. Hallux rigidus: A review of the literature and a method of treatment. *Clin Orthop* 1979; 142: 57-63.
39. Gould N. Hallux rigidus: Cheilectomy or implant? *Foot Ankle* 1981; 1: 315-20.
40. Hattrupp SJ, Johnson KA. Subjective results of hallux rigidus following treatment by cheilectomy. *Clin Orthop* 1988; 226: 182-91.
41. Broca P. Des difformités de la partie antérieure du pied produite par faction de la chaussure. *Bull Soc Anat* 1852; 27: 60-7.
42. Clutton HH. The treatment of hallux valgus. *St Thomas Rep* 1894; 22: 1-12.
43. Johansson JE, Barrington TW. Cone arthrodesis of the first metatarsophalangeal joint. *Foot Ankle* 1984; 4: 244-8.
44. Marin GA. Arthrodesis of the metatarsophalangeal joint for hallux valgus and hallux rigidus. *Guy's Hospital Reports* 1960; 109: 174-8.
45. Marin GA. Arthrodesis of the metatarsophalangeal joint of the big toe for hallux valgus and hallux rigidus. *Int Surg* 1968; 50: 175-80.
46. McKeever DC. Arthrodesis of the first metatarsophalangeal joint for hallux valgus, hallux rigidus and metatarsus primus varus. *J Bone Joint Surg* 1952; 34: 129-34.
47. Moynihan FJ. Arthrodesis of the metatarsophalangeal joint of the great toe. *J Bone Joint Surg* 1967; 49-B: 544-51.
48. Wilkinson J. Cone arthrodesis of the first metatarsophalangeal joint. *Acta Orthop Scand* 1978; 49: 627-30.
49. Wilson JN. Cone arthrodesis for the first metatarsophalangeal joint. *J Bone Joint Surg* 1967; 49-B: 98-101.
50. Geiser M. Die Arthrodesse des Großzehengrundgelenkes. *Orthop Praxis* 1976; 12: 394-7.
51. Harrison MH, Harvey FJ. Arthrodesis of the first metatarsophalangeal joint for hallux valgus and rigidus. *J Bone Joint Surg* 1963; 45-A: 471-80.
52. Turan I, Lindgren U. Compression-screw arthrodesis of the first metatarsophalangeal joint of the foot. *Clin Orthop* 1987; 221: 292-5.
53. Coughlin MJ. Arthrodesis of the first metatarsophalangeal joint with mini-fragment plate fixation. *Orthopedics* 1990; 13: 1037-44.
54. Bielen M, Holland Ch. Behandlungsergebnisse der Großzehengrundgelenks-Arthrodesse bei Hallux valgus und Hallux rigidus. *Orthop Praxis* 1985; 21: 170-2.
55. Ross Smith N. Hallux valgus and rigidus treated by arthrodesis of the metatarso-phalangeal joint. *Br Med J* 1952; 2: 1385-7.
56. Lipscomb PR. Arthrodesis of the first metatarsophalangeal joint for severe bunions and hallux rigidus. *Clin Orthop* 1979; 142: 48-54.
57. Hulbert KF. Compression clamp for arthrodesis of the first metatarsophalangeal joint. *Lancet* 1955; 1: 597.
58. Caughlin MJ, Mann RA. Arthrodesis of the first metatarsophalangeal joint as a salvage for the failed Keller procedure. *J Bone Joint Surg* 1987; 69-A: 68-75.
59. Mann RA, Oates JC. Arthrodesis of the first metatarsophalangeal joint. *Foot Ankle* 1980; 1: 159-66.
60. Fitzgerald JAW. A review of long term results of arthrodeses of the first metatarsophalangeal joint. *J Bone Joint Surg* 1969; 51-B: 488-93.
61. Gimple K, Amspacher JC, Kopta JA. Metatarsophalangeal fusion of the great toe. *Orthopaedics* 1978; 1: 462-7.
62. Lahz JC. Metatarso-phalangeal arthrodesis for hallux valgus. *J Bone Joint Surg* 1973; 55-B: 220-1.
63. Zadik FR. Arthrodesis of the great toe. *British Med J* 1960; 2: 1573-4.
64. Phillips JE, Hooper G. A method of fusion of the first metatarsophalangeal joint. *J Bone Joint Surg* 1985; 67-B: 670.
65. Chana GS, Andrew TA, Cotterill CO. A simple method of arthrodesis of the first metatarsophalangeal joint. *J Bone Joint Surg* 1984; 66-B: 703-5.
66. Thompson FR, McElvenny RT. Arthrodesis of the first metatarsophalangeal joint. *J Bone Joint Surg* 1950; 22: 555-8.
67. Salis-Sogliò G, Gebler-Rothlaender B. Die Arthrodesse des Großzehengrundgelenkes. *Z Orthop* 1986; 124: 288-92.