

PIGMENTED VILLONODULAR SYNOVITIS OF THE KNEE PRESENTING AS A POPLITEAL CYST A CASE REPORT

*Hasan TATARI**, *Önder BARAN**, *Banu LEBE***

*Selçuk KILIÇ****, *Metin MANİSALI*****, *Hasan HAVİTÇIOĞLU******

SUMMARY

Pigmented villonodular synovitis is a locally aggressive tumor of the synovium of joints and tendon sheaths. It is commonly seen in the synovial lining of the flexor tendons of the hand and in the synovium of the knee and less commonly in other joints. In this case report, a pigmented villonodular synovitis case of the knee in a 60-year-old man, with an intraarticular origin extending extraarticularly, is represented. The interesting point was that the initial diagnosis was a Baker cyst.

Key Words: *Pigmented Villonodular Synovitis, Knee, Popliteal Cyst.*

ÖZET

DİZDE, POPLİTEAL KİSTE BENZEYEN BİR PİGMENTE VİLLONODÜLER SİNOVİT OLGUSU

Olgu Sunumu: Pigmente villonodüler sinoviyit, eklem ve tendon kılıfı sinoviyasının lokal agresif bir tümördür. Sıklıkla, el fleksör tendonları ile diz eklemi sinoviyasında ve daha nadir olarak da diğer eklemlerde görülür. Bu olgu sunumunda, 60 yaşında bir erkek hastanın diz eklemünde saptanan, eklem içi orijin göstererek eklem dışı uzanım sergileyen bir pigmente villonodüler sinoviyit olgusu sunulmaktadır. Olgunun ilginç yönü, başlangıçtaki tanının Baker kisti olmasıdır.

Anahtar Kelimeler: *Pigmente Villonodüler Sinoviyit, Diz, Popliteal Kist.*

INTRODUCTION

In 1941, Jaffe et al. introduced the term of pigmented villonodular synovitis (PVS) based upon their observations on clinical and pathological experience with 20 cases^{1,2,3}. Since then, many

cases of this condition involving different joints, mostly knee, either intraarticularly or extraarticularly have been reported¹⁻⁶. Here, we report a pigmented villonodular synovitis case of the knee in a 60-year-old man that has an intraarticular origin and extends extraarticularly, where the initial diagnosis was a Baker cyst.

CASE REPORT

A 60-year-old man presented with a four-month history of increasing pain and swelling in the posterior aspect of his left knee, without any trauma. He was unable to bear full weight on his left leg. The range of motion of his left knee was minimally decreased and there was pain exacerbated by forced flexion. Despite moderate joint effusion detected on physical examination, his roentgenographic and laboratory examinations were within normal limits. The aspirate from the suprapatellar region was yellowish and microbiologic evaluation revealed no infectious agent. Ultrasonographic examination showed a well circumscribed mass of 31x54x56 mm. in size relevant with a complicated Baker cyst. Magnetic resonance images showed a large mass posterior to the medial head of the gastrocnemius muscle that seemed to be originating from the intraarticular compartment and extending extraarticularly on axial images (Figure 1). The woper most portion was hyperintense due to the hemorrhage (Figure 2). The middle and lower portions of the well deliniated mass were heterogenous with areas of predominant signal loss. Vascular displacement due to the mass effect was evident (Figure 3). An open excisional biopsy was performed through a posterior curvilinear incision. Macroscopically, the fragmented

* Assistant Professor, Department of Orthopaedics and Traumatology, Dokuz Eylül University, School of Medicine.

** Assistant Professor, Department of Pathology, Dokuz Eylül University, School of Medicine.

*** Research Assistant, Department of Orthopaedics and Traumatology, Dokuz Eylül University, School of Medicine.

**** Associate Professor, Department of Radiology, Dokuz Eylül University, School of Medicine.

***** Professor, Department of Orthopaedics and Traumatology, Dokuz Eylül University, School of Medicine.

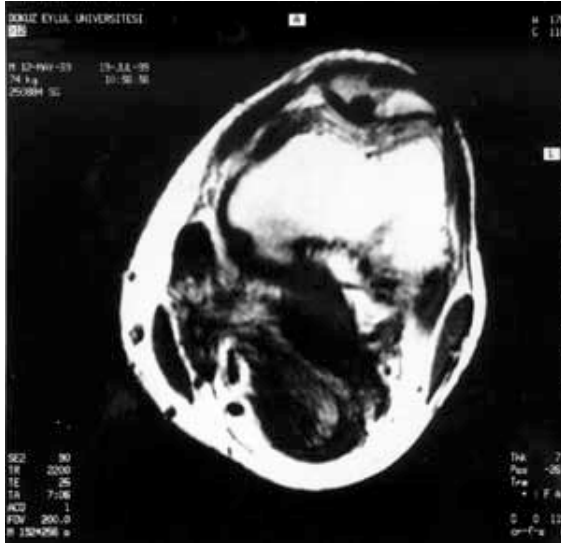

Figure 1: Proton weighted axial MR image. The neck of the mainly heterogenous hypointense mass extending to the midline is relatively narrow than its body.

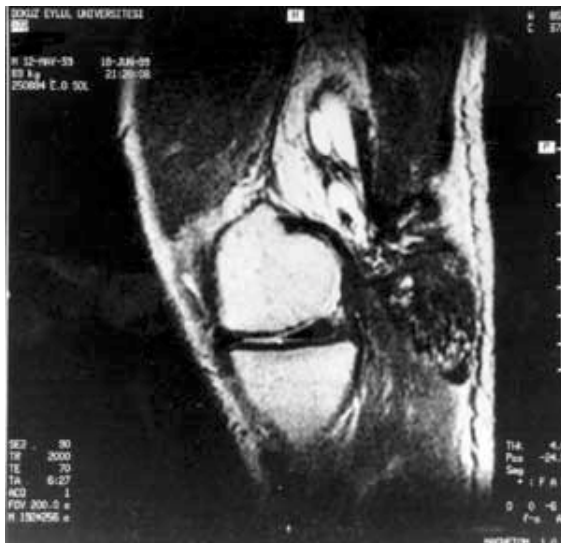

Figure 2: T 2 weighted-spin echo MR image through the level of the medial epicondyle of the left knee. Posterior to the medial head of gastrocnemius muscle, a large mass is present. The most upper portion is hyperintense due to the hemorrhage and the middle and lower portions are heterogenous with areas of signal loss corresponding to villous hypertrophy and pigment deposition.

specimen measured 6x4x0.3 cm. and the cut surface was greyish-white with a cystic and focal nodular appearance. The cyst content was sero-hemorrhagic. The cyst wall was solid and regular. Microscopically, the lesion consisted almost exclusively of numerous polyhedral epitheloid-

plump histiocytic cells (Figure 4) with occasional multinuclear giant cells and aggregates of foam cells (Figure 5). These cells were arranged in villous and nodular fashion. The villonodular structures were lined by stratified synovial cells. There was also focal hemosiderin deposits. Most of the stroma was hemorrhagic and collagenous. There was no mitosis and necrosis.

The patient underwent an arthroscopic debridement because of his increasing complaints

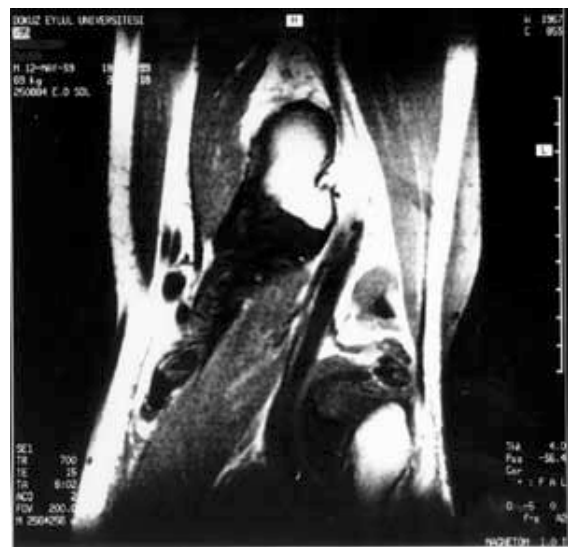

Figure 3: T 1 weighted-spin echo coronal MR image of the left knee. Vascular displacement due to the mass effect is evident. The hyperintense appearance of upper portion of the cystic mass in both T 1 and T 2 (Figure 1) sequence is due to hemorrhage. The lower portion exhibits signal loss secondary to hypertrophied pigmented villous projections.

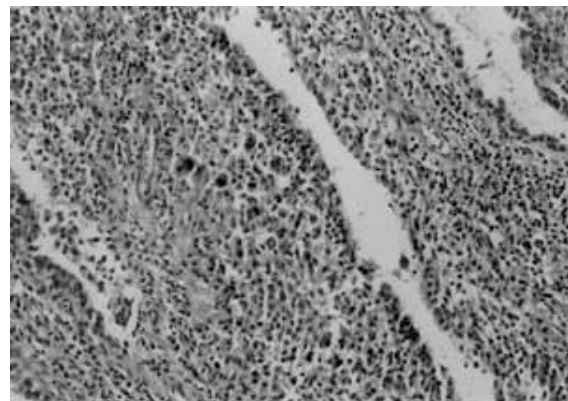


Figure 4: Numerous multinuclear giant cells and plump histiocytes at the center of the figure (x 100, H&E).

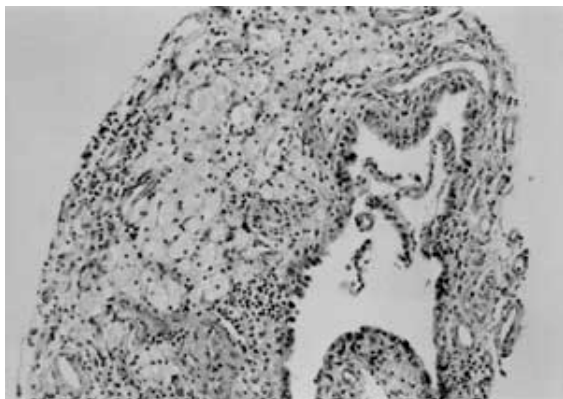


Figure 5: The aggregate of foam cells with small vascular structures (x 100, H&E).

after two months and the residual pathological synovial tissues were removed from the joint.

DISCUSSION

Pigmented villonodular synovitis is a benign proliferative disorder of the synovium of uncertain cause^{2,5,7}. The disease mostly affects the people who are in the third or fourth decade of life^{1,5,6,8,9}, but can also be seen in younger and older people^{8,10} just like in the present case. The knee is the most commonly affected joint with an incidence of 75-80%^{7,10} and involvement is almost always monoarticular^{1-6,9}. It is generally characterized by a single nodular lesion, usually pedunculated and protrudes into the joint cavity^{4,6}. Differential diagnosis of the clinical and radiologic features of PVS includes synovial proliferative disorders such as rheumatoid arthritis³, synovial chondromatosis¹¹, osteoarthritis, infections, synovial sarcoma, crystal synovitis⁷ and synovial hemangioma^{11,12}.

PVS occurs in two forms; localized and diffuse^{1,4-6}. It can be found in different parts of the knee joint, such as fat pad⁴, popliteal fossa^{6,8}, behind the medial patellar plica¹, and near the anterior horns of the menisci⁹. Just like as in our case, when observed in the posterior aspect of the knee, it can resemble a popliteal cyst originating from the bursa of the gastrocnemius and semimembranosus muscles. PVS cases presenting with cyst have been reported in adults and children before⁸. As an important point in differential diagnosis, popliteal cysts usually do not communicate with the knee joint⁸. Our case had a pedunculated origin demonstrating an evidence that does not belong to a popliteal cyst. Moskovich

et al.⁹ have mentioned that eight of nine cases had pedunculated masses that were easily identified as different from the surrounding synovium.

Roentgenographic findings are usually absent, and user dependent ultrasonography could be nondiagnostic. Due to its high contrast resolution, MRI is the best choice in non-invasive preoperative evaluation of these cases^{2,5}. The most characteristic MRI finding in PVS is nodular intraarticular masses of low signal intensity on T1-T2-, and proton density-weighted sequences, which are secondary to hemosiderin deposition^{5,11}. In the present case, the areas of signal loss, corresponding to villous hypertrophy and pigment deposition, were the evidences of PVS.

Histologically, the lesion is characterized by a fibrous stroma, deposition of hemosiderin, nodules of proliferating collagen-producing polyhedral epitheloid cells, and scattered multinucleated giant cells occurring in the synovial membrane^{1,4,7,9,13-15}. The cellular component is similar to that of nodular tenosynovitis, but in addition, there are papillary projections made up of foamy cells and hemosiderin-containing phagocytes. The degree of pigmentation ranges from a barely detectable yellow color to dark brown⁹. Large clefts and pseudoglandular or alveolar spaces lined by synovial cells are also present¹³⁻¹⁵. In the present case, the histopathologic evaluation confirmed the diagnosis.

As a conclusion, we wanted to share our experience with this case and denote that PVS localized extraarticularly or that had extraarticular extension in knee could clinically simulate a Baker cyst.

REFERENCES

1. Lee B, Yoo JE, Lee SH, Min KD. Localized pigmented villonodular synovitis of the knee: Arthroscopic treatment. *Arthroscopy* 1998; 14 (7): 764-8.
2. Mancini GB, Lazzeri S, Bruno G, Pucci G. Localized pigmented villonodular synovitis of the knee. *Arthroscopy* 1998; 14 (5): 532-6.
3. Torisu T, Watanabe H. Pigmented villonodular synovitis occurred in a rheumatoid patient. *Clin Orthop* 1973; 91: 134-40.
4. Delcogliano A, Galli M, Menghi A, Belli P. Localized pigmented villonodular synovitis of the knee: Report of two cases of fat pad involvement. *Arthroscopy* 1998; 14 (5): 527-31.
5. Lin J, Jacobson JA, Jamadar DA, Ellis JH. Pigmented villonodular synovitis and related lesions: The spectrum of imaging findings. *Am J Roentgenol* 1999; 172: 191-7.

6. Ogilvie-Harris DJ, McLean J, Zarnett ME. Pigmented villonodular synovitis of the knee. *J Bone Joint Surg* 1992; 74-A (1): 119-23.
7. Schwartz HS, Unni KK, Pritchard DJ. Pigmented villonodular synovitis. A retrospective review of affected large joints. *Clin Orthop* 1989; 247: 243-55.
8. Meehan PL, Daftari T. Pigmented villonodular synovitis presenting as a popliteal cyst in a child. *J Bone Joint Surg* 1994; 76-A (4): 593-5.
9. Moskovich R, Parisien S. Localized pigmented villonodular synovitis of the knee: Arthroscopic treatment. *Clin Orthop* 1991; 271: 218-23.
10. Visser E, Veth RPH, Pruszczynski M, Wobbles T, Van de Putte LBA. Diffuse and localized pigmented villonodular synovitis: evaluation of treatment of 38 patients. *Arch Orthop Trauma Surg* 1999; 119: 401-4.
11. Jelinek JS, Kransdorf MJ, Utz JA, Berrey BH, Thomson JD, Heekin RD, Radowich MS. Imaging of pigmented villonodular synovitis with emphasis on MR imaging. *Am J Roentgenol* 1989; 152: 337-42.
12. Lindenbaum BL, Hunt T. An unusual presentation of pigmented villonodular synovitis. *Clin Orthop* 1977; 122: 263-7.
13. Bullough PG. Joint Diseases. In: Sternberg SS. Ed. *Diagnostic Surgical Pathology*. Philadelphia: Lippincott Williams and Wilkins, 1999: 236-7.
14. Enzinger FM, Weiss SW. Benign Tumors and Tumorlike Lesions of Synovial Tissue. In: Enzinger FM, Weiss SW. Eds. *Soft Tissue Tumors*. St. Louis: Mosby, 1995: 742-8.
15. Rosai J. Bone and Joints. In: Rosai J. Ed. *Ackerman's Surgical Pathology*. St. Louis: Mosby, 1996: 2000-1.