

A MODIFIED TECHNIQUE FOR CLOSED REDUCTION OF MODULAR HIP PROSTHESIS DISLOCATION: BASSI'S METHOD

Jiwan Lal BASSI, Harpal Singh SELHI***

ABSTRACT

Dislocation is one of the common complications after hip arthroplasty. The problem is further compounded in modular hip prosthesis as there is potential risk of disengagement of the components. A different technique for closed reduction of the dislocated modular hip prosthesis is described. The manoeuvre involves flexion, adduction and internal rotation of femur in lateral position to relocate the head of the prosthesis in the cup. This manoeuvre avoids contact between the head of the femoral component and edge of the acetabulum and thus reduces the potential risk of disengagement of the components of modular hip prosthesis. This method is effective and efficient for reduction of total and partial modular hip arthroplasty and may be performed without anaesthesia.

ÖZET

MODÜLER KALÇA PROTEZİ ÇIKIKLARINDA
MODİFİYE KAPALI REDÜKSİYON TEKNİĞİ:
BASSİ YÖNTEMİ

Kalça artroplastisinden sonra dislokasyon sık görülen bir komplikasyondur. Modüler kalça protezinde komponentlerin ayrılma olasılığı durumu daha komplike hale getirmektedir. Modüler kalça protezi çıkığının kapalı redüksiyonu için farklı bir yöntem tanımlanmıştır. Manevra femuru lateral pozisyonunda fleksiyon, addüksiyon ve iç rotasyonunu gerektirmektedir. Bu manevra baş ile femoral komponentin asetabulum kenarıyla temasını azaltmakta ve komponentlerin ayrılmasını önlemektedir. Bu yöntem total ve parsiyel modüler kalça artroplastisinde etkili bir yöntem olup anestezi gerektirmeden redüksiyon sağlanabilir.

INTRODUCTION

The usual incidence of dislocation after hip arthroplasty is approximately 3%. Most of the dislocations after hip arthroplasty occur within the

first six weeks after surgery and are usually precipitated by adduction in flexion of the hip at the time when patient has not yet recovered muscle control and strength. Allis's, Stimson's and flexion adduction methods have been successfully used for closed reduction of partial and total hip arthroplasty^{1,2}. Dislocation of modular hip prosthesis, both total and partial is difficult to reduce by closed methods because of the danger of disengagement of the components^{2,3}. We report a new method of closed reduction of modular hip arthroplasty, which is simple and less likely to produce complications in modular prosthesis especially total hip arthroplasty.

MATERIAL AND METHODS

A prospective study was undertaken for reduction of dislocated modular hip prosthesis, both total and partial by flexion, adduction and internal rotation method at Dayanand Medical College & Hospital, Ludhiana, India over a period of 18 months (Jan, 1997 to June, 1998). All patients of modular hip prosthesis (unilateral or bilateral) reporting back with dislocation of the prosthesis were offered treatment by this method and those consenting to undergo the procedure were included in the study. A written informed consent was obtained from the patients. The procedure was carried out under General Anaesthesia or regional sub-arachnoid block (Spinal) anaesthesia.

METHOD

Patient is placed in lateral position with the affected side up. The surgeon stands facing the patient and flexes the dislocated hip to 90°, maximum possible adduction and then internal rotation. He then applies gentle traction in the long axis of the femur while an assistant who stands on the other side gives counter traction and stabilises the pelvis with one hand. With the other hand, he gently pushes the femoral component in the direction of the

* Professor, Department of Orthopaedic Surgery, Dayanand Medical College & Hospital, Punjab, India.

** Senior Resident Department of Orthopaedic Surgery, Dayanand Medical College & Hospital, Punjab, India.

femur to prevent dislodgement of the head/neck from the stem (Fig. 1). Maintaining the pressure on the head, the internal rotation, flexion and adduction are corrected and simultaneously during this manipulation reduction is felt and limb can be brought into neutral position. The flexion deformity is corrected and the head of the prosthesis, which was felt under the soft tissues, cannot be palpated anymore. The limb length discrepancy also disappears.

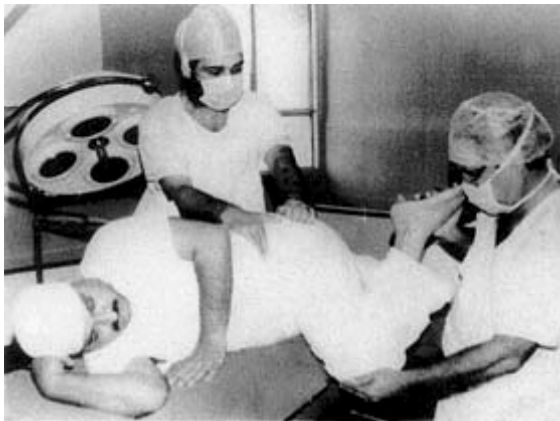


Figure 1: The photograph shows surgeon manipulating the limb in flexion, adduction and internal rotation while the assistant is stabilising the pelvis and maintaining pressure over the head of the prosthesis.

POST REDUCTION MANAGEMENT

Patient is put on skin traction for 12 weeks in abduction so as to prevent the redislocation of hip.

RESULTS

In a total number of 34 modular hip arthroplasty (Total and Partial) 6 cases of dislocation were recorded and treated with this method. We were able to achieve closed reduction in all the six cases. None of the patients had disengagement of the components during the procedure. We followed up the patients for about one year. One patient required revision of acetabular component to correct the retroversion of the acetabular component.

DISCUSSION

It has been observed that dislocation occurs in the early postoperative period when the fibrous tissue around the hip is healing. In our series of modular hip prosthesis, the dislocation rate is more in comparison with other reports which is probably due to learning curve^{2,4}. During manipulation for closed reduction, if the head of the modular prosthesis comes in contact with acetabular component, the risk of disengagement of head from the stem or acetabular liner from the cup is high and this requires open reduction. In this method, the flexion, internal rotation and maximum adduction of the hip prevents contact between the femoral components and the edge of the acetabular component. This manoeuvre along with pressure over the head of the femoral component prevents disengagement/dissociation of the head of the prosthesis from the femoral stem and acetabular liner from the cup. For repeated or habitual dislocations, revision surgery for proper realignment of the components should be performed.

REFERENCES

1. Bassi JL, Ahuja SC, Singh H. A flexion adduction method for the reduction of posterior dislocation of the hip. *J Bone Joint Surg* 1992; 74-B: 157-158.
2. Harkess JW. Arthroplasty of hip. In: Crenshaw AH, ed. *Campbell's Operative Orthopaedics*. St. Louis: CV Mosby Company, 1994: 441-626.
3. Loubignac F, Boissier F. Cup dissociation after reduction of a dislocated hip hemiarthroplasty. *Rev Chir Orthop Reparatrice Appar Mot* 1997; 84(5): 469-472.
4. Khan MA, Brabenbury PH, Reynolds ISR. Dislocation following total hip replacement. *J Bone Joint Surg* 1981; 63-B: 214-218.