



Evaluation of clinical outcomes of cemented vs uncemented knee prostheses covered with titanium plasma spray and hydroxyapatite: A minimum two years follow-up

Titanyum plazma spreyi ve hidroksiapatit ile kaplı çimentolu ve çimentosuz diz protezlerinin klinik sonuçlarının değerlendirilmesi: En az iki yıl takip

Karoly Pap¹, MD, Ph.D,^{1,3} Gabor Vasarhelyi¹, MD,¹ Tamas Gal¹, MD,^{1,3} Gyorgy Nemeth²,
Bence Abonyi, MD¹, Laszlo Rudolf Hangody¹, MD, Ph.D,¹
Gyorgy Mark Hangody¹, MD, Ph.D,¹ Laszlo Hangody¹, MD, D.Sc.^{1,3}

¹Department of Orthopedics and Traumatology, Uzsoki Hospital, Budapest, Hungary

²SanatMetal Ltd. Eger, Hungary

³Department of Traumatology, Semmelweis University, Budapest, Hungary

ABSTRACT

Objectives: In this study, we introduce the SanatSwing cementless total knee prosthesis coated with a combination of titanium plasma spray and hydroxyapatite porous coating and compared its early results to the SanatSwing cemented knee prosthesis.

Patients and methods: We compared 278 patients, who underwent total knee replacement between September 2012 and February 2017. A total of 142 patients (Group A; 78 male, 64 female, mean age 69±14) were implanted a cemented SanatSwing and 136 patients (Group B; 83 male, 53 female, mean age 59±10), a cementless SanatSwing knee prosthesis was implanted. Implant position and periprosthetic bone conditions were investigated over time on radiographs after a mean follow-up period of two years. Range of motion, pain level, distance of painless walk, and the ability to climb stairs were evaluated.

Results: Significant improvement was observed in both the cemented and uncemented groups when the preoperative scores were compared to the scores of their final visit, but we did not find any difference in measured scores between the cemented and uncemented group. Complication rates were low and almost similar in both groups without any significant difference.

Conclusion: We used the combination of titanium plasma spray and the hydroxyapatite porous coating technique in cementless prostheses. Our results showed us that the novel SanatSwing cementless total knee prosthesis could be a great alternative to cemented total knee arthroplasty.

Keywords: Cementless prosthesis; functional evaluation; hydroxyapatite; knee; titanium plasma spray.

ÖZ

Amaç: Bu çalışmada, titanyum plazma sprey ve hidroksiapatit gözenekli kaplama kombinasyonu ile kaplanmış SanatSwing çimentosuz total diz protezi tanıtıldı ve erken sonuçları SanatSwing çimentolu diz protezi ile karşılaştırıldı.

Hastalar ve yöntemler: Eylül 2012 - Şubat 2017 arasında total diz replasmanı yapılan 278 hasta karşılaştırıldı. Toplam 142 hastada (Grup A; 78 erkek, 64 kadın; ort. yaş 69±14), çimentolu SanatSwing diz protezi ve 136 hastada (Grup B; 83 erkek, 53 kadın; ort. yaş 59±10) çimentosuz SanatSwing diz protezi implante edildi. Ortalama iki yıllık takip süresinden sonra radyografilerde implant pozisyonu ve periprostetik kemik koşulları araştırıldı. Hareket açıklığı, ağrı seviyesi, ağrısız yürüyüş mesafesi ve merdiven çıkma yeteneği değerlendirildi.

Bulgular: Ameliyat öncesi skorlar, son ziyaretlerinin skorları ile karşılaştırıldığında hem çimentolu hem de çimentosuz gruplarda belirgin iyileşme gözlemlendi, ancak çimentolu ve çimentosuz gruplar arasında ölçülen puanlarda bir fark bulunmadı. Her iki grupta da komplikasyon oranları düşük ve neredeyse benzerdi ve aralarında anlamlı bir fark yoktu.

Sonuç: Titanyum plazma spreyi ile hidroksiapatit gözenekli kaplama tekniğinin kombinasyonunu çimentosuz protezlerde kullandık. Elde ettiğimiz sonuçlar bize, yeni SanatSwing çimentosuz total diz protezi serisinin çimentolu total diz artroplastisine mükemmel bir alternatif olabileceğini gösterdi.

Anahtar sözcükler: Çimentosuz protez; fonksiyonel değerlendirme; hidroksiapatit; diz; titanyum plazma spreyi.

Received: May 11, 2018 Accepted: May 21, 2018

Correspondence: Karoly Pap, MD, Department of Traumatology, Semmelweis University, Uzsoki Street 29-41, 1145-Budapest, Hungary.
Tel: +36-70-450-4903 e-mail: drpapster@gmail.com

Citation:

Pap K, Vasarhelyi G, Gal T, Nemeth G, Abonyi B, Hangody LR. Evaluation of clinical outcomes of cemented vs uncemented knee prostheses covered with titanium plasma spray and hydroxyapatite: A minimum two years follow-up. Eklem Hastalıkları Cerrahisi 2018;29(2):65-70.

The overuse of the knee joints and the genetic background can result damage in the hyaline cartilage, meniscus and in the subchondral bone. This may lead to osteoarthritis. In case of severe pain and radiological deformations arthroplasty is advised.^[1]

Total knee arthroplasty (TKA) is an effective method of treatment for advanced osteoarthritis, and leads to substantial improvement in quality of life.^[2] For the most part, cemented tibial fixation has been applied and excellent long-term results have been reported.^[3] While cemented fixation remains the gold standard for TKA, aseptic loosening continues to be a common failure mechanism, particularly in young patients.^[4] This is why cementless fixation remains of interest to clinicians to apply this method in younger and more active patients, to preserve bone stock, or due to its ease of revision, to avoid complications of cementing, but most importantly, because of the improved long-term survival of the prosthesis.^[5-7] The majority of cementless TKA systems have endured limited success predominantly due to failed metal backed patellar components with subsequent metallosis.^[8] Osteolysis secondary to tibial and patellar failures have typically required removal and revision of all three components in the knee replacement.^[9,10] This is why there has been a growing interest in different prostheses coated methods which can promote osseous ingrowth and consequently more reliable biological fixation.^[11,12] Along with methods such as sintered Co-Cr beads, porous titanium alloy, open-cell porous tantalum construct, and fiber-metal mesh, there have been numerous efforts in developing and finding the ideal coating for the cementless prosthesis surface.^[13]

In our study, we introduce the Sanatmetal cementless total knee prosthesis coated with the combination of titanium plasma spray and hydroxyapatite porous coating and compared its early results with the Sanatmetal cemented knee prosthesis.

PATIENTS AND METHODS

The study protocol was approved by the Uzsoki Hospital Ethics Committee. A written informed consent was obtained from each patient. The study was conducted in accordance with the principles of the Declaration of Helsinki.

We compared 278 patients who underwent total knee replacement between September, 2012 and February, 2017. A total of 142 (Group A; 78 male, 64 female, mean age 69 ± 14) patients were implanted a cemented SanatSwing and 136 patients (Group B; 83 male, 53 female, mean age 59 ± 10), a cementless SanatSwing knee prosthesis was implanted (Figure 1). The inclusion criteria into the uncemented group were good bone quality, relatively young age, and absence of patellofemoral arthritis. All operations were performed by the same two consultant orthopedic surgeons. A tourniquet was used, and an anterior midline incision 11-13 cm in length was made with a mid-vastus capsular approach. Tibial preparation was performed first. In the uncemented group, only the patella was denervated. All three components were fixed by cementation in the cemented group (Group A), or femoral and tibial components were implanted with a press fit technique in the uncemented group (Group B). The stability of the tibia component was initially increased with two self-cutting screws (25-50 mm length). Component stability was checked manually with the leg in full extension and flexion. Varus and valgus stresses were also tested. On the first postoperative day, patients stood up, began full weight bearing, and continuous passive motion and active exercises were initiated under the supervision of a physiotherapist.

Implant position and periprosthetic bone conditions were investigated over time on radiographs after a mean follow-up period of two years. Patients underwent X-ray examinations




Figure 1. Design of the SanatSwing uncemented prosthesis.

TABLE I

	Preoperative data					
	Cemented group (n=140)*			Uncemented group (n=134)*		
	n	%	Mean±SD	n	%	Mean±SD
Knee society score			48±12			47±16
Pain severity (%)						
None	-	-		-	-	
Mild	-	-		-	-	
Moderate	31	22.1		33	24.6	
Severe	109	77.9		101	75.3	
Walking distance						
Can not walk	1	0.7		1	0.7	
<1 km or half an hour	113	80.7		119	88.8	
>1 km or half an hour	26	18.6		14	10.5	
Stairs						
Without support	5	3.5		1	0.7	
With support	135	96.5		133	99.3	
Mean range of motion (°)			96.9±12			99.32±9

* 2-2 case were excluded because of septic revision; SD: Standard deviation.

immediately postoperatively and at six weeks, six months, 12 months, and two years postoperatively. At each follow-up visit, anteroposterior (AP) and lateral standing radiographs were obtained. All X-rays were evaluated by an independent examiner.

Range of motion was measured in the early postoperative period during the in-hospital stay (5th postoperative day), at the sixth postoperative week, at the sixth postoperative month, and at the end of the second postoperative year. The patients were asked to measure their pain level in the same periods.

The patients could choose between intense, mild, or no pain. We also registered the distance of painless walk. Patients could choose between less than 30 minutes or 1 km, more than 30 minutes or 1 km or unlimited painless walking. The ability of climbing stairs with the operated limb was also evaluated. In this case, the patients were questioned only at the third postoperative month and at the end of the first year. The Knee Society (KS) score was also registered preoperatively, at the sixth postoperative months follow up and at the end of the second postoperative year.^[14]

TABLE II

	Clinical results at six months postoperative					
	Cemented group (n=140)*			Uncemented group (n=134)*		
	n	%	Mean±SD	n	%	Mean±SD
Knee society score			64.3±14			65.1±17
Pain severity (%)						
None	107	76		96	72	
Mild	33	26		38	28	
Moderate	-	-		-	-	
Severe	-	-		-	-	
Walking distance						
Can not walk	0	0		0	0	
<1 km or half an hour	25	18		28	21	
>1 km or half an hour	115	82		106	79	
Stairs						
Without support	49	35		41	31	
With support	91	65		93	69	
Mean range of motion (°)			107±17			105±15

* 2-2 case were excluded because of septic revision; SD: Standard deviation.

TABLE III
Clinical results at the end of the second postoperative year

	Cemented group (n=140)*			Uncemented group (n=134)*		
	n	%	Mean±SD	n	%	Mean±SD
Knee society score: functional score			79±17			82±15
Pain severity (%)						
None	114	82		116	86	
Mild	26	18		19	14	
Moderate	-	-		-	-	
Severe	-	-		-	-	
Walking distance						
Can not walk	0	0		0	0	
<1 km or half an hour	17	12		19	14	
>1 km or half an hour	123	88		115	86	
Stairs						
Without support	73	52		66	49	
With support	68	48		68	51	
Mean range of motion (°)			113±21			116±23

* 2-2 case were excluded because of septic revision; SD: Standard deviation.

The results were compared with a two-tailed t-test. The level of significance used was $p < 0.05$. Statistical analysis was performed with SAS statistical software package (SAS/STAT, Software Release 9.1.3., SAS Institute Inc., NC, USA).

RESULTS

The patients in this study were 69 ± 14 years old in Group A and 59 ± 10 years old in Group B. The pre- (Group A 48 ± 12 vs. Group B 47 ± 16 , $p = 0.541$) and postoperative KS scores (Group A 64.3 ± 14 vs. Group B 65.1 ± 17 , $p = 0.341$), walking distance, ability to climb and descend stairs, range of motion (ROM) and VAS pain scores were not significantly different between the two groups (Table 1-3) before surgery, at the sixth postoperative month, and at the end of the second postoperative year visit.

Significant improvement was observed in both the cemented and uncemented groups compared to their preoperative scores of their final visit.

At the end of the second year visit, the mean KS score (Group A preoperative 48 ± 12 vs. Group A postoperative second year 79 ± 17 , $p = 0.0013$, Group B preoperative 47 ± 16 vs. Group B postoperative second year 82 ± 15 , $p = 0.0025$) ROM (Group A preoperative 96.9 ± 12 vs. Group A postoperative second year 113 ± 21 , $p = 0.031$, Group B preoperative 99.32 ± 9 vs. Group B postoperative second year 116 ± 23 , $p = 0.029$), improved significantly in both groups compared to the preoperative scores. At the final follow-up examination, patient satisfaction was similar. Mild pain remained in 26 cases (18%) in group A and in 19 cases (14%) in group B.

The mean operation time in Group A was 55 ± 11 minutes versus 69 ± 19 minutes in Group B. A significant difference was observed ($p = 0.031$).

Complication rates were low and almost similar in both groups without any significant difference (Table 4). Two knees in both groups suffered septic loosening; these were treated with two-step revision

TABLE IV
Complications

	Cemented group (n=140)		Uncemented group (n=134)		p
	n	%	n	%	
Wound disorder, hemarthrosis	20	14	17	12	0.619
Septic revision	2	1.4	2	1.5	0.887
Deep venous thrombosis	2	1.4	1	0.7	0.355
Manipulation under anesthesia	5	3.5	4	2.9	0.389
Open lysis of adhesions	2	1.4	2	1.5	0.671

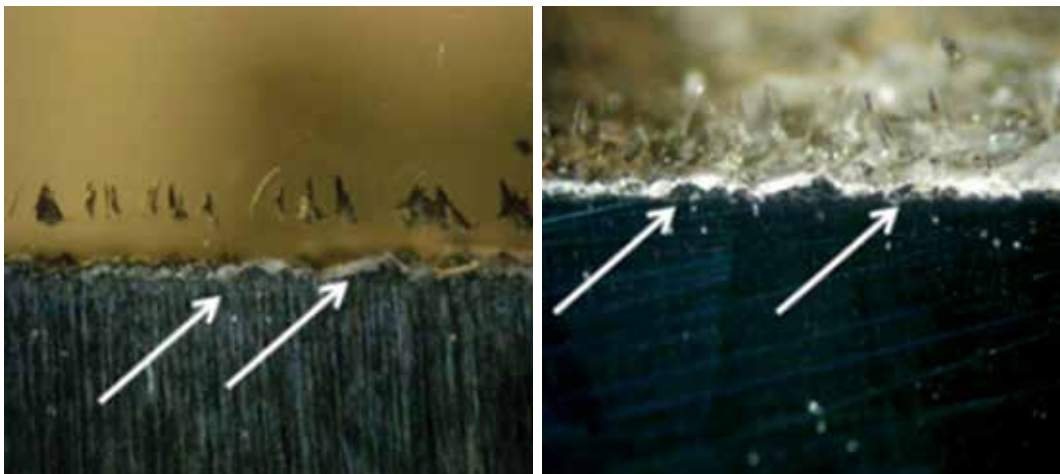


Figure 2. Cross-sections of removed uncemented tibial plateau of the prostheses. The bony incorporation is visible on the side of the bone-prosthesis border (marked with arrow).

surgeries. After the removal of a four month old cementless prosthesis, we analyzed the bony integration into the femoral and tibial prosthesis surfaces. Total bony incorporation was found on the side of the bone-prosthesis border (Figure 2). No aseptic loosening was found in either group A or group B. In two cases in group B, radiolucent lines were found by our examiners, but no migration of the tibial or the femoral components were visible.

The same results were observed in cases of minor complications. No significant differences were found in cases of wound disorders (Group A 14% vs. Group B 12%, $p=0.619$), deep vein thrombosis (Group A 1.4% vs Group B 1.5%, $p=0.655$) and open lysis of adhesions (Group A 1.4% vs. Group B 1.5%, $p=0.671$). Mean postoperative blood loss (including intraoperative blood loss and blood collected in a suction drain) was $1,286.9 \pm 428.1$ (range from 215-1,880 mL) in the uncemented group and 921.9 ± 316.1 mL (range from 285-2510 mL). This difference was significant (paired t-test $p=0.0236$).

DISCUSSION

The theoretical advantages of cementless TKA include the potential to preserve bone stock and avoid cement debris, but most importantly, the potential to achieve lasting, biological fixation of the implant to the bone with shorter operative time.

Therefore, there has been a reemergence of the development and use of cementless TKA. Recent short-term trials have demonstrated that modern cementless TKA has comparable survivability and functional outcomes to cemented prostheses.^[4] However, more prospective, randomized trials are needed to clearly

delineate any differences between these two fixation options.^[15] In our study, we found neither functional nor radiological difference between the cemented and cementless knee prosthesis. We implanted SanatSwing cementless TKA in a total of 136 patients. In these 136 patients, two septic complications were observed, the same amount as in the cemented group. No aseptic loosening was observed in either of the groups during the examination period.

The operation time was significantly shorter in the uncemented group, because of the lack of the setting time of the cement. The shorter operation time means the opened tissues can be closed earlier, which could decrease the rate of septic complications.

Once osseointegration has occurred, it is highly unlikely that loosening will present, except due to lysis or sepsis. With an increasing number of younger and more active patients seeking TKA,^[16] surgeons are looking for a more physiological bond.

Tibial baseplate loosening is one of the most common disadvantages of cementless TKA implantations.^[4] In two cases in group B, radiolucent lines were visible under the tibial component, but this did not disturb the patients in their daily activity. The patients had full pain-free active and passive ROM.

We used the combination of titanium plasma spray and the hydroxyapatite porous coating technique in cementless prostheses for the first time in literature. We found normal osseointegration with the formation of a biological interface between the bone and the prosthetic components. This was also observed after histological examinations of the removed septic knee prostheses. The operation

time was significantly shorter in the uncemented group. This was most likely due to the sparing of the cementing time.

In conclusion; the novel SanatSwing cementless total knee prosthesis could be a great alternative for cemented total knee arthroplasty. The results thus far are promising, however we would like to increase the number of cases and report long-term follow-up results.

Declaration of conflicting interests

The authors declared no conflicts of interest with respect to the authorship and/or publication of this article.

Funding

The design and development of the prosthesis was supported by SanatMetal Ltd.

REFERENCES

- Atik OS, Erdoğan D, Seymen CM, Bozkurt HH, Kaplanoglu GT. Is there crosstalk between subchondral bone, cartilage, and meniscus in the pathogenesis of osteoarthritis? *Eklem Hastalik Cerrahisi* 2016;27:62-7.
- Ethgen O, Bruyère O, Richy F, Dardennes C, Reginster JY. Health-related quality of life in total hip and total knee arthroplasty. A qualitative and systematic review of the literature. *J Bone Joint Surg Am* 2004;86:963-74.
- Kane RL, Saleh KJ, Wilt TJ, Bershadsky B. The functional outcomes of total knee arthroplasty. *J Bone Joint Surg Am* 2005;87:1719-24.
- Kim YH, Park JW, Lim HM, Park ES. Cementless and cemented total knee arthroplasty in patients younger than fifty five years. Which is better? *Int Orthop* 2014;38:297-303.
- Kim YH, Kim JS, Choe JW, Kim HJ. Long-term comparison of fixed-bearing and mobile-bearing total knee replacements in patients younger than fifty-one years of age with osteoarthritis. *J Bone Joint Surg Am* 2012;94:866-73.
- Lombardi AV Jr, Berasi CC, Berend KR. Evolution of tibial fixation in total knee arthroplasty. *J Arthroplasty* 2007;22:25-9.
- Kim YH, Kim JS, Park JW, Joo JH. Comparison of the low contact stress and press fit condylar rotating-platform mobile-bearing prostheses in total knee arthroplasty: a prospective randomized study. *J Bone Joint Surg Am* 2011;93:1001-7.
- Porter M, Borroff M, Gregg P, MacGregor A, Tucker K. National Joint Registry for England, Wales, Northern Ireland and the Isle of Man. 9th Annual Report (April 2012 - March 2013). Available from: www.new.njrcentre.org.uk/njrcentre/Reports,PublicationsandMinutes/Annualreports/Archivedannualreports/tabid/87/Default.aspx 2016.
- Nolan JF, Bucknill TM. Aggressive granulomatosis from polyethylene failure in an uncemented knee replacement. *J Bone Joint Surg Br* 1992;74:23-4.
- Berry DJ, Wold LE, Rand JA. Extensive osteolysis around an aseptic, stable, uncemented total knee replacement. *Clin Orthop Relat Res* 1993;293:204-7.
- Park JW, Kim YH. Simultaneous cemented and cementless total knee replacement in the same patients: a prospective comparison of long-term outcomes using an identical design of NexGen prosthesis. *J Bone Joint Surg [Br]* 2011;93:1479-86.
- Baker PN, Khaw FM, Kirk LM, Esler CN, Gregg PJ. A randomised controlled trial of cemented versus cementless press-fit condylar total knee replacement: 15-year survival analysis. *J Bone Joint Surg Br* 2007;89:1608-14.
- Davis JR. Coatings. In: Davies JR, editor. *Handbook of Materials for Medical Devices*. Ohio: ASM International; 2003. p. 179-94.
- Insall JN, Dorr LD, Scott RD, Scott WN. Rationale of the Knee Society clinical rating system. *Clin Orthop Relat Res* 1989;248:13-4.
- Khaw FM, Kirk LM, Morris RW, Gregg PJ. A randomised, controlled trial of cemented versus cementless press-fit condylar total knee replacement. Ten-year survival analysis. *J Bone Joint Surg Br* 2002;84:658-66.
- Kurtz SM, Lau E, Ong K, Zhao K, Kelly M, Bozic KJ. Future young patient demand for primary and revision joint replacement: national projections from 2010 to 2030. *Clin Orthop Relat Res* 2009;467:2606-12.