



A modified technique of interspinous ligamentoplasty for lumbar stenosis or degenerative spondylolisthesis

Lomber stenoz veya dejeneratif spondilolistesis tedavisi için interspinöz ligamentoplastide modifiye yeni bir teknik

Ho-Yeon Lee, M.D., PhD.¹ Sang Bum Chang, M.D.,² Sang-Ho Lee, M.D., PhD.¹ Song-Woo Shin, PhD.¹

Departments of ¹Neurosurgery, ²Orthopedic Surgery, Wooridul Spine Hospital, Seoul, Korea

Objectives: Interspinous ligamentoplasty (ILP) was first introduced by Senegas for the treatment of degenerative lumbar disease. The purpose of this study was to present a modified technique of ILP for lumbar stenosis or degenerative spondylolisthesis.

Patients and methods: Twenty patients (4 men, 16 women; mean age 61.3 years; range 31 to 83 years) underwent ILP after posterior decompression. Ten patients had stenosis with instability, eight patients had degenerative spondylolisthesis, and two patients had a juxtafacet cyst. The authors modified the original Senegas ILP procedure, so called the figure of '8' technique, as the '80 to 88' technique. In this modification, a second circular artificial ligament is added turning around the upper and lower spinous processes, initially resembling the figure '0'. It is then fastened in the middle so that its appearance turns to the figure '8'. Hence, the ligamentoplasty procedure is composed of two artificial ligaments both resembling the figure '8'.

Results: At the end of a mean follow-up period of 17.4 months (range 1 to 45 months), the mean Oswestry Disability Index score improved from 66% (range 26% to 88%) preoperatively to 31.1% (range 4% to 56%). Two patients developed superficial wound infection and another two developed transient dysesthesia. None of the patients required reoperation.

Conclusion: Considering relatively short operation time, less invasiveness, and its nonfusion nature, ILP with '80 to 88' technique seems to be an appropriate option for dynamic stabilization in treating degenerative pathologies. Yet, it should be justified with long-term comparative studies.

Key words: Intervertebral disk displacement/surgery; lumbar vertebrae/surgery/radiography; spinal fusion/instrumentation/methods; spinal stenosis/surgery; spondylolisthesis/surgery.

Amaç: İnterspinöz ligamentoplasti (İLP) dejeneratif lomber hastalığın tedavisi için ilk kez Senegas tarafından geliştirilmiştir. Bu çalışmada, lomber stenoz veya dejeneratif spondilolistesis tedavisinde kullandığımız modifiye İLP tekniğinin sunulması amaçlandı.

Hastalar ve yöntemler: Yirmi hastaya (4 erkek, 16 kadın; ort. yaş 61.3; dağılım 31-83) posterior dekompresyondan sonra İLP uygulandı. On hastada instabilitenin eşlik ettiği stenoz, sekiz hastada dejeneratif spondilolistesis, iki hastada da jukstafaset kisti vardı. Senegas'ın '8' rakamı olarak bilinen İLP prosedürü, yazarlar tarafından "80'den 88'e" tekniği şeklinde modifiye edildi. Bu modifikasyonda, üst ve alt spinöz prosesler ikinci bir yapay ligamanla '0' rakamına benzer şekilde çevrilir. Bu yapay ligaman daha sonra ortasından bağlanarak, '8' rakamına dönüştürülür. Sonuçta ligamentoplasti prosedüründe her ikisi de '8' rakamına benzeyen iki yapay ligaman kullanılmış olur.

Bulgular: Ameliyattan önce ortalama %66 (dağılım (%26-88) olan Oswestry Sakatlık İndeksi skoru, ortalama 17.4 ay (dağılım 1-45 ay) olan izlem döneminin sonunda %31.1'e (dağılım %4-56) geriledi. Komplikasyon olarak iki hastada yüzeysel yara enfeksiyonu, iki hastada geçici disestezi görüldü. Hiçbir hastada yeniden ameliyat gerekmedi.

Sonuç: Oldukça kısa ameliyat süresi, daha az invaziv olması ve nonfüzyon özelliği göz önüne alındığında, "80'den 88'e" İLP tekniği, dejeneratif patolojilerin tedavisinde dinamik stabilizasyon için uygun bir seçenek olarak görünmektedir. Bununla birlikte, uzun dönemli karşılaştırmalı çalışmalarla sınanması gerekir.

Anahtar sözcükler: İntervertebral disk deplasmanı/cerrahi; lomber vertebra/cerrahi/radyografi; spinal füzyon/entrümantasyon/yöntem; spinal stenoz/cerrahi; spondilolistesis/cerrahi.

• Correspondence: Sang-Ho Lee, MD, PhD. Department of Neurosurgery, Wooridul Spine Hospital, 47-4 Chungdam-Dong Gangnam-Gu, Seoul 135-100, Korea. Tel: +00 - 82 - 2 - 513 8151 Fax: +00 - 82 - 2 - 513 8146 e-mail: swshin@wooridul.co.kr
• This work was supported by a grant from the Wooridul Spine Foundation.

It has always been a big challenge to choose the optimal surgical treatment in symptomatic degenerative pathology of the lumbar spine. Degenerative spondylosis may cause neural compressive lesions as well as various spinal instabilities, which may further lead to neurological symptoms, pseudoradicular pain, and axial low-back pain. The focus of the treatment used to be adequate decompression with or without fusion till the introduction of dynamic stabilization. Decompressive procedures usually showed initial improvement, but success rates dropped to 70% on long-term follow-ups.^[1,2] The causes of recurrent symptoms were restenosis, new stenosis at other levels, and occurrence of herniated lumbar disc, which were considered a consequence of microinstability. Even in case of successful decompression, back pain very often remained.^[3] In addition, decompressive procedures were associated with iatrogenic instability.^[4-8] Currently, fusion surgery is performed to maintain or restore stability. But fusion, being an unphysiological procedure, may generate juxtafusal syndrome through elimination of motion at the functional spinal segment, and thus lead to a higher rate of re-interventions.^[9-12] Considering these problems, nonfusion systems have been developed as an alternative option for stabilization.

Senegas is credited with the introduction of interspinous ligamentoplasty (ILP).^[13] The authors of the current study present a modified technique of the original ILP, providing a better stabilization.

PATIENTS AND METHODS

Twenty patients (4 men, 16 women; mean age 61.3 years; range 31 to 83 years) underwent ILP after posterior decompression. Of these, 10 patients had

stenosis with instability, eight patients had degenerative spondylolisthesis, and two patients had a juxtafacet cyst.

Surgical technique

The patient is placed in the prone position, with hip joints in flexion initially. A midline incision through the skin and subcutaneous tissue is made at the affected level. Muscle stripping and retraction is limited from the lower half of the upper lamina to the upper half of the lower lamina and the facet plane laterally. Supraspinous and interspinous ligaments are removed without violation to the two spinous processes. The base of the lower spinous process is drilled out and extended laterally to unroof the lower lamina and hypertrophied inferior facet covering the traversing root till the upper half of pedicles are exposed bilaterally. At this stage, a contralateral approach with tilting of operation table and microscope is very helpful (Fig. 1a). Then, the lower half of the upper lamina and buckled yellow ligament are removed (Fig. 1b, c). At the end of decompression, there should be no contact between the dural sac and bone (usually the lower lamina) when both spinous processes are approximated with clamps. During the decompression, a polyester braid (artificial ligament), 40 cm long and 5 mm in diameter, is soaked in saline containing antibiotics. Initially, both spinous processes are wrapped with the artificial ligament, resembling the figure “8” at the base of the spinous process.

After changing the position of the spine from flexion to extension, the waist of the figure ‘8’ is sutured at least two times at a point just inferior to the upper spinous process and just superior to the lower spinous process while pulling the artificial

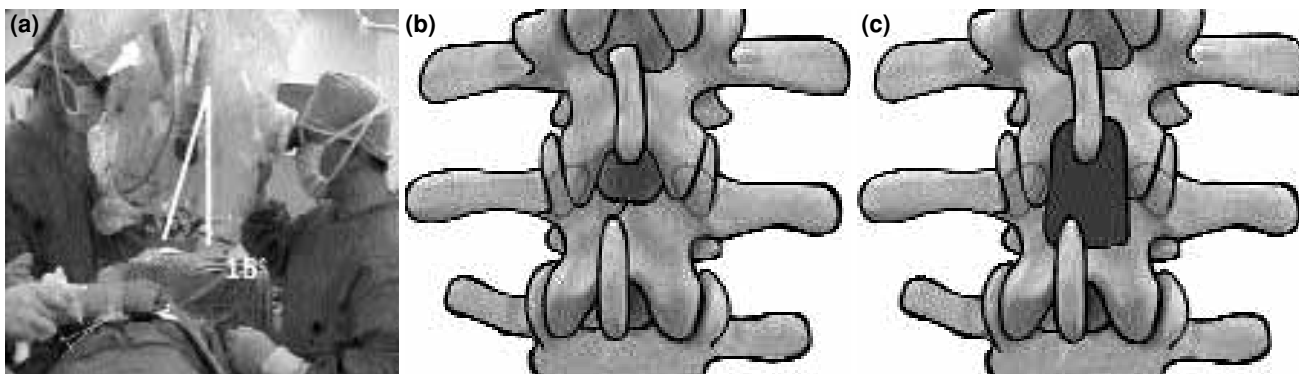


Fig. 1. (a) The operation table tilted 15 degrees; (b) illustrative image before bone removal, (c) the lower half of the upper lamina and the upper half of the lower lamina are removed for decompression.

ligament tightly. This multiply sutured waist acts as an interspinous spacer without bone erosion, which may be seen in case of a metal spacer.

Then, with the remaining ligament, another circle without crossing the interspinous space (figure of '0') is made just posterior to the initial figure of '8' and sutured to the adjacent bilateral ligament (Fig. 2a). Addition of figure '0' circle to '8' represents the difference from Senegas's original method. When the waist of the circular ligament is fastened, its appearance turns to the figure '8'. Hence, the two spinous processes are fixed tightly, but sufficient mobility is maintained between compression at the posterior circle and distraction permitted at the waist of the initial '8'. Thus, the ligament structure is changed from '80' to '88' (Fig. 2b).

RESULTS

At the end of a mean follow-up period of 17.4 months (range 1 to 45 months), the mean Oswestry Disability Index score improved from 66.0% (range 26% to 88%) preoperatively to 31.1% (range 4% to 56%). Two patients developed superficial wound infection and another two developed transient dysesthesia. None of the patients required reoperation.

DISCUSSION

As the name implies, ILP requires intact spinous processes capable of enduring the stresses and strains of loading and mobilization. In the past, total laminectomy was performed to treat lesions upon detection of total block on myelogram, and subtotal laminectomy was performed for partial

block. With the advances in optics and mechanical tools, such as high-speed drills, limited fine-targeted decompression sparing the remaining mid-line structures and spinous process is becoming a standard procedure. As a corollary, indication of ILP is more relevant than ever before.

Many randomized studies that compared different surgical procedures for spinal stenosis provided convincing evidence in favor of this procedure.^[14-17] In case of stenosis with instability and spondylolisthesis, fusion is beneficial, and this has been validated by a meta-analysis conducted by Mardjetko et al.^[18] However, the complication rate is higher than that of decompression alone in any kind of fusion.^[3,18-21] Among the drawbacks of fusion, the complication of transition syndrome and increased invasiveness of the technique cannot be expected to be overcome. To utilize the advantages of fusion without experiencing its inherent complications, mobile systems have been developed

Many types of mobile stabilization systems are available these days. According to the application site, they are divided into intradiscal, transpedicular, and interspinous systems. Intradiscal systems which are divided into total disc replacement (TDR) and partial disc replacement (PDR) are used in case of normal facet joint morphology. In degenerative conditions, stand-alone use of TDR or PDR may be limited. Transpedicular systems allow total laminectomy for decompression, but require a wide dissection and retraction of muscles. During pedicle screw procedures, surgeons are worried about pro-

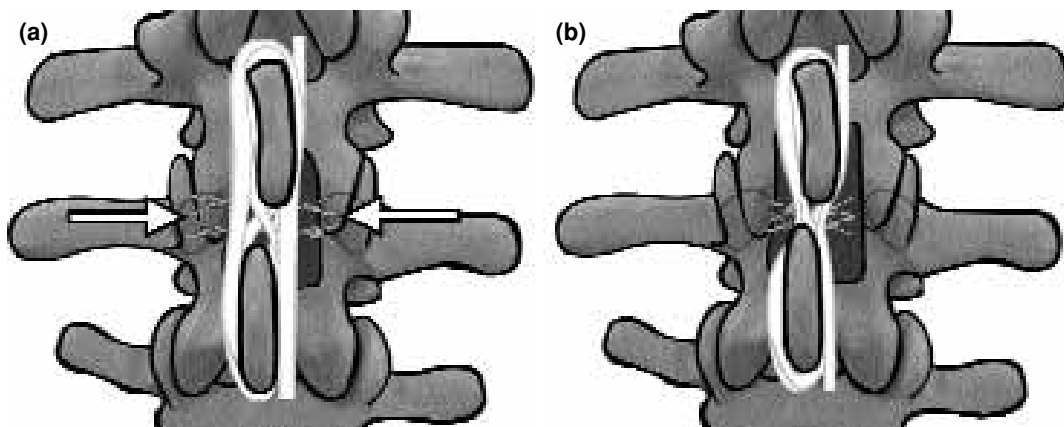


Fig. 2. (a) Illustration of both artificial ligaments encircling both spinous processes, one crosses between the spinous processes forming a figure '8', the other is circular resembling the figure '0'. (b) The waist of figure '0' is fastened tightly so that its appearance turns to the figure '8', resulting in a ligament structure of '88'.

cedure-related complications especially in degenerative conditions, such as malposition of screws, neural injury, and pedicle fractures. Considering the complications of abdominal surgery with TDR or transpedicular screw insertion, ILP may be a better choice than the other systems.

Interspinous ligamentoplasty requires less dissection and retraction of muscles just like decompression alone, keeping the pedicle and intervertebral disc intact for future salvage fusion procedures. However, it also requires the existence of a reliable spinous process, in other words, adequate decompression while retaining essential bony structure for later stabilization. Unlike former circumstances, currently available high-resolution magnetic resonance imaging and computed tomography studies enable us to plan accurate decompression preoperatively. A precise execution of this plan is possible thanks to availability of sophisticated optics and mechanical instruments, such as highly mobile surgical microscopes, endo-

scopes, and high-speed drills. Through an incision of the same size, decompression and stabilization can be simultaneously accomplished.

It should be noted that the tension of the artificial ligament during fixation is of special importance, in that excessive tension will result in spinous process fracture while insufficient tension may not provide adequate stabilization. Patients with a degenerative spinal pathology are usually old-aged, even medically compromised, and osteoporotic. It is hazardous to subject them to repeated surgeries as in decompression alone followed by fusion, or to perform fusion surgery in osteoporotic individuals.

Interspinous ligamentoplasty may also be indicated in cases of lumbar stenosis with synovial cyst, because synovial cysts are associated with disruption of the facet joint and some degree of instability (Fig. 3).^[22] It can also be used with prosthetic disc nucleus (PDN) replacement and/or interspinous locker for posterior augmentation (Fig. 4).

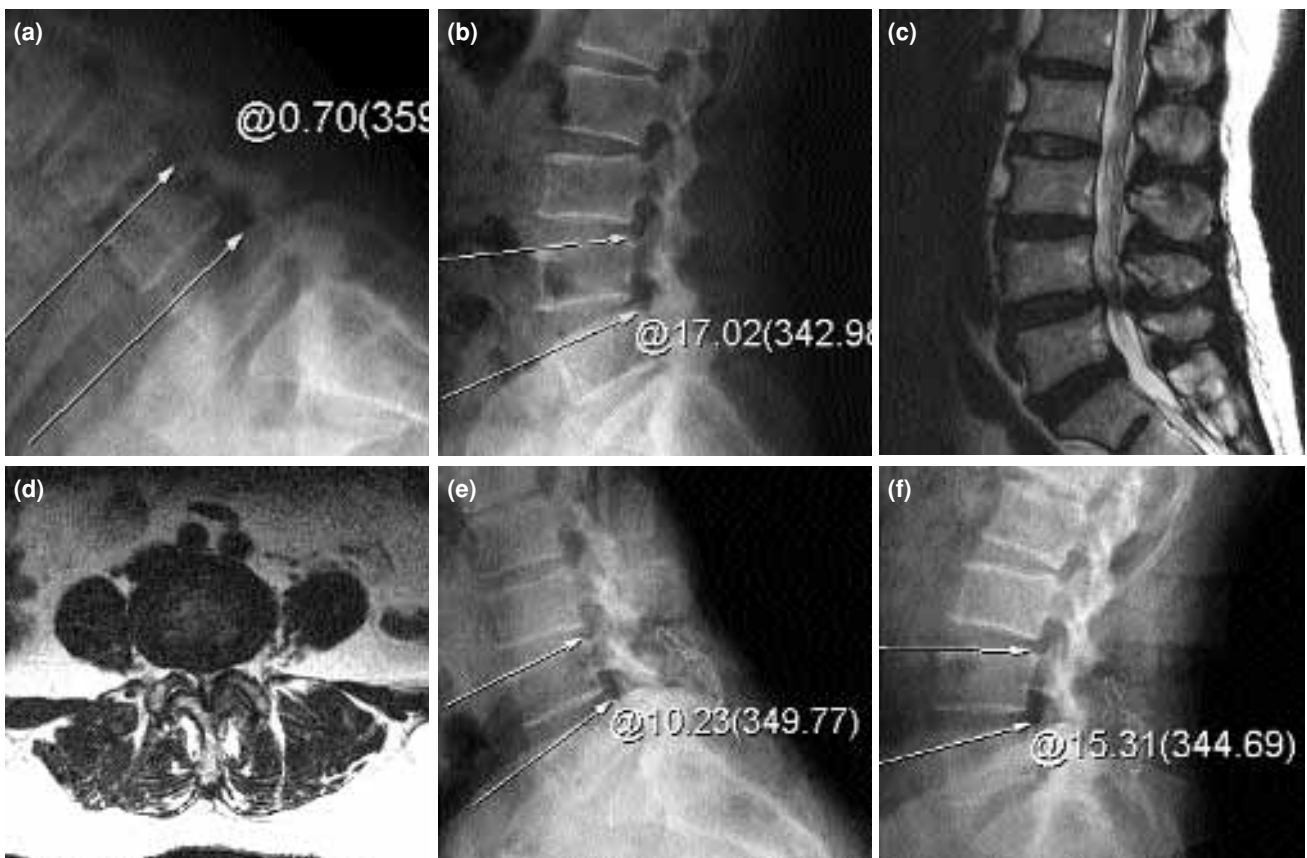


Fig. 3. (a, b) Preoperative images showing instability and a synovial cyst. The sagittal rotation angle (SRA) is measured as 17 degrees. (c, d) Appearance of the synovial cyst at L₄₋₅ on an MR image. (e, f) Postoperative images showing improvement in instability, with SRA being 5°.

In ILP, the most serious complication is fracture of the spinous process (usually the upper one). To avoid this complication, the surgeon must reserve enough bone to support the spinous process while obtaining sufficient decompression. This can be accomplished with the use of a previously described modified unilateral approach after

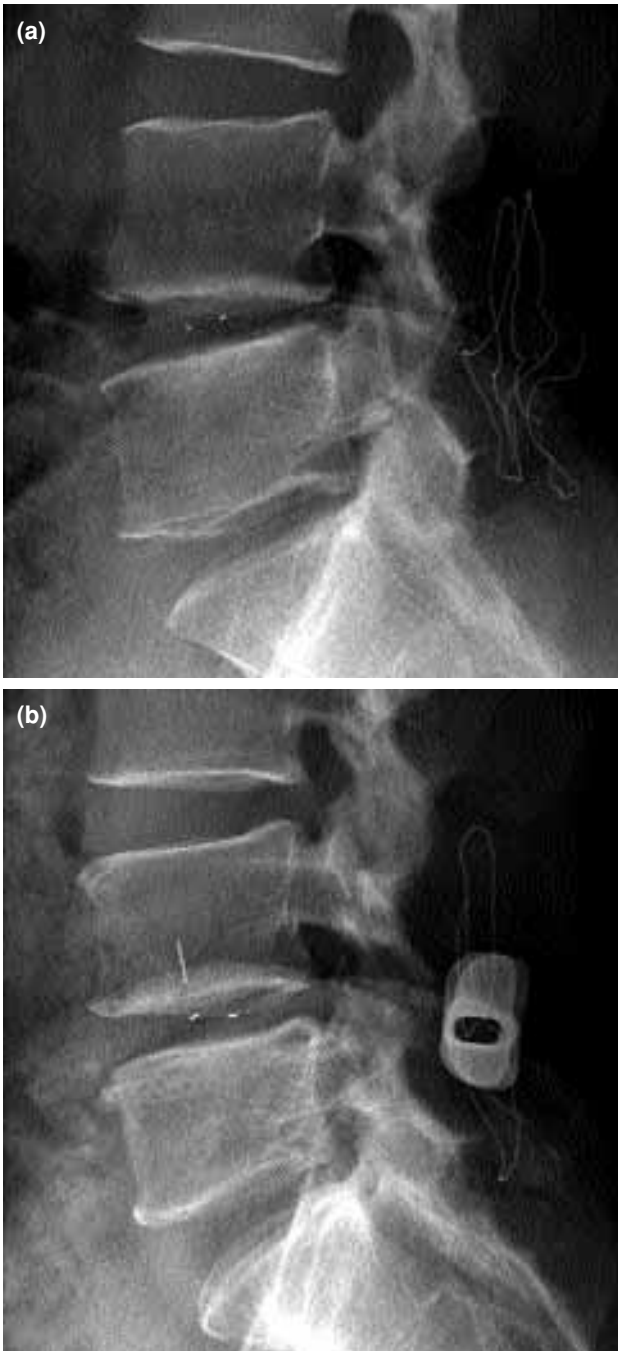


Fig. 4. (a) Combined surgery with ligamentoplasty (LP) and prosthetic disc nucleus (PDN) replacement, (b) Combined surgery with LP, PDN, and interspinous locker.

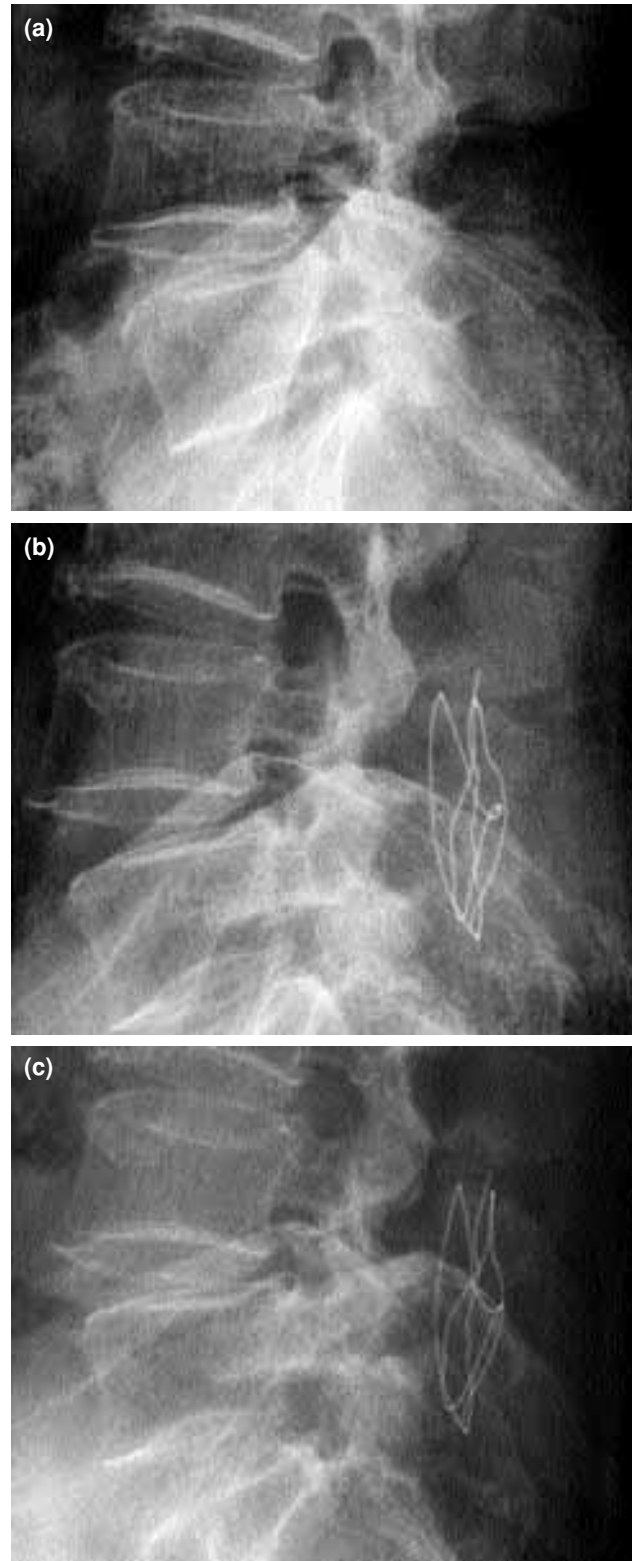


Fig. 5. (a) A preoperative radiograph. (b) Immediate postoperative radiograph showing reduction and good coiling around the spinous process. (c) Fifteen months after surgery, a progressive slippage and some erosion to the upper spinous process were seen; however, the patient's complaint of low back pain improved regardless of this phenomenon.

removal of the supraspinous and interspinous ligaments.^[23] Nonetheless, fractures may occur during passage of the thick braid portion through the interspinous ligament or upon tightening. Thus, the direction of pulling must be just tangential to the sagittal plane to minimize frictional forces exerted to the spinous processes. Then, the braid should be fastened gradually without hastening, using elastic property of the artificial ligament itself. However, even after a sufficiently good stabilization with strict adherence to the above-mentioned tips, loss of stabilization may sometimes occur owing to erosions to the spinous process (Fig. 5).

Passing the ligament too deeply may result in injury to the dural sac and subsequent cerebrospinal fluid leakage. Therefore, the ligament should be passed just posterior to the laminae. In addition, inadequate decompression and fastening of the ligament may cause new compression of the dural sac due to the remaining midline bony structures. Thus, one should consider temporary clamping to check for neural compression before application of the ligament.

Before changing the ligament combination from figure '80' to '88', fluid collection was found in some cases. However, after increasing the degree of tightness of the combination '88', fluid collection was not seen in any case. The additional step also gives a tighter stabilization in both compression and distraction; this implies that ILP can be used in the treatment of unstable spondylolisthesis of grade I. Surgeons must be aware of other complications that usually occur during the posterior approach such as hematoma, infection, nerve injury etc.

Considering relatively short operation time, less invasiveness, and its nonfusion nature, ILP with '80 to 88' technique seems to be the first option to adopt for dynamic stabilization in treating degenerative pathologies. Yet, ILP should be justified with long-term comparative studies with decompression alone and with fusion. In future, ILP may also prove to be a useful augmentation method with PDN or other disc replacement materials like pedicle screw fixation developed for intervertebral cages.

REFERENCES

1. Javid MJ, Hadar EJ. Long-term follow-up review of patients who underwent laminectomy for lumbar stenosis: a prospective study. *J Neurosurg* 1998;89:1-7.

2. Turner JA, Ersek M, Herron L, Deyo R. Surgery for lumbar spinal stenosis. Attempted meta-analysis of the literature. *Spine* 1992;17:1-8.
3. Ganz JC. Lumbar spinal stenosis: postoperative results in terms of preoperative posture-related pain. *J Neurosurg* 1990;72:71-4.
4. Abumi K, Panjabi MM, Kramer KM, Duranceau J, Oxland T, Crisco JJ. Biomechanical evaluation of lumbar spinal stability after graded facetectomies. *Spine* 1990;15:1142-7.
5. Boden SD, Martin C, Rudolph R, Kirkpatrick JS, Moeini SM, Hutton WC. Increase of motion between lumbar vertebrae after excision of the capsule and cartilage of the facets. A cadaver study. *J Bone Joint Surg [Am]* 1994;76:1847-53.
6. Frymoyer JW, Selby DK. Segmental instability. Rationale for treatment. *Spine* 1985;10:280-6.
7. Johnsson KE, Willner S, Johnsson K. Postoperative instability after decompression for lumbar spinal stenosis. *Spine* 1986;11:107-10.
8. Jonsson B, Aleson M, Jonsson K, Stromqvist B. Low risk for vertebral slipping after decompression with facet joint preserving technique for lumbar spinal stenosis. *Eur Spine J* 1992;1:100-4.
9. Aota Y, Kumano K, Hirabayashi S. Postfusion instability at the adjacent segments after rigid pedicle screw fixation for degenerative lumbar spinal disorders. *J Spinal Disord* 1995;8:464-73.
10. Kumar MN, Jacquot F, Hall H. Long-term follow-up of functional outcomes and radiographic changes at adjacent levels following lumbar spine fusion for degenerative disc disease. *Eur Spine J* 2001;10:309-13.
11. Lehmann TR, Spratt KF, Tozzi JE, Weinstein JN, Reinartz SJ, el-Khoury GY, et al. Long-term follow-up of lower lumbar fusion patients. *Spine* 1987;12:97-104.
12. Rahm MD, Hall BB. Adjacent-segment degeneration after lumbar fusion with instrumentation: a retrospective study. *J Spinal Disord* 1996;9:392-400.
13. Senegas J, Etchevers JP, Vital JM, Baulny D, Grenier F. Widening of the lumbar vertebral canal as an alternative to laminectomy in the treatment of lumbar stenosis. [Article in French] *Fr J Orthop Surg* 1998;2:93-9.
14. Mayer HM, List J, Korge A, Wiechert K. Microsurgery of acquired degenerative lumbar spinal stenosis. Bilateral over-the-top decompression through unilateral approach. [Article in German] *Orthopade* 2003;32:889-95.
15. Epstein NE. Lumbar laminectomy for the resection of synovial cysts and coexisting lumbar spinal stenosis or degenerative spondylolisthesis: an outcome study. *Spine* 2004;29:1049-55; discussion 1056.
16. Bridwell KH, Sedgewick TA, O'Brien MF, Lenke LG, Baldus C. The role of fusion and instrumentation in the treatment of degenerative spondylolisthesis with spinal stenosis. *J Spinal Disord* 1993;6:461-72.
17. Fischgrund JS, Mackay M, Herkowitz HN, Brower R, Montgomery DM, Kurz LT. Degenerative lumbar spondylolisthesis with spinal stenosis: a prospective,

- randomized study comparing decompressive laminectomy and arthrodesis with and without spinal instrumentation. *Spine* 1997;22:2807-12.
18. Mardjetko SM, Connolly PJ, Shott S. Degenerative lumbar spondylolisthesis. A meta-analysis of literature 1970-1993. *Spine* 1994;19(20 Suppl):S2256-65.
 19. Herkowitz HN, Kurz LT. Degenerative lumbar spondylolisthesis with spinal stenosis. A prospective study comparing decompression with decompression and intertransverse process arthrodesis. *J Bone Joint Surg [Am]* 1991;73:802-8.
 20. Esses SI, Sachs BL, Dreyzin V. Complications associated with the technique of pedicle screw fixation. A selected survey of ABS members. *Spine* 1993;18:2231-9.
 21. Okuyama K, Abe E, Suzuki T, Tamura Y, Chiba M, Sato K. Posterior lumbar interbody fusion: a retrospective study of complications after facet joint excision and pedicle screw fixation in 148 cases. *Acta Orthop Scand* 1999;70:329-34.
 22. Pihlajamaki H, Myllynen P, Bostman O. Complications of transpedicular lumbosacral fixation for non-traumatic disorders. *J Bone Joint Surg [Br]* 1997;79:183-9.
 23. Soini J, Laine T, Pohjolainen T, Hurri H, Alaranta H. Spondylodesis augmented by transpedicular fixation in the treatment of olisthetic and degenerative conditions of the lumbar spine. *Clin Orthop* 1993;(297):111-6.