



## Osteochondral mass encircling the patellar tendon

### Patellar tendonu saran osteochondral kitle

Metin Manouchehr Eskandari, M.D.,<sup>1</sup> Volkan Öztuna, M.D.,<sup>1</sup>  
Özlem Aydın, M.D.,<sup>2</sup> Fehmi Kuyurtar, M.D.<sup>1</sup>

Departments of <sup>1</sup>Orthopedics and Traumatology and <sup>2</sup>Pathology, Medicine Faculty of Mersin University

Osteochondral masses encircling the patellar tendon are very rare. A 70-year-old man presented with a complaint of a slow-growing painful mass of 11-year history in the anterior region of the left knee. Computed tomography showed a lesion encircling the patellar tendon. The mass was excised totally. A diagnosis of extraarticular type of synovial osteochondromatosis was made upon synchronous evaluation of clinical, radiological, and histopathological findings. The patient had no complaint other than minimal pain at his last follow-up 40 months after surgery.

**Key words:** Chondromatosis, synovial/diagnosis/surgery; diagnosis, differential; patella; tomography, X-ray computed.

Patellar tendonu saran osteokondral kitleler çok nadirdir. Yetmiş yaşındaki erkek hasta, 11 yıldan beri sol diz anteriorunda var olan ağrılı şişlik şikayetiyle başvurdu. Bilgisayarlı tomografide patellar tendonu saran bir kitle görüldü. Ameliyatta total eksizyon yapıldı. Kesin tanı ekstraartiküler tipte sinovyal osteokondromatozis idi ve bu tanıya klinik, patolojik ve histopatolojik bulguların birlikte değerlendirilmesi sonucu varıldı. Hastanın 40. aydaki kontrolünde hafif ağrı dışında bir şikayeti yoktu.

**Anahtar sözcükler:** Kondromatozis, sinovyal/tanı/cerrahi; ayırıcı tanı; patella; bilgisayarlı tomografi.

A large number of benign and malignant tumors lead to ossified or calcified periarticular masses. The differential diagnosis of these lesions might be difficult.<sup>[1-4]</sup> In such cases, the final diagnosis can be made by a synchronous evaluation of the clinical, radiological, and histopathological findings.<sup>[1]</sup> Herein, a case with an osteochondral lesion encircling the patellar tendon is presented. The final diagnosis was extraarticular type of synovial osteochondromatosis.

### CASE REPORT

A 70-year old man was admitted with a complaint of a painful mass in the left knee. His medical history showed a diagnosis of patellar tendinitis which had been treated with steroid injections 11 years ago. Following a temporary relief for several months, the patient noticed a slow-growing mass

at the anterior aspect of the knee associated with a vague pain. A year before his final presentation, the pain increased in severity and was accompanied by limitation in motion.

On physical examination, there was a non-tender mass measuring 9x12x4 cm at the anterior aspect of the knee between the inferior pole of the patella and the tibial tuberosity. The mass had a lobular surface which was firm on palpation on the medial side. Active and passive range of motion was 100 degrees, with 10 degrees of extension loss.

Direct radiographs of the left knee showed a large ossified lesion with irregular margins, located at the anatomical site of the patellar tendon, with signs of erosion to the inferior pole of the patella and the superior margin of the tibial tuberosity (Fig. 1). Computed tomography (CT)

• Received: June 23, 2004 Accepted: July 12, 2004

• Correspondence: Dr. Metin Manouchehr Eskandari, Mersin Üniversitesi Tıp Fakültesi Hastanesi Ortopedi ve Travmatoloji Anabilim Dalı, Zeytinlibahçe Cad., 33079 Mersin. Tel: 0324 - 327 30 60 Fax: 0324 - 337 43 05 e-mail: eskandari@mersin.edu.tr

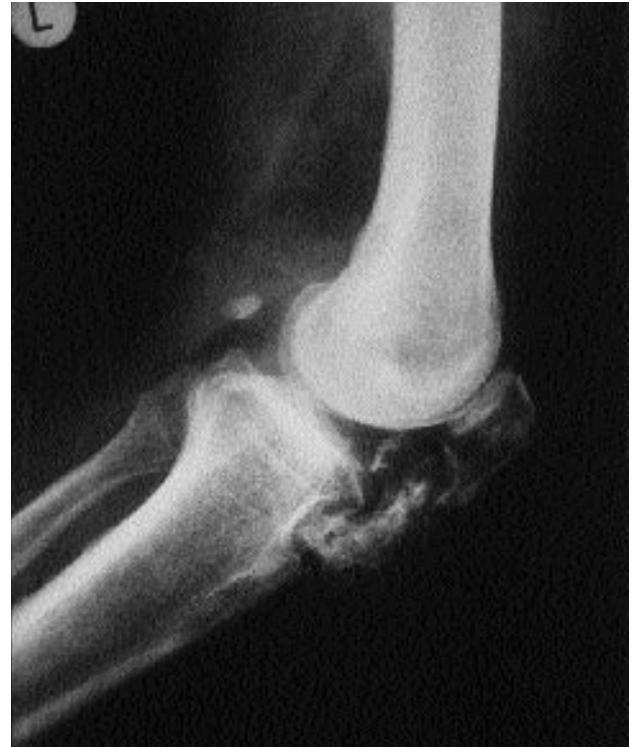revealed a lesion encircling the patellar tendon with nonhomogenous ossifying and nonossifying regions (Fig. 2).

Fine needle aspiration biopsy was obtained from the softer lateral side of the mass. Microscopically, the slides revealed spindle-shaped fibroblastic cells and chondrocytes in a slightly myxoid background. The cytological features were interpreted as a benign mesenchymal lesion.

At surgery, a medial parapatellar incision was made. The mass had two major lobes encircling the patellar tendon and joining posteriorly through a flat bony bridge. There were no adhesions to the surrounding tissues and no intra-articular component. The fat pad was compressed and displaced posteriorly. The mass was resected totally. The patellar tendon, though thinned and elongated, was intact. On the 14th postoperative day, the patient could walk pain-free without crutches and range of motion increased to 125 degrees.

Histopathological examination of the mass revealed a disorganized lobular cartilaginous structure covered by a fibrous membrane containing mature bone trabeculae and normal bone marrow (Fig. 3). The final diagnosis was extraarticular type synovial osteochondromatosis.

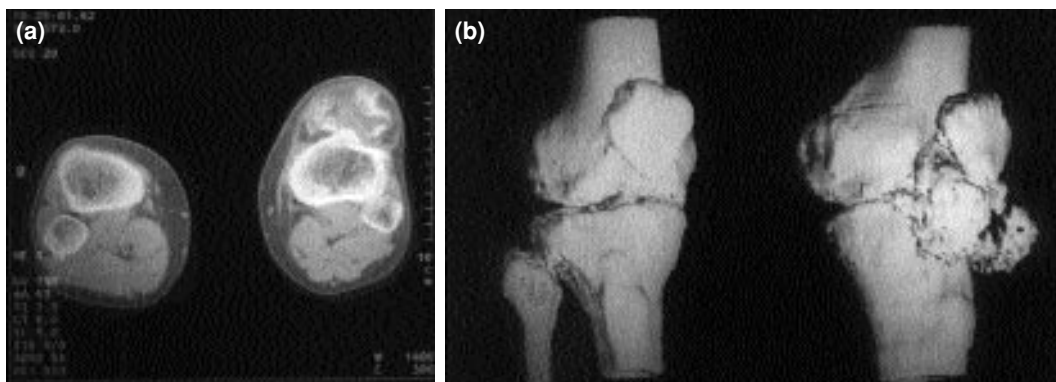
At his last follow-up control in the 40th postoperative month, the patient had minimal pain on the medial side of the knee joint and a full range of motion. No recurrence was detected clinically or radiographically (Fig. 4). The residual pain was thought to be related to degenerative arthritic changes.



**Fig. 1.** Preoperative lateral radiograph of the left knee showing a large ossified lesion at the anatomical site of the patellar tendon, with signs of erosion to the inferior pole of the patella and superior margin of the tibial tuberosity.

## DISCUSSION

The differential diagnosis of osteochondral tumors is difficult and could not solely be based upon histopathological findings.<sup>[1]</sup> Misdiagnosis of these lesions results in undertreatment or overtreatment.<sup>[4]</sup> The patient presented here had a mass around the patellar tendon, which is an unusual location. The long list of differential diagnosis was



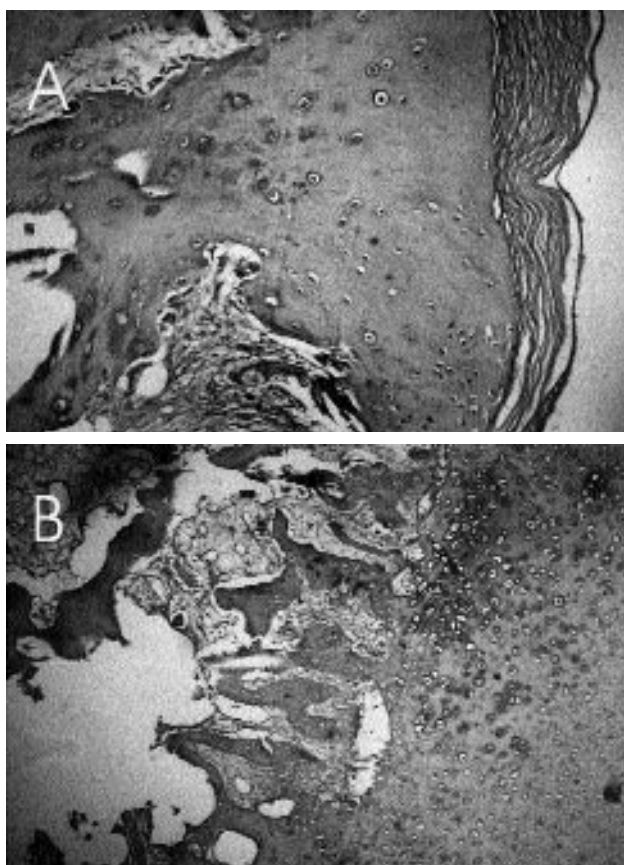
**Fig. 2.** (a) Preoperative CT scan showing the knee joint with a mass surrounding the patellar tendon. (b) Three-dimensional reconstruction CT view showing the knee joint with an ossified component of the mass around the patellar tendon.

narrowed based upon clinical, radiographical, CT, intraoperative, cytological, and histopathological findings. The final diagnosis was extraarticular synovial osteochondromatosis. Other potential causes were investigated in three groups. The first group was benign tumorous conditions which might appear as peri- or intra-articular radiodensities, including osteochondroma and osteochondroma-like lesions,<sup>[1,4]</sup> chondroma,<sup>[1,4]</sup> myositis ossificans,<sup>[2]</sup> and calcified Hoffa's disease.<sup>[5]</sup> The other group involved causes of radiodensity within the patellar tendon, which were extensive post-traumatic ossification of the patellar tendon<sup>[6]</sup> and calcified chronic tendinitis.<sup>[7]</sup> The third group was malignant tumors which might present as periarticular masses of radiodensity, such as parosteal osteosarcoma, chondrosarcoma, synovial sarcoma, and synovial chondrosarcoma.<sup>[3,4]</sup>

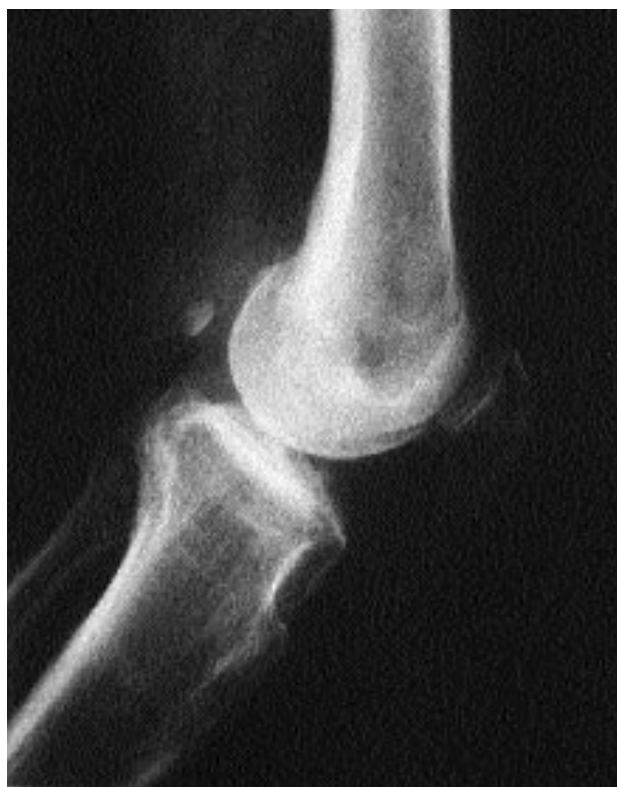Synovial osteochondromatosis is a benign tumorous condition which begins with metaplasia of the synovial tissue. It may occur within synovial

joints, extraarticular bursal cavities, and tendon sheaths.<sup>[8,9]</sup> The knee region is the most commonly involved site and the lesions are frequently intraarticular.<sup>[5,9,10]</sup> Extraarticular synovial chondromatosis is very rare, and its usual primary location is the posterior bursal cavities of the knee.<sup>[9]</sup> The most common symptom of extraarticular synovial osteochondromatosis is a slow-growing mass. It has no gender or age predilection, unlike the intraarticular form which is more common in young male adults.<sup>[11]</sup> Radiographically, signs of erosion to the surrounding bony structures may be present.<sup>[10,11]</sup> Histopathologically, it consists of disorganized lobular cartilage proliferations with patchy or diffuse calcification or endochondral ossification sites.<sup>[5]</sup>

In the literature, there are very few cases of osteochondral lesions located at the region of the patellar tendon. They were reported to originate from the infrapatellar bursa or fat pad.<sup>[10,11]</sup> The lesion presented here had an extraarticular anterior location, encircling the patellar tendon almost entirely, suggesting that it might have originated



**Fig. 3.** Photomicrographs showing (a) a fibrous membrane and cartilaginous tissue (b) with mature bone trabeculae and normal bone marrow (H-E x 40).



**Fig. 4.** Lateral radiograph of the left knee 40 months after surgery. The eroded regions of the inferior pole of the patella and the superior margin of the tibial tuberosity are still visible.

from the patellar tendon sheath rather than the infrapatellar bursa.

### REFERENCES

1. Carnesale PG. Benign tumors of bone. In: Canale ST, editor. *Campbell's operative orthopaedics*. 10th ed. St. Louis: Mosby; 2003. p. 793-811.
2. Carnesale PG. Soft tissue tumors and nonneoplastic conditions simulating bone tumors. In: Canale ST, editor. *Campbell's operative orthopaedics*. 10th ed. St. Louis: Mosby; 2003. p. 859-81.
3. Heck RK Jr. Malignant tumors of bone. In: Canale ST, editor. *Campbell's operative orthopaedics*. 10th ed. St. Louis: Mosby; 2003. p. 827-58.
4. Vigorita VJ, Ghelman B. Bone tumors and tumor-like lesions of the knee. In: Insall JN, Scott WN, editors. *Surgery of the knee*. 3rd ed. Philadelphia: Churchill Livingstone; 2001. p. 1977-96.
5. Vigorita VJ. The synovium: normal and pathological conditions. In: Insall JN, Scott WN, editors. *Surgery of the knee*. 3rd ed. Philadelphia: Churchill Livingstone; 2001. p. 1103-33.
6. Matsumoto H, Kawakubo M, Otani T, Fujikawa K. Extensive post-traumatic ossification of the patellar tendon. A report of two cases. *J Bone Joint Surg [Br]* 1999;81:34-6.
7. Azar FM. Traumatic disorders. In: Canale ST, editor. *Campbell's operative orthopaedics*. 10th ed. St. Louis: Mosby; 2003. p. 2449-93.
8. Hashimoto N, Okada K. Synovial osteochondromatosis of the retrocalcaneal bursa. A case report. *J Bone Joint Surg [Am]* 1996;78:1741-5.
9. Milgram JW, Hadesman WM. Synovial osteochondromatosis in the subacromial bursa. *Clin Orthop Relat Res* 1988;(236):154-9.
10. Steiner GC, Meushar N, Norman A, Present D. Intracapsular and paraarticular chondromas. *Clin Orthop Relat Res* 1994;(303):231-6.
11. Karlin CA, De Smet AA, Neff J, Lin F, Horton W, Wertzberger JJ. The variable manifestations of extraarticular synovial chondromatosis. *AJR Am J Roentgenol* 1981;137:731-5.