



## Subungual osteochondroma: a case report

### Subungual osteokondrom: Olgu sunumu

Özal Özcan, M.D.,<sup>1,2</sup> Hakan Boya, M.D.,<sup>1,2</sup> Şükrü Araç, M.D.,<sup>3</sup> Reha Tandoğan, M.D.<sup>1</sup>

<sup>1</sup>Department of Orthopedics and Traumatology, Medicine Faculty of Başkent University, <sup>2</sup>Zübeyde Hanım Training and Research Center; <sup>3</sup>Department of Orthopedics and Traumatology, Medicine Faculty of Dokuz Eylül University

Subungual osteochondroma is a benign osteochondral tumor usually involving the distal phalanx of the big toe. The exact diagnosis is challenging because many cases are initially misdiagnosed. An 18-year-old woman presented with a deformed nail of a six-month history in her right big toe. She had previous treatments for verruca vulgaris and pyogenic granuloma at two centers, respectively. Radiographic examination showed a pedunculated bony growth on the dorsum of the distal phalanx. Under digital nerve block, the lesion was removed from the distal phalanx by osteotomy. Histopathologic diagnosis was osteochondroma. Her complaints disappeared and no recurrence was observed within a follow-up of six months.

**Key words:** Osteochondroma/pathology/surgery; nail diseases/pathology/surgery; toes/pathology.

Subungual osteokondrom sıklıkla ayak birinci parmak distal falanksta görülen benign osteokondral bir tümördür. Subungual osteokondromu önemli kılan, birçok olguda başlangıçta yanlış tanı konmasıdır. On sekiz yaşında kadın hasta, sağ ayak başparmağında altı aydır var olan tırnak deformasyonu nedeniyle başvurdu. Daha önce iki merkezde verruca vulgaris ve piyojenik granülom tanılarıyla tedavi görmüştü. Radyografik incelemede distal falanksta, tırnağın altına doğru uzanan saplı kemik gelişimi görüldü. Sinir blokajı altında lezyon, osteotomi ile çıkarıldı. Histopatolojik tanı osteokondrom idi. Altı aylık izlem sırasında hastanın yakınlığı yoktu, nüks görülmedi.

**Anahtar sözcükler:** Osteokondrom/patoloji/cerrahi; tırnak hastalıkları/patoloji/cerrahi; ayak parmağı/patoloji.

Osteochondromas are benign osteochondral tumors that are rarely seen in subungual locations.<sup>[1]</sup> Clinically, they may be associated with nail deformities, pain, inconvenience in shoe wear, and sometimes secondary periungual infections.<sup>[2,3]</sup>

In this case report, we presented a patient in whom a simple and effective surgical technique was used to preserve the nail.

### CASE REPORT

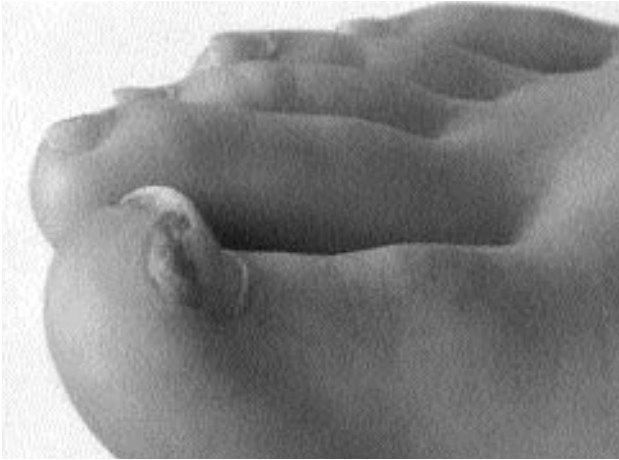An 18-year-old woman was admitted to our hospital with a deformed nail in her right big toe (Fig. 1). The lesion existed approximately for six months and showed a gradual growth, for which she had received two separate treatments with diagnoses

of verruca vulgaris and pyogenic granuloma, respectively. On physical examination, a hyperkeratotic nodule was noted under the distorted nail. An x-ray revealed a pedunculated bony growth on the dorsum of the distal phalanx (Fig. 2).

Under digital nerve block, a toe tourniquet was applied. Via an onychectomy, a distally based narrow strip of toenail of less than one-fourth of the nail width was removed. The lesion was removed from the distal phalanx by osteotomy. Any residual osteochondroma tissue was removed and a smooth surface was prepared by a fine rongeur. The wound was sutured to the nail fold with four stitches. A firm bandage was applied which was changed every three days during the next two

• Received: May 6, 2004 Accepted: August 1, 2005

• Correspondence: Dr. Özal Özcan. 36. Sokak, No: 4/10, 35290 Güzelyalı, İzmir.  
Tel: 0232 - 330 52 30 / 408 Fax: 0232 - 336 94 21 e-mail: ozalozcan@yahoo.com



**Fig. 1.** Subungual lesion in the big toe.

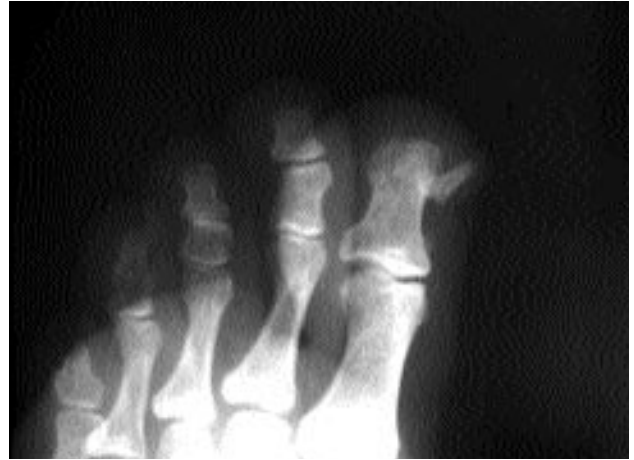weeks. With removal of the stitches after two weeks, the patient could gradually return to normal-width shoes.

On histopathologic examination of the lesion, a characteristic trabecular bone pattern covered with a hyaline cartilage cap was seen, confirming the diagnosis of osteochondroma (Fig. 3). At six months follow-up, the patient did not manifest any signs of recurrence (Fig. 4).

### DISCUSSION

Subungual osteochondromas are rare benign tumors that are commonly located on the dorsum of the distal phalanx.<sup>[4]</sup> In general, they are encountered between 10 to 25 years of age. Clinically, the lesion presents as firm, shiny, smooth-surfaced, and white-yellow nodules.<sup>[5]</sup>

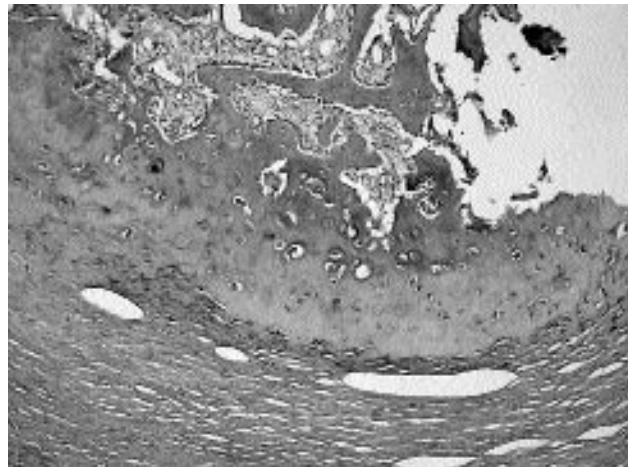
Osteochondromas can easily be misdiagnosed. The differential diagnosis includes benign lesions such as onychomycosis, verruca vulgaris, subungual fibroma, glomus tumor, pyogenic granuloma, subungual digital mucous cyst, and enchondroma, and malignant lesions such as osteosarcoma, squamous cell carcinoma, and malignant melanoma.<sup>[6,7]</sup> Radiographically, osteochondromas present as an exophytic bony growth protruding from the dorsal surface of the distal phalanx. A dorsoplantar radiograph may not demonstrate the lesion, but a lateral or oblique radiograph frequently enables the diagnosis.<sup>[7,8]</sup> Our patient had previously received treatment in two centers with two different diagnoses, which were verruca vulgaris and pyogenic granuloma, respectively. Finally, she sought treatment at our center with a deformed nail in her big toe. Clinical findings were consistent with osteochondroma and



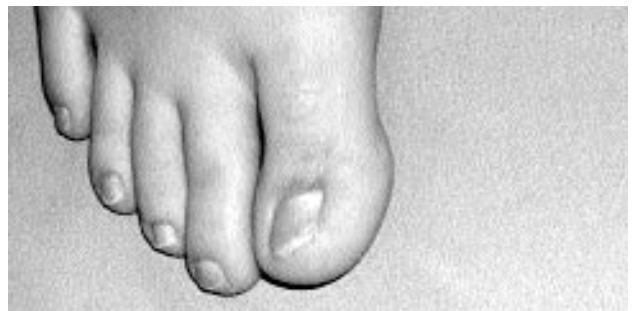**Fig. 2.** Radiograph of the subungual osteochondroma.

the diagnosis was supported by both radiographic and histopathologic examinations.

The wound is usually left to secondary healing.<sup>[9-11]</sup> Total or partial nail excision may cause an uncomfortable sensation at the tip of the toe, nail growth deformities, difficulty in returning to nor-



**Fig. 3.** Histopathology of the lesion showing mature trabecular bone formation covered by a cartilaginous cap.



**Fig. 4.** After six months, healing with excellent cosmetic appearance.

mal activity and shoe wear, as well as poor cosmetic appearance. The surgical method described herein enables radical excision of the lesion, with preservation of the nail and natural coverage of the operated phalanx, so that patients can have a rapid recovery and return to activity with excellent cosmetic appearance.

#### REFERENCES

1. Hodgkinson DJ. Subungual osteochondroma. *Plast Reconstr Surg* 1984;74:833-4.
2. Cohen HJ, Frank SB, Minkin W, Gibbs RC. Subungual exostoses. *Arch Dermatol* 1973;107:431-2.
3. Landon GC, Johnson KA, Dahlin DC. Subungual exostoses. *J Bone Joint Surg [Am]* 1979;61:256-9.
4. Eliezri YD, Taylor SC. Subungual osteochondroma. Diagnosis and management. *J Dermatol Surg Oncol* 1992;18:753-8.
5. Haneke E, Baran R, Bureaw H. Tumors of the nail apparatus and adjacent tissues. In: Bara R, Dawber RP, editors. *Diseases of the nails and their management*. Oxford: Blackwell Scientific; 1984. p. 424-9.
6. Apfelberg DB, Druker D, Maser MR, Lash H. Subungual osteochondroma. Differential diagnosis and treatment. *Arch Dermatol* 1979;115:472-3.
7. Coughlin MJ. Toenail abnormalities. In: Coughlin MJ, Mann RA, editors. *Surgery of the foot and ankle*. 7th ed. St. Louis: Mosby; 1999. p. 1043-6.
8. de Palma L, Gigante A, Specchia N. Subungual exostosis of the foot. *Foot Ankle Int* 1996;17:758-63.
9. Bostanci S, Ekmekci P, Ekinci C, Akcaboy B, Gurgey E. Subungual osteochondroma: a case report. *Dermatol Surg* 2001;27:591-3.
10. Dumontier CA, Abimelec P. Nail unit enchondromas and osteochondromas: a surgical approach. *Dermatol Surg* 2001;27:274-9.
11. De Berker DA, Langtry J. Treatment of subungual exostoses by elective day case surgery. *Br J Dermatol* 1999;140:915-8.