



Ranges of scapular elevation and depression in healthy male subjects

Sağlıklı erkeklerde skapula elevasyon ve depresyon genişliği

Hasan Hallaceli, PhD.,¹ Ali Cımbız, PhD.,² Uğur Cavlak, PhD.,³ İzge Günel, M.D.⁴

¹Department of Orthopedics, Medicine Faculty of Suleyman Demirel University;

²Department of Physical Therapy and Rehabilitation, Health Institution of Higher Education, Dumlupınar University;

³School of Physical Therapy and Rehabilitation, Pamukkale University;

⁴Department of Orthopedics, Medicine Faculty of Dokuz Eylül University

Objectives: Although most of the movements of the joints have been measured in several studies, data on scapular elevation and depression are very few. The aim of this study was to describe the amplitudes of active ranges of scapular elevation and depression in healthy male subjects, together with a comparison between the right and left sides.

Materials and methods: A total of 907 healthy right-handed male volunteers (mean age 20.9±1.8 years; range 19 to 30 years) were included in the study. Those with a history of illness, injury, or operation involving any joint of the upper extremity or cervical spine were excluded. Active scapular elevation, depression, and total elevation-depression ranges were measured with a manual goniometer under standardized conditions.

Results: The mean values for the right side elevation, depression, and total elevation and depression were 41.03±5.98, 4.16±4.47, and 36.88±6.19 degrees, respectively. The corresponding values for the left side were 41.88±5.95, 5.38±4.43, 36.50±6.05 degrees, respectively. There were significant differences between the right and left side values of scapular elevation (p=0.002) and depression (p=0.000), including the rest position (p=0.000). However, there was no significant difference between the two sides with respect to the total elevation and depression (p=0.3).

Conclusion: Normal values given in the present study can be used in clinical evaluations. However, due to significant differences between the two sides, contralateral values should not be used as reference.

Key words: Laterality; range of motion, articular/physiology; reference values; scapula/physiology; shoulder joint/physiology.

Amaç: Eklemlerin hemen hemen tüm hareketleri birçok çalışmada ele alındıysa da, skapula elevasyonu ve depresyonu konusunda literatürde çok fazla veri yoktur. Bu çalışmada, sağlıklı erkeklerde skapula elevasyonu ve depresyonunun aktif genişliklerinin belirlenmesi ve sağ ve sol tarafların karşılaştırılması amaçlandı.

Olgular ve yöntemler: Çalışmaya, baskın olarak sağ elini kullanan 907 sağlıklı erkek gönüllü (ort. yaş 20.9±1.8; dağılım 19-30) alındı. Üst ekstremitede ya da servikal omurgada eklemlerle ilgili herhangi bir hastalık, yaralanma ya da ameliyat öyküsü olanlar çalışmaya alınmadı. Skapula elevasyon, depresyon ve toplam elevasyon-depresyon genişlikleri standart şartlar altında el gonyometresiyle ölçüldü.

Bulgular: Sağ taraf için ortalama elevasyon, depresyon ve toplam elevasyon-depresyon değerleri sırasıyla 41.03±5.98, 4.16±4.47, 36.88±6.19 derece iken, aynı değerler sol taraf için sırasıyla 41.88±5.95, 5.38±4.43, 36.50±6.05 bulundu. İstirahat pozisyonu (p=0.000), elevasyon (p=0.002) ve depresyonda (p=0.000) elde edilen değerler açısından sağ ve sol taraflar arasında anlamlı farklılık bulundu. Toplam elevasyon-depresyon değerleri ise iki taraf arasında anlamlı farklılık göstermedi (p=0.3).

Sonuç: Bu çalışmada elde edilen sonuçlar normal değerler olarak kullanılabilir. Ancak, iki taraf arasındaki anlamlı farklılık nedeniyle klinik değerlendirmede karşı taraf referans olarak kullanılmamalıdır.

Anahtar sözcükler: Laterallite; hareket açıklığı, eklem/fizyoloji; referans değeri; skapula/fizyoloji; omuz eklemi/fizyoloji.

Measurement of the range of motion (ROM) of a joint is commonly recorded by health professionals during clinical evaluation for various reasons, including baseline evaluation, evaluation of the treatment procedure, feedback to the patient, assessment of work capacity, or for research studies.^[1,2]

Although a number of reports have provided estimates of the normal ROM of the joints of the upper extremity, a careful review of the literature would reveal very few data on the normal range of scapular elevation, depression, and total elevation and depression.^[1-6] Normal shoulder motion, force development, force regulation, and ligamentous tension require coupling of scapular motions including elevation and depression, and humeral motion. Alterations in resting scapular position and dynamic scapular motion have been recognized commonly in association with many types of shoulder pathologies, such as impingement, instability, and rotator cuff tears. Scapular elevation is challenging because the overlying muscle mass obscures surface landmarks and scapular moments occur under the skin.^[7-9]

The aim of this study was to describe the amplitudes of active ranges of scapular elevation and depression in healthy male subjects, together with a comparison between the right and left sides.

MATERIALS AND METHODS

All subjects were informed about the measurements and gave informed consent for participation. A total of 907 healthy right-handed male volunteers (mean age 20.9 ± 1.8 years; range 19 to 30 years) were included in the study, and all participants were recruited from the Isparta Headquarters of Ministry of National Defence, the Republic of Turkey. Individuals who were found to have a history of illness, injury, or operation involving any joint of either the upper extremity or cervical spine were excluded.

Active scapular elevation, depression, and total elevation-depression ranges were measured with a full-circle manual goniometer made of flexible clear plastic, with arms 30 cm long, that met the requirements of a universal goniometer described by Moore.^[10] The protector portion was divided into 1-deg increments. A small scale placed on the arm enabled measurements to the nearest degree.

The examiners were familiar with specific recommendations or instructions that defined the appropriate position of the subjects and the alignment of the goniometer. All the subjects were advised to rest and relax before the test. The subject was seated on a stool in an upright position, with the arms dangling freely. Any tilt or rotation of the trunk and the neck were avoided throughout the measurements. The goniometer was placed with its fulcrum centered in the midpoint of the jugular notch; the stationary arm was placed parallel to the sternum, and the movable arm could be freely positioned from the fulcrum to the most prominent point of the anterior portion of the acromion.^[1,3,4]

The ranges of scapular elevation and depression were measured by the examiner and the best score was recorded.

In order to reduce the effect of muscle fatigue, the subjects were allowed to rest for a minute between two consecutive measurements. The measurements were first performed on the right side (Fig. 1).

Data analysis

Measurements were expressed as means and standard deviations. Data for side differences were analyzed using the Mann-Whitney U-test and a *p* value of less than 0.05 was considered significant. The precision of the frequency was estimated with a 95% confidence interval (CI). Data analyses were performed using the SPSS statistical package, version 10.0.

RESULTS

The mean scapular total elevation-depression was 36.88 ± 6.19 degrees on the right and 36.50 ± 6.05 degrees on the left. There were significant differences between the right and left side values of scapular elevation ($p=0.002$; 95% CI, -1.117 to -0.584) and depression ($p=0.000$; 95% CI, -1.4639 to -0.9859), including the rest position ($p=0.000$; 95% CI, -1.4351 to -1.0192) (Table I).

DISCUSSION

Objective measurements of joint function are required with increasing frequency as indices of improvement following a course of treatment.^[1] Although there are several reports in the literature concerning the normal ROM of upper extremity joints,^[2,5,11,12] data are limited on the normal ROM of the scapular elevation and depression.^[3,4,13]

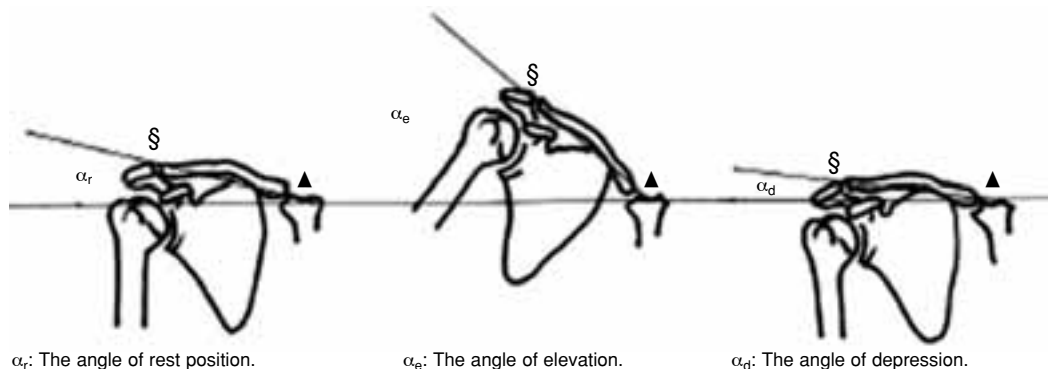


Fig. 1. Clinical measurement of scapular elevation and depression. The goniometer is placed with the fulcrum centered in the mid-point of the jugular notch (▲). The stationary arm is placed parallel to the sternum, and the movable arm from the fulcrum to the most prominent point of the anterior portion of the acromion (§).

Measurements for the ROM of joints are commonly conducted by health care providers during clinical evaluation of the patients for various reasons, including initial evaluation, evaluation of the treatment procedure, feedback to the patient, or for research studies.^[3,14-17]

Most of the studies in the literature about measuring scapulohumeral kinematics used various methods including electromagnetic movement sensors, a transducer, potentiometer, or a goniometer.^[3,14-18] However, other than the goniometer, none is practical for health care providers in assessing patients during routine procedures.

Scapular elevation and depression are performed in the sternoclavicular and scapulothoracic joints in the sagittal plane, without any contribution of the glenohumeral joint. Measuring scapular elevation and depression is somewhat more difficult than measuring other movements of the shoulder, in that the scapular motion requires coupling of humeral motion, the scapular joint has an irregular structure, and does not have a reference

point to measure its ROM. These may account for the presence of relatively few studies in the literature.

McRae^[12] reported a maximal total excursion of 12 cm, but as scapular rotation contributes to elevation and depression, we feel that it is more convenient to express its movement in degrees, rather than in centimeters in order to make comparisons possible among individuals. In a previous report, we measured scapular elevation ($37.65 \pm 4.95^\circ$) and depression ($8.44 \pm 2.0^\circ$) in degrees in 15 healthy male subjects.^[3] Differences between these studies may be due to the greater number of the subjects included in the present study.

The results of this study showed significant differences between elevation and depression values in favor of the non-dominant left side ($p < 0.05$). This is in accordance with a previous study which found that most of the movements in the upper extremity were greater on the left side.^[1] However, there was no difference between the two sides with respect to the total elevation and depression

TABLE I
Comparison of scapular elevation and depression

Motion	ROM (Mean±SD, degrees)		Mann-Whitney U-test		95% CI of the differences	
	Right side	Left side	z	p	Lower	Upper
Rest position	9.48±4.37	10.71±3.99	-6.03	0.000*	-1.4351	-1.0192
Elevation	41.03±5.98	41.88±5.95	-3.14	0.002*	-1.1117	-0.5840
Depression	4.16±4.47	5.38±4.43	-5.42	0.000*	-1.4639	-0.9859
Total elevation & depression	36.88±6.19	36.50±6.05	-1.014	0.311	0.0710	0.6831

*Significant difference ($p < 0.05$).

($p=0.3$; Table I). In addition, we found an average elevation excursion of 10 degrees during the rest position, suggesting that elevated shoulder was common as a postural alignment in healthy male subjects.

In conclusion, external and internal rotations of the scapular joint are included in almost all shoulder scoring systems. It is well known that scapular elevation and depression contribute to these movements.^[12,19-21] Any impairment in scapular elevation and depression may affect the assessment of shoulder rotation. Thus, measuring the scapular shrug should be considered in all the measurements of the shoulder ROM.

Acknowledgments

The authors would like to thank to Dr. A. Hüsrev Eroğlu for statistical analyses and to the representatives of the Isparta Headquarters of Ministry of National Defence, the Republic of Turkey, for their kind permission to perform this study.

REFERENCES

1. Gunal I, Kose N, Erdogan O, Gokturk E, Seber S. Normal range of motion of the joints of the upper extremity in male subjects, with special reference to side. *J Bone Joint Surg [Am]* 1996;78:1401-4.
2. Magee DJ. Shoulder. In: *Orthopedic physical assessment*. 3rd ed. Philadelphia: W. B. Saunders; 1997. p. 175-246.
3. Hallaceli H, Gunal I. Normal range of scapular elevation and depression in healthy subjects. *Arch Orthop Trauma Surg* 2002;122:99-101.
4. Hallaceli H, Manisali M, Gunal I. Does scapular elevation accompany glenohumeral abduction in healthy subjects? *Arch Orthop Trauma Surg* 2004;124:378-81.
5. Kibler WB, Uhl TL, Maddux JW, Brooks PV, Zeller B, McMullen J. Qualitative clinical evaluation of scapular dysfunction: a reliability study. *J Shoulder Elbow Surg* 2002;11:550-6.
6. Poppen NK, Walker PS. Normal and abnormal motion of the shoulder. *J Bone Joint Surg [Am]* 1976;58:195-201.
7. Ludewig PM, Cook TM. Alterations in shoulder kinematics and associated muscle activity in people with symptoms of shoulder impingement. *Phys Ther* 2000; 80:276-91.
8. Palmer AK, Werner FW, Murphy D, Glisson R. Functional wrist motion: a biomechanical study. *J Hand Surg [Am]* 1985;10:39-46.
9. Wuelker N, Schmotzer H, Thren K, Korell M. Translation of the glenohumeral joint with simulated active elevation. *Clin Orthop Relat Res* 1994;(309):193-200.
10. Moore ML. The measurement of joint motion. Part II. The technique of goniometry. *Phys Ther Rev* 1949;29: 256-64.
11. Bigliani LU, Perez-Sanz JR, Wolfe IN. Treatment of trapezius paralysis. *J Bone Joint Surg [Am]* 1985; 67:871-7.
12. McRae R. The shoulder. In: *Clinical orthopaedic examination*. 3rd ed. Singapore: Churchill Livingstone; 1989. p. 40-56.
13. Youdas JW, Carey JR, Garrett TR, Suman VJ. Reliability of goniometric measurements of active arm elevation in the scapular plane obtained in a clinical setting. *Arch Phys Med Rehabil* 1994;75:1137-44.
14. Barnett ND, Duncan RD, Johnson GR. The measurement of three dimensional scapulohumeral kinematics-a study of reliability. *Clin Biomech* 1999;14:287-90.
15. Boissonnault WG, Janos AC. Dysfunction, evaluation, and treatment of the shoulder. In: Donatelli R, Wooden M, editors. *Orthopaedic physical therapy*. New York: Churchill Livingstone; 1989. p. 151-60.
16. de Groot JH, Brand R. A three-dimensional regression model of the shoulder rhythm. *Clin Biomech* 2001;16: 735-43.
17. Ludewig PM, Cook TM, Nawoczenski DA. Three-dimensional scapular orientation and muscle activity at selected positions of humeral elevation. *J Orthop Sports Phys Ther* 1996;24:57-65.
18. Riddle DL, Rothstein JM, Lamb RL. Goniometric reliability in a clinical setting. *Shoulder measurements*. *Phys Ther* 1987;67:668-73.
19. Browne AO, Hoffmeyer P, Tanaka S, An KN, Morrey BF. Glenohumeral elevation studied in three dimensions. *J Bone Joint Surg [Br]* 1990;72:843-5.
20. Kebaetse M, McClure P, Pratt NA. Thoracic position effect on shoulder range of motion, strength, and three-dimensional scapular kinematics. *Arch Phys Med Rehabil* 1999;80:945-50.
21. Voss DE, Ionta MK, Myers BJ, editors. *Patterns of motion*. In: *Proprioceptive neuromuscular facilitation: patterns and techniques*. 3rd ed. Philadelphia: Harper&Row; 1985. p. 69-99.