



Subtrochanteric femur fracture following hip arthrodesis: a report of three cases

Kalça artrodezinden sonra meydana gelen subtrokanterik femur kırığı: Üç olgu sunumu

Basil J. Alwattar, M.D., Kenneth A Egol, M.D.

Department of Orthopedic Surgery, The New York University Hospital for Joint Diseases

The use of hip arthrodesis for the treatment of various arthritic conditions has dramatically decreased since the advent and success of hip arthroplasty. Subtrochanteric femur fracture below a long-standing hip arthrodesis is a rare complication that is difficult to treat. There are many factors to be considered in selecting among multiple options for the treatment of this fracture. We present three cases of subtrochanteric femur fractures that occurred long after hip arthrodesis, in which treatment was tailored to the individual patient- and fracture-based characteristics, often requiring multiple procedures.

Key words: Arthrodesis/adverse effects; femoral fractures/etiology/surgery; fracture fixation, intramedullary; hip joint/surgery.

Çeşitli artritlik durumların kalça artrodezi ile tedavisi, kalça artroplastisinin kullanılmaya başlanması ve başarısıyla büyük düşüş göstermiştir. Uzun süreli kalça artrodezinin aşağısında meydana gelen subtrokanterik femur kırığı, tedavisi zor bir komplikasyondur. Bu kırığın tedavisinde var olan çok sayıda seçenek içinden seçim yaparken dikkate alınması gereken faktörler vardır. Bu yazıda, kalça artrodezinden uzun zaman sonra subtrokanterik femur kırığı gelişen üç olgu sunuldu. Her bir olguda tedavi hastaya ve kırığa ait özelliklere göre düzenlendi ve zaman zaman birden çok işleme başvuruldu.

Anahtar sözcükler: Artrodez/yan etki; femur kırığı/etyoloji/cerrahi; kırık tespiti, intramedüller; kalça eklemi/cerrahi.

With the continued success of total hip arthroplasty, hip arthrodesis has become a rare surgical procedure.^[1] Yet, hip arthrodesis has been, and is still used in the treatment of a variety of hip pathologies.^[2,3] Long-term follow-up studies of patients with hip arthrodesis report a variety of adverse sequelae. Hip arthrodesis affects the biomechanical function of the lower extremity. The most commonly reported sequelae are back pain and pain in adjacent joints of the lower extremities.^[4-8] Very few cases of hip arthrodesis complicated by ipsilateral hip or femur fracture have been reported in the orthopaedic literature. A review of long-term follow-up studies of hip arthrodesis and case series/reports revealed less than 50 such fractures including 19 ipsilateral intertrochanteric fractures, two case reports of ipsilateral trochanteric fracture,

a case report of femoral neck fracture, and a series of proximal femoral shaft fractures.^[4-12] The largest series, from 1976, reported 19 ipsilateral femur fractures after hip arthrodesis but described only one as subtrochanteric.^[13] Treatment options reported include retrograde intramedullary nailing, compression plating, fixed-angle devices, and internal fixation to the pelvis, with varying degrees of success. In this series, we present three ipsilateral subtrochanteric femur fractures following long-standing hip arthrodesis, each treated in a unique surgical manner. Based on our results and of those cases previously reported in the literature, it is clear that this fracture pattern is difficult to treat, often necessitating multiple surgical procedures. Elimination of pain and improved patient function should be the goal of the treating surgeon.

• Received: October 19, 2006 Accepted: December 25, 2006

• Correspondence: Kenneth A Egol, MD, NYU-Hospital for Joint Diseases, Department of Orthopaedic Surgery, 301 East 17th Street, New York, NY, 10003 USA. Tel: +00-1-212-598-6000 Fax: +00-1-212-598-6015 e-mail: egolk01@nyumc.org

CASE REPORT

Case 1- A 45-year-old male had a history of left hip arthrodesis secondary to severe posttraumatic arthritis 15 years before. Five years after hip arthrodesis, he was involved in a motor vehicle collision and sustained a subtrochanteric fracture below the hip arthrodesis. The patient underwent five surgical procedures to treat the fracture, at outside institutions, but reported that the fracture never healed, and complained of persistent pain in the left thigh. Radiographs obtained on presentation revealed nonunion of the fracture site with failure of the surgical hardware (Fig. 1a). Infection work-up showed an elevated erythrocyte sedimentation rate and C-reactive protein

and nuclear medicine scans were consistent with an infected nonunion of the fracture. Upon diagnosis, the patient was taken to the operating room for irrigation and debridement of the hip, removal of hardware and placement of antibiotic beads (Fig. 1b). Cultures from the operation site grew *Staphylococcus aureus* and the patient received a six-week course of intravenous antibiotics. Resolution of the infection was monitored with serial infection labs and nuclear medicine studies. Upon normalization of laboratory and scintigraphic findings, the patient returned to the operating room for a conversion of the hip arthrodesis to a noncemented, distal filling, total hip arthroplasty (Fig. 1c). Intraoperative frozen

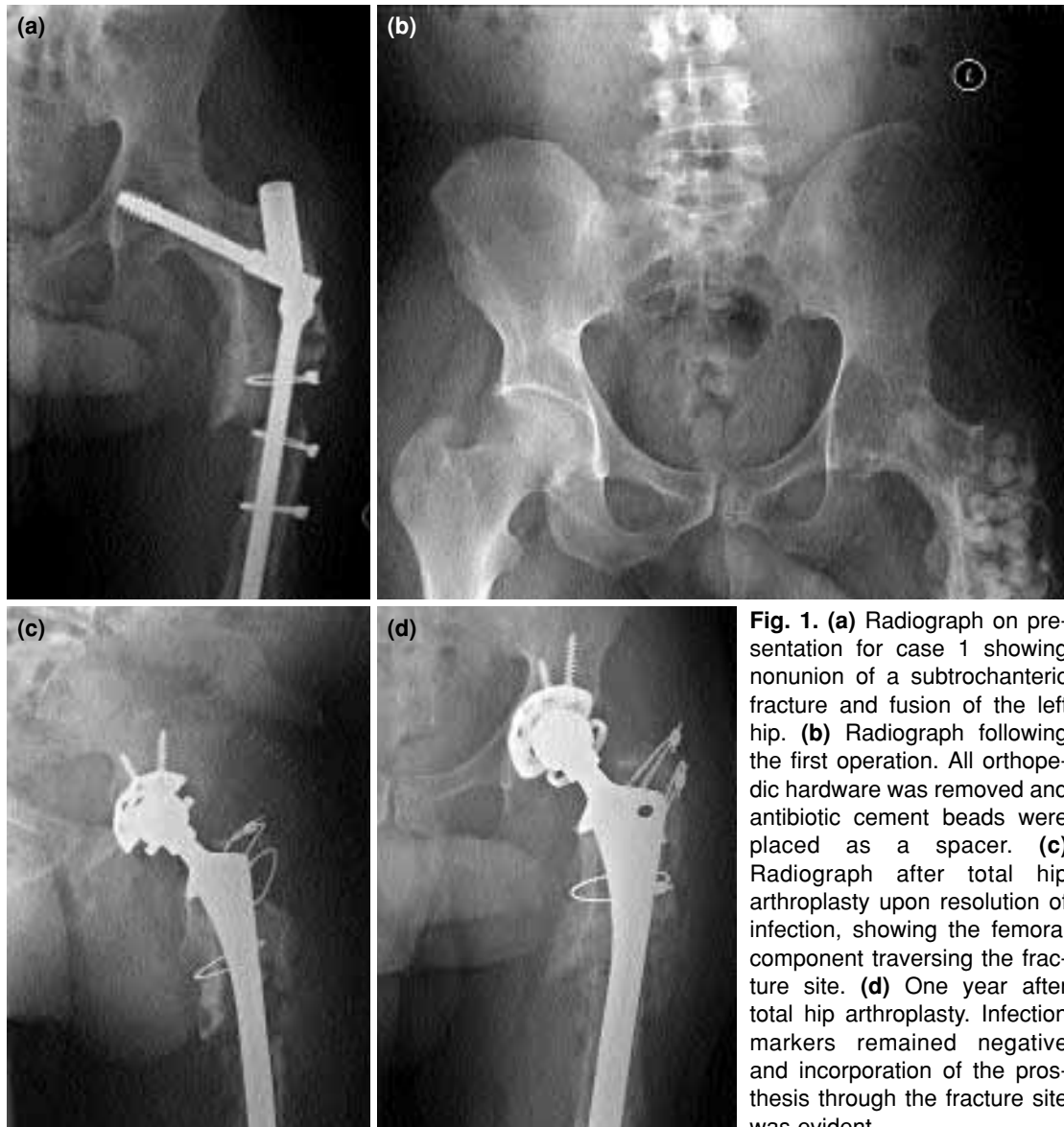

Fig. 1. (a) Radiograph on presentation for case 1 showing nonunion of a subtrochanteric fracture and fusion of the left hip. (b) Radiograph following the first operation. All orthopedic hardware was removed and antibiotic cement beads were placed as a spacer. (c) Radiograph after total hip arthroplasty upon resolution of infection, showing the femoral component traversing the fracture site. (d) One year after total hip arthroplasty. Infection markers remained negative and incorporation of the prosthesis through the fracture site was evident.

section analysis of periarticular tissues and cultures were negative. Postoperatively, the patient did well. There was no recurrence of infection. Partial weight-bearing was allowed for three months and full weight-bearing thereafter. The patient was pain free, ambulating with an assistive device and without signs of infection at one year follow-up. Radiographs revealed incorporation of the prosthesis into the femur (Fig. 1d).

Case 2— A 49-year-old male with a history of bipolar disorder and alcohol/substance abuse underwent hip arthrodesis for severe osteoarthritis secondary to avascular necrosis 15 years before (Fig. 2a). He presented one year after a subtrochanteric femur fracture that had occurred after a motor vehicle accident, with a locked retrograde femoral nail placed at an outside hospital. He was ambulatory but complained of pain in the left thigh and knee since the time of the accident. Radiographs revealed a hypertrophic nonunion of the subtrochanteric fracture (Fig. 2b). Work-up for infection was negative. The previous femoral nail was replaced with a larger retrograde, dynamized, reamed nail, bone-grafting was performed, and a hip spica cast was applied for four months, during which time partial weight-bearing was allowed (Fig. 2c).

After removal of the spica cast, the patient complained of persistent knee and thigh pain. Follow-up with serial radiographs confirmed a persistent nonunion of the fracture site. One year after the first operation, he underwent removal of the intramedullary nail, take-down of the nonunion site, bone grafting, internal fixation with a fixed-angle device, and placement of a bone growth stimulator (Fig. 2d). Postoperatively, he was placed in a hip spica brace and made partial weight-bearing. Two months postoperatively, weight-bearing was allowed as tolerated. At six months, the patient was pain free and returned to his pre-injury activity level with full weight-bearing. Three years postoperatively, he had no complaints of thigh pain, but reported persistent knee pain and low back pain, both of which are currently being treated nonoperatively.

Case 3— A 49-year-old male who was 20 years status post-arthrodesis of the right hip for posttraumatic arthritis sustained a subtrochanteric femur fracture below the hip arthrodesis after a fall down five steps (Fig. 3a). The patient complained of right thigh pain, no other injuries were documented. He

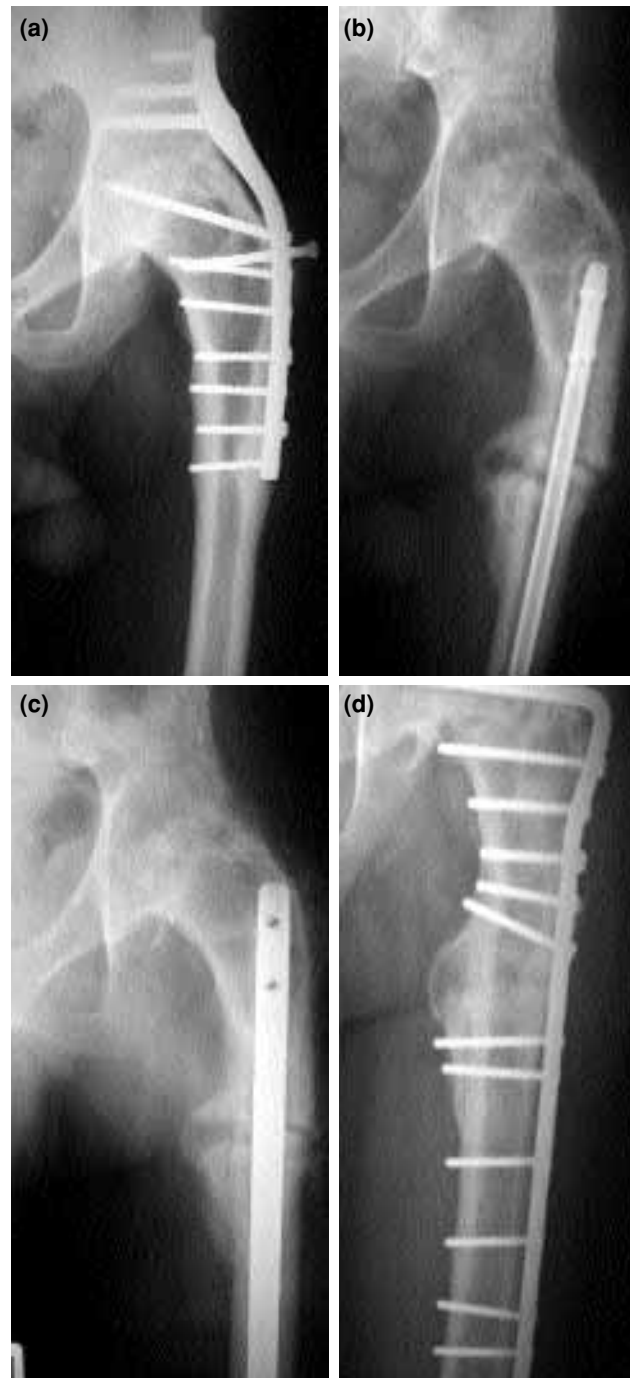

Fig 2. (a) Radiograph of case 2 showing a primary hip fusion with cobra plate. (b) Radiograph on presentation showing nonunion of a subtrochanteric femur fracture. (c) Radiograph following exchange of nailing and bone grafting of fracture site. (d) Radiograph after second operation showing removal of intramedullary nail and placement of a fixed angled device.

underwent removal of hardware, open reduction of the fracture and internal fixation with a proximal femoral locking plate (Fig. 3b). At surgery, it was determined that the arthrodesis screws placed

in the femoral neck and into the pelvis were irretrievable and that locked plating would provide fixation and avoid the retained hardware. The patient was made foot flat weight-bearing postoperatively and was discharged from the hospital.

Two weeks later, the patient presented to the office with increased pain in the thigh. Radiographs revealed failure of the ortopedic hardware (Fig. 3c). The patient denied any trauma or unusual activity. It was noted that the plate had fractured, leaving the fracture site unstable. At revision surgery, the locking plate was removed and reamed, antegrade, cephalo-medullary nailing was performed (Fig. 3d). Postoperatively, the patient was again made foot flat weight-bearing and work-up for infection was negative. Three months after the latest procedure, the patient was doing well with signs of fracture healing.

DISCUSSION

Subtrochanteric femur fractures below a long-standing hip arthrodesis are rare and complex injuries. In this series, none of the fractures healed with initial fixation, two requiring more than one revision with the possibility of additional procedures. A review of these and other reported cases may provide a guideline for the treatment of these fractures.

Stoltz and Ganz^[13] suggested that the implants used for hip arthrodesis be removed prophylactically after arthrodesis to eliminate their stress shielding effect at the distal most part of the fixation device, thereby lessening the risk for fracture. This does not appear to be a common practice and may not make a significant difference. As seen in our cases, these patients sustained injuries after mechanisms that involved significant amounts of energy. Fracture might have occurred even if original hardware had been removed. The subtrochanteric region of the femur is already subject to significantly high stresses and arthrodesis of the joint above merely contributes to these stresses.

In treating these fractures, several issues must be taken into account. The presence and condition of implanted hardware, the possibility that sub-clinical infection may be present and be the cause of a nonunion, and finally the patient's functional status which plays a major role in determining the proper treatment. High stresses at the subtrochanteric region exert a negative effect on fracture healing. Conversion of an arthrodesed hip to total hip arthroplasty has been shown to have a high level of success^[3] and may allow for osseous union with integration of prosthetic components. Furthermore, this approach may eliminate long-

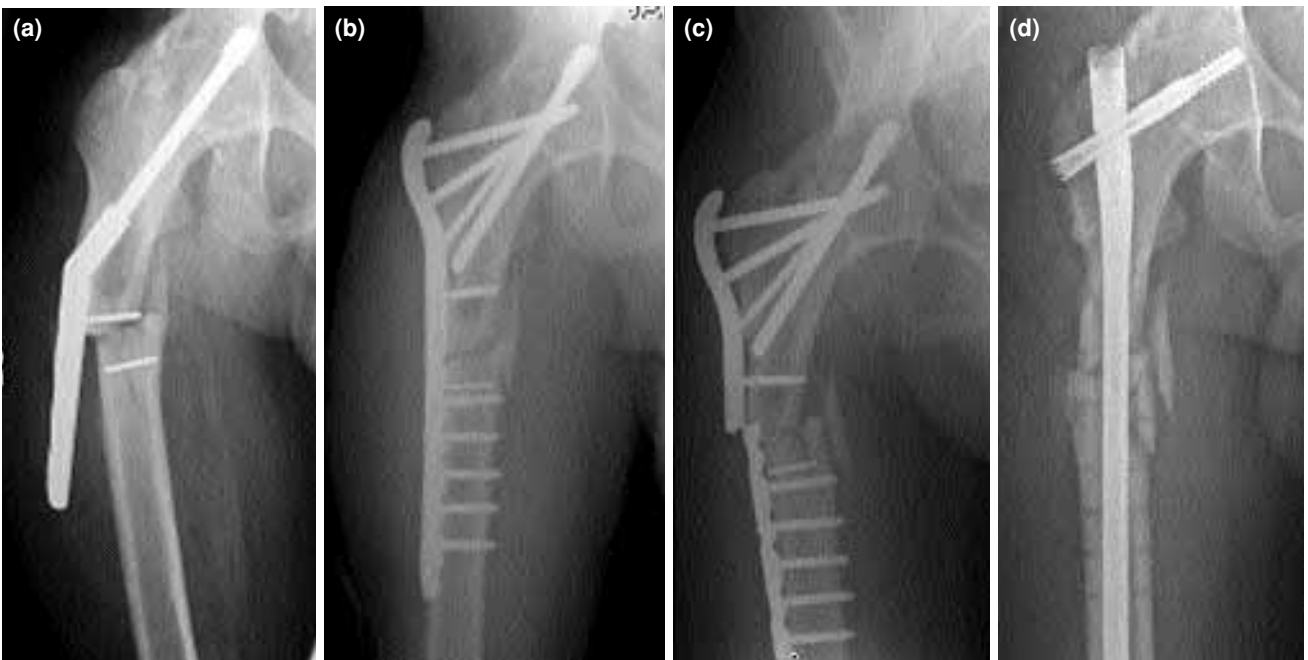


Fig 3. (a) Subtrochanteric femur fracture below the hip arthrodesis in case 3. (b) Radiograph after open reduction and internal fixation with a proximal femoral locking plate. (c) Radiograph showing failure of the hardware two weeks after the initial operation. (d) Radiograph after revision surgery, with all the previous implants removed, and a cephalo-medullary nail placed.

standing problems of hip arthrodesis, such as ipsilateral back and knee pain. However, most patients may not desire conversion to total joint arthroplasty and wish to remain fused.^[14] In case 1, total hip arthroplasty provided increased function and fracture fixation and resulted in an improved outcome for the patient. Total hip arthroplasty may be the best option for motivated patients.

Treatment with intramedullary nailing was reported to be successful in two cases of ipsilateral femoral shaft fractures after hip arthrodesis.^[11] These fractures were more distal to those presented here and were fixed in a retrograde manner.^[11] Intramedullary fixation in case 2 did not provide sufficient stability and resulted in a hypertrophic nonunion which was eventually converted to a fixed-angle device with bone grafting. Retrograde nailing in this patient also led to a significant amount of knee pain. In the third case, the patient was successfully revised to an intramedullary nail. In less compliant patients, intramedullary nailing allows weight-bearing as tolerated and does not require the same level of compliance as with total hip arthroplasty.

In our second and third cases, fixed-angle plate and screw fixation were utilized. Fixed-angle devices may serve a roll in the treatment of nonunions in patients who may not be candidates for, or amenable to, total hip arthroplasty. Other options described include compression plating with bone grafting,^[13] and intramedullary fixation into the ilium.

There are a variety of options for the treatment of ipsilateral subtrochanteric femur fractures after hip arthrodesis, as demonstrated by our case series. Due to the infrequent incidence of this fracture pattern, a controlled study is not possible. These fractures are difficult to manage and often need multiple procedures. Consideration of the patient's function, the

patient's compliance and desires may guide physicians for the treatment of this injury.

REFERENCES

1. Clohisy JC, Curry MC, Fejfar ST, Schoenecker PL. Surgical procedure profile in a comprehensive hip surgery program. *Iowa Orthop J* 2006;26:63-8.
2. Beaulé PE, Matta JM, Mast JW. Hip arthrodesis: current indications and techniques. *J Am Acad Orthop Surg* 2002;10:249-58.
3. Joshi AB, Markovic L, Hardinge K, Murphy JC. Conversion of a fused hip to total hip arthroplasty. *J Bone Joint Surg [Am]* 2002;84:1335-41.
4. Callaghan JJ, Brand RA, Pedersen DR. Hip arthrodesis. A long-term follow-up. *J Bone Joint Surg [Am]* 1985; 67:1328-35.
5. Greiss ME, Thomas RJ, Freeman MA. Sequelae of arthrodesis of the hip. *J R Soc Med* 1980;73:497-500.
6. Lipscomb PR, McCaslin FE Jr. Arthrodesis of the hip. Review of 371 cases. *J Bone and Joint Surg [Am]* 1961; 43:923-38.
7. Stewart MJ, Coker TP Jr. Arthrodesis of the hip. A review of 109 patients. *Clin Orthop Relat Res* 1969; (62): 136-50.
8. Stinchfield FE, Cavallaro WU. Arthrodesis of the hip joint; a follow-up study. *J Bone Joint Surg [Am]* 1950; 32:48-58.
9. Mullaji AB, Todd RC. Late ipsilateral trochanteric fractures in patients with long-standing fusion of the hip. *Injury* 1991;22:233-5.
10. Sponseller PD, McBeath AA, Perpich M. Hip arthrodesis in young patients. A long-term follow-up study. *J Bone Joint Surg [Am]* 1984;66:853-9.
11. Wong TC, Rikhranj IS. Femoral shaft fracture in a hip arthrodesis: two cases of retrograde interlocking nailing. *Singapore Med J* 2004;45:85-7.
12. Wulke AP, Mader K, Pennig D. Femoral neck fracture in an arthrodesed hip treated by a supracondylar intramedullary locked nail. *J Orthop Trauma* 2004;18: 116-8.
13. Stoltz MR, Ganz R. Fracture after arthrodesis of the hip and knee. *Clin Orthop Relat Res* 1976;(115):177-81.
14. Sofue M, Kono S, Kawaji W, Homma M. Long term results of arthrodesis for severe osteoarthritis of the hip in young adults. *Int Orthop* 1989;13:129-33.