



Acute compartment syndrome of the thigh: diagnosis and management

Uyluğun akut kompartman sendromu: Tanı ve tedavi

Alexis S. Chiang, M.D., Nirmal C. Tejwani, M.D.

Department of Orthopedic Surgery, The New York University Hospital for Joint Diseases

Objectives: The purpose of this study was to review our experience with compartment syndrome (CS) of the thigh and to provide guidelines for its management.

Patients and methods: The study included 10 cases of thigh CS in seven male patients (mean age 26 years; range 17 to 47 years). The mechanisms of injury included trauma due to a motor vehicle accident, sports injuries (n=2), blunt trauma, crush injuries (n=2), and after intramedullary nailing of a femur fracture. Four patients developed CS of the ipsilateral leg, of whom two also had CS of the ipsilateral foot. Three patients had bilateral CS of the thighs, two of whom also had bilateral CS of the legs. One patient had acute CS of the forearm. Decision for fasciotomy of the thigh was based on clinical evidence for tense compartments with elevated compartment pressures, increased need for analgesia, and pain with passive range of motion. All wounds were treated with delayed primary closure. The mean follow-up was one year (range 3 to 36 months).

Results: Associated morbidities included rhabdomyolysis in four patients, of which one progressed to acute renal failure. Three patients developed deep vein thrombosis. At fasciotomy, there was evidence for muscle necrosis in two patients. One patient had hematoma. One patient sustained an injury to the superficial femoral artery. The mean length of stay was 30 days (range 7 to 43 days). Upon discharge, five patients had intact neurovascular status. Two patients had a foot drop, one with bilateral, which did not resolve at three years' follow-up. All patients underwent multiple debridements, ranging from 2 to 39 including definitive wound closure.

Conclusion: Emergent fasciotomy and release of affected compartments minimize morbidity and future complications.

Key words: Compartment syndromes/diagnosis/surgery; fascia/surgery; thigh/surgery.

Amaç: Bu çalışmada uyluk kompartman sendromu (KS) ile ilgili deneyimlerimizi gözden geçirmek ve tedavisi için kılavuz oluşturmak amaçlandı.

Hastalar ve yöntemler: Çalışmaya, 10 uyluğunda KS gelişen yedi erkek hasta (ort. yaş 26; dağılım 17-47) alındı. Yaralanma nedenleri motorlu taşıt kazası, spor yaralanması (n=2), künt travma, ezilme (n=2) ve intramedüller çivilemeden sonra gelişen femur kırığıydı. Dört hastada aynı taraf bacakta KS vardı; bunların ikisinde aynı taraf ayak da etkilenmişti. Üç hastada uyluk KS'si iki taraflıydı; bunların ikisinde ayaklarda da iki taraflı KS vardı. Bir hastada kolda da akut KS saptandı. Uyluk fasyotomisi kararı, artmış kompartman basıncıyla birlikte gergin kompartman gösteren klinik bulgulara, yüksek derecede analjezi ihtiyacına ve pasif hareket açıklığında ağrı varlığına dayanılarak verildi. Yaraların primer kapatılması daha sonra yapıldı. Ortalama takip süresi bir yıl (dağılım 3-36 ay) idi.

Bulgular: Eşlik eden morbidite olarak dört hastada rhabdomyoliz saptandı; bunların birinde akut renal yetmezlik gelişti. Üç hastada derin ven trombozu görüldü. Fasyotomide, iki hastada kas nekrozu bulgularına rastlandı. Bir hastada hematoma vardı. Bir hastada yüzeysel femoral arter yaralanması görüldü. Ortalama yatış süresi 30 gün (dağılım 7-43 gün) bulundu. Taburculuk sırasında beş hastada nörovasküler sorun yoktu; iki hastada ise, birinde iki taraflı olmak üzere düşük ayak gelişti. Bu durum üç yıllık takip sırasında da düzelmedi. Tüm hastalarda, primer yara kapanması da dahil birden fazla debridman (dağılım 2 ile 39) uygulandı.

Sonuç: Acil fasyotomi ve etkilenen kompartmanların gevşetilmesi morbidite ve sonraki komplikasyonları önemli derecede azaltmaktadır.

Anahtar sözcükler: Kompartman sendromu/tanı/cerrahi; fasya/cerrahi; uyluk/cerrahi.

• Received: October 19, 2006 Accepted: February 15, 2007

• Correspondence: Nirmal Tejwani, MD. 550 First Avenue, NBV 21W37, New York, NY, 10010 USA Tel: +00-1-212-263-7198 Fax: +00-1-212-263-8217 e-mail: nirmal.tejwani@med.nyu.edu

Since the thigh has greater capacity for expansion before its contents become restricted, it is an unusual site for compartment syndrome.^[1-4] A review of the available English literature demonstrated that acute compartment syndrome of the thigh is limited to only a few series and several case reports.^[1,2,5-10] Compartment syndrome of the thigh occurs in association with femur fractures, strenuous exercise, blunt trauma, vascular injury, compression of the thigh, prolonged positioning, total joint arthroplasty, and the use of military anti-shock trousers.^[1-5,7,11-13] We report our experience with 10 thigh compartment syndromes in seven patients and present our guidelines for the treatment of acute compartment syndrome of the thigh. The purpose of our clinical series was to further the understanding of the diagnosis and treatment of acute compartment syndrome of the thigh.

PATIENTS AND METHODS

Bellevue Hospital Center is a regional trauma center that receives patients from all five boroughs of New York City. During the period from March 2000 to July 2003, 10 cases of thigh compartment syndrome in seven patients were diagnosed and treated. All patients were males with an age range of 17 to 47 years (mean age 26 years).

The mechanisms of injury included trauma sustained during a motor vehicle accident, sports injuries (n=2), blunt trauma, crush injuries (n=2), and after intramedullary nailing of a femur fracture (Table I). Associated injuries included superior and inferior pubic rami fractures, an ankle fracture, a

facial fracture, and a tear of the lateral collateral ligament of the knee. Compartment syndromes in the buttocks, legs, and feet were also noted. Four patients developed compartment syndrome of the ipsilateral leg, of whom two also developed compartment syndrome of the ipsilateral foot. Three patients had bilateral compartment syndrome of the thighs and two of these had bilateral compartment syndrome of the legs, as well. One patient developed acute compartment syndrome of the forearm.

Diagnosis

The diagnostic criteria for compartment syndrome included clinical evaluation and pressure monitoring. Upon evaluation, swelling and the tense appearance of the skin of the thighs were noted. The basic metabolic panels and creatine phosphokinase values were followed (Table II).

All patients initially evaluated at our institution were able to cooperate with the primary examination in the emergency ward. All patients had increasing pain and swelling in the affected thigh. Painful passive range of motion of the knee was noted in two patients. Two patients had decreased sensation in the affected leg, probably due to sciatic nerve palsy in the thigh or peroneal nerve palsy in the leg. Both of these patients had compartment syndrome of both the thigh and the leg. All patients had palpable distal pulses. Pressure measurements were performed once in the anterior, posterior, and medial compartments of the thigh. Fasciotomies were performed in patients in whom measured pressures were greater than 40 mmHg and less than 30 mmHg difference from the diastolic blood pressure.

TABLE I

Injuries sustained by patients with thigh compartment syndrome

| Case | Age (years) | Mechanism of injury | Injury | Side of thigh compartment syndrome | Associated compartment syndromes |
|------|-------------|--------------------------------|---|------------------------------------|--|
| 1 | 47 | Motor vehicle accident | Femur fracture | Right | Right forearm |
| 2 | 34 | Building collapse | Crush injury | Left | Left leg, left foot |
| 3 | 17 | Motor vehicle accident | Postoperative femur fracture after intramedullary nailing | Left | Left leg |
| 4 | 23 | Extreme exertion | Extreme exertion | Bilateral | None |
| 5 | 38 | Building collapse | Crush injury | Bilateral | Bilateral buttocks Bilateral legs, bilateral feet |
| 6 | 18 | Blunt trauma during rugby play | Blunt trauma | Left | Left leg |
| 7 | 23 | Extreme exertion | Extreme exertion | Bilateral | None |

TABLE II

Creatine phosphokinase levels (U/l)

| Case | Admission | Peak | Last | DVT |
|------|-----------|--------|-------|-----|
| 1 | 414 | 1,639 | 65 | - |
| 2 | 61,100 | 66,800 | 146 | + |
| 3 | 505 | 8,860 | 4,030 | + |
| 4 | 735 | 851 | 113 | - |
| 5 | 2,476 | 30,000 | 66 | - |
| 6 | 1,587 | 1,587 | 346 | + |
| 7 | 58,700 | 58,700 | 686 | - |

DVT: Deep vein thrombosis

Treatment

Emergent fasciotomies were performed in all patients in whom acute compartment syndrome was diagnosed. Decision for fasciotomy of the thigh was based on clinical evidence for tense compartments, increased need for analgesia, and pain with passive range of motion. Of these criteria, the decision for fasciotomy was mainly based on the presence of a tense thigh with elevated compartment pressures. In all cases, fasciotomies of the anterior, posterior, and medial compartments of the thigh were performed using two incisions. The first incision was made laterally and dissection was performed to the intermuscular septum through which the anterior and posterior compartments were released. The second incision was made medially to decompress the medial compartment. All wounds were treated with delayed primary closure. The necessity for further irrigation and debridement as well as skin grafting was based upon clinical assessment of the wound. Three cases were complicated by rhabdomyolysis, of which one progressed to acute renal failure. Patients with rhabdomyolysis were treated with vigorous intravenous hydration, usually with normal saline. The patient with acute

renal failure was treated with aggressive intravenous hydration with alkalinized fluids for a target urine pH of greater than 7.

RESULTS

There were no mortalities. Associated morbidities included rhabdomyolysis in four patients, including one with acute renal failure. Three patients developed deep vein thrombosis. Of these, two patients had deep vein thrombosis in the ipsilateral and contralateral legs, respectively.

At initial fasciotomy, there was evidence for muscle necrosis in two patients. One patient had hematoma. One patient sustained an injury to the superficial femoral artery which was repaired by vascular surgeons.

All patients underwent multiple debridements, ranging from 2 to 39 including definitive wound closure (Table III). One patient (Case no. 6) initially had release of only the anterior and medial compartments because the posterior compartment showed no evidence for compartment syndrome. However, the next day of surgery, he complained of increased pain in the ipsilateral leg and posterior thigh and was found to have a tense leg and posterior thigh. Pressures measured in the operating room were elevated and fasciotomy of the leg and the posterior compartment of the thigh were performed. Upon release of the posterior compartment, a hematoma was found.

The average length of stay ranged from 7 to 43 days, with an average of 30 days. Upon discharge, five patients were noted to have intact neurovascular status. Two patients had a foot drop, one with bilateral, which did not resolve at three years' follow-up. In both, compartment syndrome developed in the ipsilateral thigh and leg so it could be attributed to sciatic nerve palsy in the thigh or peroneal nerve

TABLE III

Surgical data of the patients

| Case | Vascular injuries | Muscle necrosis | Hematoma | Skin graft | Total no. of surgeries |
|------|-------------------|-----------------|----------|------------|------------------------|
| 1 | - | - | - | + | 2 |
| 2 | - | + | + | + | 6 |
| 3 | + | - | - | - | 2 |
| 4 | - | - | - | - | 2 |
| 5 | - | + | - | + | 39 |
| 6 | - | - | + | - | 6 |
| 7 | - | - | - | - | 2 |

palsy in the leg. One patient had decreased range of motion of the knee secondary to stiffness that developed as a result of fasciotomies in the entire lower extremity. His range of motion was approximately full extension to flexion of 60 degrees. After manipulation under anesthesia at three months, the patient regained flexion of his knee to approximately 90 degrees. The final follow-up averaged one year (range 3 to 36 months). Those having foot drop showed no improvement in neurological function.

DISCUSSION

Acute compartment syndrome of the thigh is a rare occurrence. Unlike the forearm or lower leg, the thigh has much larger compartments that allow for greater increases in volume before the compartment pressures become critical.^[3,11]

The thigh has three compartments—anterior, medial, and lateral (Fig. 1). The septa of the anterior compartment are the most rigid, followed by the septa surrounding the lateral compartment. The septa of the medial compartment are the least rigid.^[3] According to Kahan et al.,^[11] the strong septa and positional vulnerability of the anterior compartment of the thigh may account for a higher susceptibility to acute compartment syndrome.

Data regarding the incidence of compartment syndrome in the thigh are sparse. Thigh compartment syndrome has been associated with strenuous exercise, femur fractures, and contusions.^[1,3,5,11-13] In the largest series to date reported by Mithofer et al.,^[7] 15 of 29 thigh compartment syndromes, and in another series of 21 thigh compartment syndromes reported by Schwartz et al.,^[2] 10 were associated with femoral fractures. In our series, only one compartment syndrome was associated with an acute femur fracture.

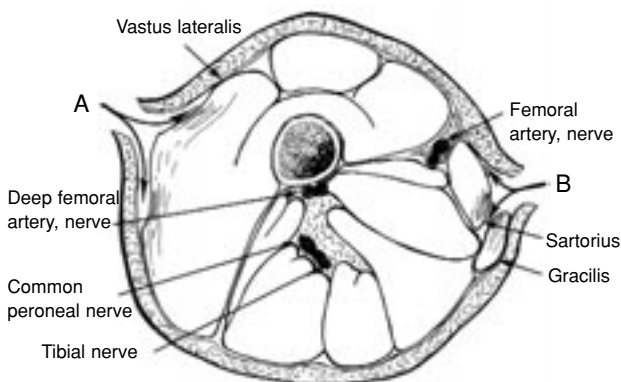


Fig. 1. Cross-sectional view of compartments of the thigh (With permission from Dr. Eric Kubiak).

It is important to diagnose compartment syndrome early for prevention of further muscular and neurologic injury. A sensory deficit is a useful sign in diagnosing compartment syndrome the leg or the forearm, because the deficit may help isolate the particular compartment involved.^[8] However, since the nerves of the thigh are not confined to one compartment, a sensory deficit may not be a reliable marker. Classically, the patients present with tense compartments and pain out of proportion to the injury. Pain may also exist on passive range of motion of the knee, but this finding can be confounded by a concomitant femur fracture. The presence of distal pulses does not eliminate a possible diagnosis of compartment syndrome since compartment pressures are rarely high enough to occlude a major artery. Schwartz et al.^[2] also recommended repeated clinical examinations when the patient is awake and able to cooperate. Swelling and tenderness may be the only clinical signs. Indeed, Mithofer et al.^[7] reported that the most reliable clinical finding in the awake patient was a tensely swollen, excessively painful thigh.

When the clinical examination is equivocal because the patient is unable to cooperate or has multiple injuries, the use of adjunctive diagnostic techniques such as compartment pressure measurement is recommended.^[6,8,14] However, rather than establishing a pressure threshold, continuous monitoring to observe the trend of tissue pressure measurements may be more valuable.^[8,14-16] Therefore, an elevated compartment pressure alone may not be the definitive indicator of a compartment syndrome. Allen et al.^[15] demonstrated that a compartment syndrome might be transient. In such a case, the compartment pressures rise but do not remain elevated, with no residual effect. Allen et al.^[15] suggested six hours as the period before which permanent damage could occur from elevated compartment pressures. Our institutional protocol is to perform one set of compartment pressure measurements if the clinical evidence, such as a tense thigh, is suggestive of acute compartment syndrome. Repeated pressure measurements are a consideration if the clinical criteria are borderline.

Thigh compartment syndrome is a unique entity. A tense compartment, pain with passive range of motion, and increasing pain are important clinical signs in the thigh as well as elsewhere in the extremities for compartment syndrome. However, because of the increased capacity of the thigh versus the leg or

the forearm, there is the potential to perform repeat monitoring before surgery is absolutely indicated.

Measuring compartment pressures is useful in deciding which patients require operative intervention. Whitesides et al.^[14] reported on three cases in which the clinical signs of a compartment syndrome were present (i.e. lack of pulses, pain on passive range of motion, and decreased sensation) in the absence of elevated compartment pressures. All three patients recovered from their respective deficits without undergoing a fasciotomy. Mubarak et al.^[8] reported that measuring compartment pressures also helped distinguish neurapraxia resulting from direct trauma from that resulting from compartment syndrome. In their series, all patients who had neurapraxia attributable to direct trauma, as verified by normal compartment pressures, were spared a fasciotomy and recovered fully within 12 weeks. All patients diagnosed as having neurapraxia resulting from compartment syndrome underwent immediate fasciotomies and recovered fully within the first week.

Fasciotomy is indicated when clinical signs of compartment syndrome are present with increased compartment pressures.^[6] A standard threshold pressure has not been established, but values above 40 mmHg should be considered suspicious.^[6,8,12,15,17] Diastolic blood pressure can also be used as a reference, with concerning compartment pressure levels occurring within 10 to 30 mmHg of the diastolic blood pressure. When compartment syndrome is suspected, emergent fasciotomy is critical. Irreversible injury to muscles and nerves has been shown to begin after five to six hours of ischemia in animal studies.^[14]

The patient's history, physical examination, and compartment pressures may support the decision to operate in the case of a suspected compartment syndrome. Although full recovery from fasciotomies for thigh compartment syndrome has been reported, these surgical interventions are not without complications.^[1,11,13,15,16] Winternitz et al.^[12] reported greater peak torques of the involved versus uninvolved thigh muscles at 18 months upon postoperative muscle function testing. After fasciotomy, the sequelae include decreased flexion, decreased sensation, and decreased motor strength.^[2] Certainly, if there is an underlying femur fracture, many of the sequelae can be due to that. However, Mithofer et al.^[7] reported that patients with isolated thigh compartment syndrome had a lower incidence of complications,

including myonecrosis and need for skin graft, than those with associated injuries. They suggested that the thigh musculature was able to tolerate greater compartment pressures than other areas of the body.

A review of the literature also showed a variable number of compartments upon which a fasciotomy was performed. Several authors performed fasciotomy of only a single compartment with no adverse results reported in the remaining compartments.^[3,4,12] However, we recommend decompression of all clinically suspected compartments. As seen in one patient (Case no. 6), compartment syndrome can develop in another compartment of thigh even after fasciotomy of the other two.

Reviewing our experience with thigh compartment syndrome and the cases documented in the literature allows us to make several conclusions regarding its management.

Thigh compartment syndrome can be due to diverse etiologies, including fracture, crush injury, blunt trauma, exertion, and after intramedullary nailing of the femur. Of note, a case of acute compartment syndrome of the thigh in our series occurred after intramedullary nailing of the femur. Schwartz et al.^[2] reported approximately one percent incidence of thigh compartment syndrome after closed intramedullary nailing of the femur, hypothesizing that this was due to a combination of a decreased volume secondary to reduction of the fracture and increased pressure secondary to hemorrhage and edema.

Clinical examination, especially a tense and painful thigh, can further aid in the diagnosis. Lack of pulses usually indicates a vascular injury and should not be used to diagnose compartment syndrome. Measurement of compartment pressures assists in confirming the diagnosis. Absolute compartment pressures of greater than 40 mmHg or within 30 mmHg from the diastolic blood pressure are recommended thresholds for fasciotomy. These are the compartment pressures that we use based upon recommendations in the literature. An associated compartment syndrome in the same extremity should also be looked for, especially with crush injuries.

From the time of admission, hematocrit, electrolytes, and creatine phosphokinase levels should be serially monitored. In our series, four of seven patients had rhabdomyolysis secondary to com-

partment syndrome, and one progressed to acute renal failure. The need for renal dialysis and medical management should be kept in mind.

The use of prophylactic anticoagulation is recommended since nearly half of the patients in this series developed deep vein thrombosis. Fasciotomies were performed immediately after diagnoses, with decompression of all three compartments. Wounds were left open for future debridements with V.A.C. dressings (KCI, San Antonio, TX). Multiple subsequent procedures are needed to clean and close the wounds.

In conclusion, we have developed institutional guidelines based upon our experience with acute compartment syndrome of the thigh for its diagnosis and treatment. First, the mechanisms of injury that can lead to acute compartment syndrome of the thigh must be recognized. Second, upon initial evaluation, the presence or absence of the signs and symptoms of acute compartment syndrome must be ascertained. Third, serial blood urea nitrogen, creatinine, and creatine phosphokinase measurements should be followed. Although acute compartment syndrome of the thigh is primarily a clinical diagnosis, it is important to measure compartment pressures. This should be performed in a sterile fashion, preferably in the operating room, so that fasciotomy of the thigh can be performed without delay. Indeed, the clinical findings should dictate the need for surgery and the compartment pressures should be used as confirmation. Finally, wounds should be left open to allow for future irrigation and debridements before secondary closure and coverage. Patients should return to the operating room every 48 to 72 hours for irrigation and debridement followed by closure or coverage. Use of the V.A.C. dressing is routine at our institution to reduce edema and aid in wound closure.

The limitations of our study include the small series of patients, its retrospective nature, and the varying type of initiating factors for the compartment syndrome. Future studies could include a prospective design on the predictive value of the clinical criteria versus laboratory values and compartment pressure measurements in diagnosing acute compartment syndrome of the thigh.

REFERENCES

1. Kahan JS, McClellan RT, Burton DS. Acute bilateral compartment syndrome of the thigh induced by exercise. A case report. *J Bone Joint Surg [Am]* 1994;76:1068-71.
2. Schwartz JT Jr, Brumback RJ, Lakatos R, Poka A, Bathon GH, Burgess AR. Acute compartment syndrome of the thigh. A spectrum of injury. *J Bone Joint Surg [Am]* 1989;71:392-400.
3. Tarlow SD, Achterman CA, Hayhurst J, Ovadia DN. Acute compartment syndrome in the thigh complicating fracture of the femur. A report of three cases. *J Bone Joint Surg [Am]* 1986;68:1439-43.
4. Viegas SF, Rimoldi R, Scarborough M, Ballantyne GM. Acute compartment syndrome in the thigh. A case report and a review of the literature. *Clin Orthop Relat Res* 1988(234):232-4.
5. Kuklo TR, Tis JE, Moores LK, Schaefer RA. Fatal rhabdomyolysis with bilateral gluteal, thigh, and leg compartment syndrome after the Army Physical Fitness Test. A case report. *Am J Sports Med* 2000;28:112-6.
6. Matsen FA 3rd, Winquist RA, Krugmire RB Jr. Diagnosis and management of compartmental syndromes. *J Bone Joint Surg [Am]* 1980;62:286-91.
7. Mithofer K, Lhowe DW, Vrahas MS, Altman DT, Altman GT. Clinical spectrum of acute compartment syndrome of the thigh and its relation to associated injuries. *Clin Orthop Relat Res* 2004;(425):223-9.
8. Mubarak SJ, Owen CA, Hargens AR, Garetto LP, Akeson WH. Acute compartment syndromes: diagnosis and treatment with the aid of the wick catheter. *J Bone Joint Surg [Am]* 1978;60:1091-5.
9. Nadeem RD, Clift BA, Martindale JP, Hadden WA, Ritchie IK. Acute compartment syndrome of the thigh after joint replacement with anticoagulation. *J Bone Joint Surg [Br]* 1998;80:866-8.
10. Rooser B, Bengtson S, Hagglund G. Acute compartment syndrome from anterior thigh muscle contusion: a report of eight cases. *J Orthop Trauma* 1991;5:57-9.
11. Nau T, Menth-Chiari WA, Seitz H, Vecsei V. Acute compartment syndrome of the thigh associated with exercise. *Am J Sports Med* 2000;28:120-2.
12. Winternitz WA Jr, Metheny JA, Wear LC. Acute compartment syndrome of the thigh in sports-related injuries not associated with femoral fractures. *Am J Sports Med* 1992;20:476-7.
13. Wise JJ, Fortin PT. Bilateral, exercise-induced thigh compartment syndrome diagnosed as exertional rhabdomyolysis. A case report and review of the literature. *Am J Sports Med* 1997;25:126-9.
14. Whitesides TE, Haney TC, Morimoto K, Harada H. Tissue pressure measurements as a determinant for the need of fasciotomy. *Clin Orthop Relat Res* 1975;(113): 43-51.
15. Allen MJ, Stirling AJ, Crawshaw CV, Barnes MR. Intracompartmental pressure monitoring of leg injuries. An aid to management. *J Bone Joint Surg [Br]* 1985;67:53-7.
16. Machold W, Muellner T, Kwasny O. Is the return to high-level athletics possible after fasciotomy for a compartment syndrome of the thigh? A case report. *Am J Sports Med* 2000;28:407-10.
17. Gelberman RH, Szabo RM, Williamson RV, Hargens AR, Yaru NC, Minteer-Convery MA. Tissue pressure threshold for peripheral nerve viability. *Clin Orthop Relat Res* 1983;(178):285-91.