



Early complications encountered using a self-lengthening intramedullary nail for the correction of limb length inequality

Bacak uzunluğu eşitsizliğini düzeltmek için kendiliğinden uzayan intramedüller çivi uygulamasının erken dönem sonuçları

Erik N. Kubiak, M.D., Eric Strauss, M.D., Alfred Grant, M.D., David Feldman, M.D.,
Kenneth A. Egol, M.D.

Department of Orthopedic Surgery, The New York University Hospital for Joint Diseases

Objectives: We evaluated early complications of self-lengthening intramedullary nails during limb lengthening in patients with post-traumatic or growth-related limb length deficiencies.

Patients and methods: A retrospective review was undertaken of all patients who underwent femoral lengthening using the Internal Skeletal Distractor (ISKD Orthofix, McKinney, Texas) device beginning September 2003 at our tertiary care center. Data from the radiographic and clinical records of 11 limbs in nine patients (mean age 24 years; range 16 to 33 years) were derived. Complications were recorded and compared to the demographic data.

Results: Preoperative leg length discrepancies averaged 3.7 cm (range 2.5 to 4.8 cm) and postoperative lengthening averaged 3.1 cm (range 2.3 to 4.4 cm). The mean follow-up was 16 months (range 12 to 26 months). The nails were removed after a mean of 11.5 months (range 8 to 16 months). Complications were encountered with eight ISKD nails (72.7%). Of these, seven complications necessitated the patients returning to the operating room. The average time to reoperation was 21 days (range 4 to 37 days). Two patients had two complications per ISKD. In all, there were four nails which failed to advance and required re-osteotomy, three premature consolidations which required osteoclasts, and one runaway nail advancement of 3.0 mm/day compared to the target lengthening rate of 0.8-1.0 mm/day.

Conclusion: We believe that binding at the osteotomy site was responsible for failure of nail advancement in patients in whom lengthening failed. In the light of the high complication rate, surgeons' vigilance during the postoperative period is crucial.

Key words: Bone nails; equipment design; femur/surgery; leg length inequality/surgery; osteogenesis, distraction/instrumentation; tibia/surgery.

Amaç: Travmaya bağlı ya da büyüme ile ilgili bacak uzunluğu eşitsizliği olan hastalarda kendiliğinden uzayan intramedüller çivi ile ekstremitte uzatma sırasında karşılaşılan erken dönem komplikasyonlar değerlendirildi.

Hastalar ve yöntemler: 2003 yılı Eylül'ünden başlayarak, üçüncü basamak merkezimizde İnternal İskelet Distraktörü (ISKD Orthofix, McKinney, Teksas, ABD) ile femoral uzatma işlemi yapılan tüm hastalar geriye dönük olarak değerlendirildi. Bunlar arasında dokuz hastanın (ort. yaş 24; dağılım 16-33) 11 ekstremitesine ait radyografik ve klinik kayıtlar incelendi. Komplikasyonlar kaydedilerek demografik verilerle karşılaştırıldı.

Bulgular: Ameliyat öncesi ortalama bacak uzunluğu eşitsizliği 3.7 cm (dağılım 2.5-4.8 cm) iken ameliyat sonrası sağlanan uzatma ortalama 3.1 cm (dağılım 2.3-4.4 cm) bulundu. Ortalama takip süresi 16 aydı (dağılım 12-26 ay). Distraksiyon çivileri ortalama 11.5 ay sonra çıkarıldı (dağılım 8-16 ay). Sekiz çivide komplikasyon gelişti (%72.7). Bunların yedisinde ortalama 21 günde (dağılım 4-37 gün) hastalara yeniden girişim gerekti. İki hastada çivi başına iki komplikasyon görüldü. Komplikasyon olarak ilerleme başarısızlığı gösteren dört çivide yeniden osteotomi gerekti; üç ayaktaki erken konsolidasyon için osteoklastis uygulandı; bir çivide ise hedeflenen 0.8-1.0 mm/gün ilerleme hızına karşın 3.0 mm/gün ilerleme hızıyla aşırı ilerleme görüldü.

Sonuç: Uzatmanın başarısız olduğu hastalardaki çivi ilerlemedeki başarısızlıkta osteotomi alanında oluşan eğilmenin rol oynadığını düşünüyoruz. Yüksek komplikasyon oranı göz önüne alındığında, ameliyat sonrası dönemde yakın takibin çok önemli olduğu görülmektedir.

Anahtar sözcükler: Kemik çivisi; ekipman tasarımı; femur/cerrahi; bacak uzunluğu eşitsizliği/cerrahi; osteogenez, distraksiyon/enstrümantasyon; tibia/cerrahi.

• Received: October 19, 2006 Accepted: December 30, 2006

• Correspondence: Kenneth A Egol, MD. NYU-Hospital for Joint Diseases, Department of Orthopaedic Surgery, 301 East 17th Street, New York, NY, 10003 USA. Tel: +00-1-212-598-6000 Fax: +00-1-212-598-6015 e-mail: egolk01@nyumc.org

Limb length inequality in bipedal animals like humans is a relatively common finding with a reported incidence of 2-4/100,000.^[1-3] There are multiple etiologies for the development of limb length inequality, which include lower extremity fracture, infection, vascular trauma, tumor, Legg-Calve-Perthes disease, cerebral palsy, congenital malformation, and many more. Leg length inequalities have been linked to the development of low back pain^[3] and gait abnormalities.

Mild leg length inequalities less than 5 cm are generally treated with external prosthetic devices like shoes lifts and heel wedges. Surgical correction of more severe leg length inequalities above 5 to 6 cm^[4] prior to the advent of successful distraction osteogenesis ("callus distraction," callotaxis, chondrodiastasis) involved arresting the growth of the longer limb or shortening the longer limb if the patient was skeletally mature.

Codivilla at the beginning of the twentieth century is credited with the initial attempts at correcting leg length by distraction osteogenesis. He was followed later by Putti and Abbott in the 1920's who confirmed the viability of distraction osteogenesis. After World War II, Andersen, Allan, and Ilizarov perfected the technique of distraction osteogenesis and clarified its biological principles.^[5] Today, distraction osteogenesis is the preferred technique for the correction of limb length inequalities in excess of 5-6 cm.

The technique involves the stabilization of the limb to be lengthened with an external fixator followed by a metaphyseal corticotomy. After a consolidation period of 7-10 days, the limb is gradually lengthened 1 mm/day until the desired length correction has been achieved. The lengthening period is followed by a maturation period which is equal to two times the lengthening period.^[6-8] During this time, the external fixator must remain in place. Distraction osteogenesis performed in this manner has a complication rate of 13-100% depending on the author and the series.^[9-11] Most of the complications involve the external fixator, with pin tract infections being the most common.^[12,13] Recently, attempts have been made to reduce the external fixator time by using locked intramedullary nails to stabilize the bone during the maturation period.^[14-16] The Internal Skeletal Distractor (ISKD nail, Orthofix McKinney, Texas) (Fig. 1) is a self-lengthening intramedullary nail which is designed to completely

eliminate the use of external fixator, having the ability to perform the lengthening and the maturation period stabilization.^[17-19]

We describe the complications encountered using a self-lengthening intramedullary nail (ISKD) during limb lengthening in patients with post-traumatic or growth-related limb length deficiencies.

PATIENTS AND METHODS

A retrospective review was undertaken of all patients who underwent femoral lengthening using the ISKD device beginning September 2003 at our tertiary care center. The ISKD procedures were performed in accordance with the manufacturer's recommendations. All intramedullary devices were placed in an antegrade fashion through a piriformis starting point after the creation of the diaphyseal osteotomy. Osteotomies were created by making multiple drill holes in the diaphysis of the femur with a 3.5-mm drill. The drill holes were connected using an osteotome, and finally the completion of the osteotomy was confirmed to be complete with biplanar stress fluoroscopy. All limb lengthening



Fig. 1. Internal skeletal distractor (ISKD) implants for the femur and tibia.

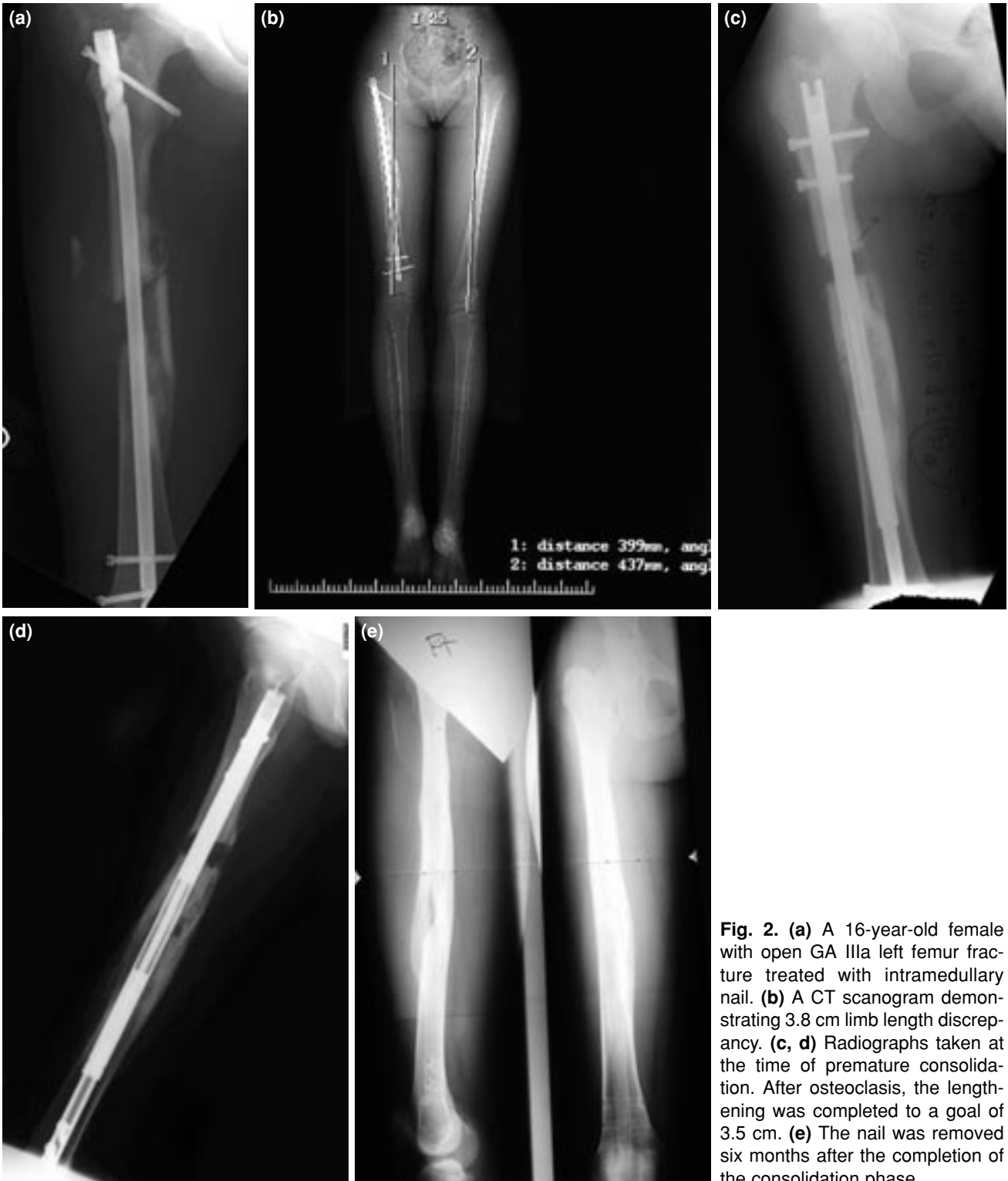

Fig. 2. (a) A 16-year-old female with open GA IIIa left femur fracture treated with intramedullary nail. (b) A CT scanogram demonstrating 3.8 cm limb length discrepancy. (c, d) Radiographs taken at the time of premature consolidation. After osteoclasis, the lengthening was completed to a goal of 3.5 cm. (e) The nail was removed six months after the completion of the consolidation phase.

procedures were performed by senior surgeons (AG, DF, KE) having extensive experience with limb lengthening techniques. Patients were not discharged from the hospital until they had been trained in the use of the ISKD monitor (an elec-

tromagnetic nail advancement detector device). Prior to discharge, all patients were crutched and trained by a licensed physical therapist and were compliant with toe-touch weight bearing precautions on the operative limb.

TABLE I
Compilation of complications and solutions

Case	Age	M/F	Etiology	Index procedure	Complication	Solution
1 (B)	27	M	Congenital	ISKD	Jammed nail Premature consolidation	Osteoclasia, iliotibial band release
2	22	F	Congenital	ISKD		
3	25	M	Congenital	ISKD	Jammed nail	Manipulation under anesthesia, osteoclasia, nail exchange
4	33	M	Femur fracture	ISKD	Premature consolidation	Osteoclasia, iliotibial band release, biceps femoris release
5	23	M	Femur fracture	ISKD		
6	16	F	Open femur fracture	ISKD	Premature consolidation	Manipulation under anesthesia, osteoclasia
7	18	F	Femur fracture	ISKD, iliotibial band release		
8 (B)	16	M	Congenital	ISKD	Jammed nail Runaway nail	Manipulation under anesthesia, osteoclasia
9	16	M	Congenital	ISKD	Premature consolidation	Osteoclasia, iliotibial band release

ISKD: Internal Skeletal Distractor; B: Bilateral.

Patients were seen in the senior surgeons' private offices or in the hospital inpatient wards at one week postoperatively, at which time limb lengthening was begun. During the lengthening period, patients were seen at one-week intervals to record and confirm appropriate progression of lengthening. Progression of lengthening was determined by the ISKD monitor, whose values were then correlated with biplanar radiographs. Figure 2 demonstrates the evaluation of a patient with a post-traumatic limb length discrepancy that was treated with lengthening using the ISKD implant.

Data from the radiographic and clinical records of nine patients with 11 limbs, who underwent placement of an ISKD nail for femoral lengthening was abstracted for this study.

RESULTS

The mean age of the patients at the time of surgery was 24 years (range 16 to 33 years). Preoperative leg length discrepancies averaged 3.7 cm (range 2.5 to 4.8 cm) and postoperative lengthening averaged 3.1 cm (range 2.3 to 4.4 cm). The mean follow-up was 16 months (range 12 to 26 months). The nails were removed after a mean of 11.5 months (range 8 to 16 months). Complications were encountered with eight ISKD nails, which included failure of

three nails to advance despite manual manipulation of the affected legs, premature consolidation in four legs, and runaway of one nail (Table I). Of these, seven complications (6 patients) necessitated a return to the operating room. The average time to reoperation was 21 days (range 4 to 37 days). Two patients had two complications: one returned to the operating room twice, at 4 days for repeat osteotomy and at 19 days from the index procedure for iliotibial band release and osteoclasia (Case 1). The other returned to the operating room on postoperative day 5 for manipulation under anesthesia and reosteotomy (Case 8). After the initial osteotomy, both had normal nail advancement (0.8-1.0 mm/day) for the first week; however, one week later, the latter patient's ISKD showed a lengthening rate in excess of normal (the "runaway" nail), completing the planned advancement with a rate greater than 3 mm/day. Two other patients (Cases 3 and 6) required manipulations under anesthesia followed by reosteotomy at postoperative days 5 and 7, respectively. In one of these (Case 3), the implant was replaced due to malfunction, after which the remaining postoperative course was uncomplicated. The remaining two patients (Cases 4 and 9) experienced premature consolidation on postoperative days 34 and 37 and underwent osteoclasia and iliotibial band release; subsequently the

preoperative goals for lengthening were achieved in both patients without further complications.

DISCUSSION

Despite the high degree of experience on the part of the operating surgeons with limb lengthening using external fixators and external fixators over locked intramedullary nails, a very high complication rate of 72.7% was observed in our initial series of nine patients with 11 ISKD lengthening procedures. Six of the patients had to return to the operating theater. All patients who returned to the operating room required re-opening of the osteotomy site and osteoclasts after manipulation under anesthesia, which consisted of manually rotating the femur to advance the failed nail. Two patients with late consolidation underwent release of the iliotibial band. One patient required replacement of the nail because the gear in the nail had jammed. These findings are dissimilar to those of Hankemeier et al.^[19] who reported no complications in an initial series of four patients treated with an ISKD. Our complication rate does not compare favorably to the rates reported for Ilizarov or Wagner distraction osteogenesis^[6,9,20] if minor complications like pin tract infections are not considered, which seldom require return to the operating theater.

We believe that, in these five patients, two complications could have been avoided with modification of the surgical technique because they were intrinsic to the nail and demands placed upon the nail. First, the three early complications which required osteoclasts and replacement of the nail were likely to be the result of anterior cortical impingement. We are convinced that this was the case because all osteotomies were confirmed to be complete by stress fluoroscopy prior to placement of the nails. This impingement occurs as a result of a straight rod being placed in a curved bone (Fig. 3). The rod straightens the femur, turning a uniplanar osteotomy to a biplanar osteotomy with high contact stresses anteriorly if the surgeons do not pay particular attention to the lateral radiographs, suggesting a distraction after osteotomy prior to distal locking of the nail. Removal of a wedge of bone (reosteotomy, in cases in which the patients returned to the operating room within the first week) or distraction of the osteotomy site that would ensure no cortical contact at the osteotomy site would correct this problem. Over-reaming may worsen the situation by allowing the bone to

toggle on the nail and increasing anterior impingement when the femur extends on the nail secondary to the pull of the quadriceps.

Second, the ISKD nail gear mechanism may not be capable of overcoming the compressive forces on the nail created by the soft tissue envelope around the femur. Brunner et al.^[21] demonstrated that distraction forces in the tibia reached 340 N over an intramedullary rod during lengthening, peaking at the end of transport. No literature data exist on the amount of distraction force needed for the femur and the end of distraction over a rod. Younger et al.^[22] demonstrated that distraction force as great as 673 N was encountered in children's femurs during lengthening with a circular fixator. This force may be greater in adults and even greater with an intramedullary device. Moreover, there is no information on the amount of force that an ISKD can develop without malfunctioning or the patient being unable to rotate the nail and on site of distraction osteogenesis to overcome that force. The ISKD nail may not be able to overcome the lateral tension

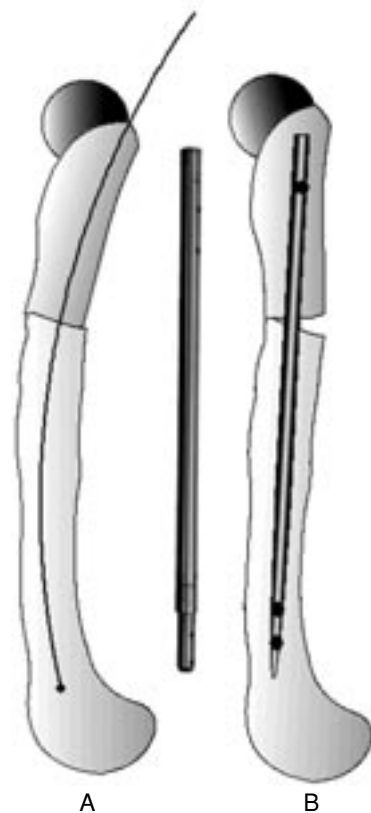


Fig. 3. Curvature mismatching between the nail and the femur can lead to anterior cortical impingement necessitating osteoclasts.

band of the iliotibial band as one reaches the extent of distraction. It may be necessary with this implant to perform prophylactic iliotibial band release in cases in which the distraction is planned for more than 4 centimeters; we added this procedure in our last case which was uncomplicated (Case 7).

In one patient, rapid lengthening of at least 3 mm/day was observed, which is in excess of the recommended 0.8-1 mm/day. Despite the presence of a "runaway" nail, the patient went on to uneventful consolidation. This stands as a reminder to the fact that the ISKD must be preset to the planned distraction amount at the time of placement because there is no way to arresting lengthening other than removal of the ISKD once implanted.

We recognize that this is our early experience with this device with a small number of cases. Yet, we believe that this case series provides some valuable insights into the use of this device. Additional work needs to be done to determine the amount of force that needs to be overcome by the device and the amount of force that the device can develop. This is a potentially good way to perform limb lengthening by a distracting fixator, which avoids the morbidity of prolonged external fixator application and the potential risk for infection of an intramedullary rod.

In conclusion, the high complication rate obtained from this series demands attention. We believe that, in those patients who experienced failure of lengthening, binding at the osteotomy site was responsible for insufficient nail advancement. Modification of the operative technique may be appropriate. In the light of this high complication rate, surgeons' vigilance during the postoperative period is crucial.

REFERENCES

- Guichet JM, Spivak JM, Trouilloud P, Grammont PM. Lower limb-length discrepancy. An epidemiologic study. *Clin Orthop Relat Res* 1991;(272):235-41.
- Soukka A, Alaranta H, Tallroth K, Heliovaara M. Leg-length inequality in people of working age. The association between mild inequality and low-back pain is questionable. *Spine* 1991;16:429-31.
- Brady RJ, Dean JB, Skinner TM, Gross MT. Limb length inequality: clinical implications for assessment and intervention. *J Orthop Sports Phys Ther* 2003;33:221-34.
- Stanitski CL. Limb lengthening for stature. *J Pediatr Orthop* 2004;24:593-4.
- Wiedemann M. Callus distraction: a new method? A historical review of limb lengthening. *Clin Orthop Relat Res* 1996;(327):291-304.
- Bonnard C, Favard L, Sollogoub I, Glorion B. Limb lengthening in children using the Ilizarov method. *Clin Orthop Relat Res* 1993;(293):83-8.
- Cech O. Prof. Ilizarov and his contribution to the challenge of limb lengthening. *Injury* 1993;24 Suppl 2:S2-8.
- Frankel VH, Gold S, Golyakhovsky V. The Ilizarov technique. *Bull Hosp Jt Dis Orthop Inst* 1988;48:17-27.
- Aaron AD, Eilert RE. Results of the Wagner and Ilizarov methods of limb-lengthening. *J Bone Joint Surg [Am]* 1996;78:20-9.
- Aldegheri R. Distraction osteogenesis for lengthening of the tibia in patients who have limb-length discrepancy or short stature. *J Bone Joint Surg [Am]* 1999;81:624-34.
- Bassett GS, Morris JR. The use of the Ilizarov technique in the correction of lower extremity deformities in children. *Orthopedics* 1997;20:623-7.
- Atar D, Lehman WB, Grant AD, Strongwater A, Frankel V, Golyakhovsky V. Treatment of complex limb deformities in children with the Ilizarov technique. *Orthopedics* 1991;14:961-7.
- Schlenzka D, Poussa M, Osterman K. Metaphyseal distraction for lower limb lengthening and correction of axial deformities. *J Pediatr Orthop* 1990;10:202-5.
- Kocaoglu M, Eralp L, Kilicoglu O, Burc H, Cakmak M. Complications encountered during lengthening over an intramedullary nail. *J Bone Joint Surg [Am]* 2004;86:2406-11.
- Lin CC, Huang SC, Liu TK, Chapman MW. Limb lengthening over an intramedullary nail. An animal study and clinical report. *Clin Orthop Relat Res* 1996;(330):208-16.
- Lee WH, Huang SC. Femoral lengthening: callotasis with Ilizarov external fixator alone and with intramedullary locking nail. *J Formos Med Assoc* 1997; 96:98-102.
- Cole JD, Justin D, Kasparis T, DeVlught D, Knobloch C. The intramedullary skeletal kinetic distractor (ISKD): first clinical results of a new intramedullary nail for lengthening of the femur and tibia. *Injury* 2001;32 Suppl 4:SD129-39.
- Hankemeier S, Gosling T, Pape HC, Wiebking U, Krettek C. Limb lengthening with the Intramedullary Skeletal Kinetic Distractor (ISKD). *Oper Orthop Traumatol* 2005;17:79-101.
- Hankemeier S, Pape HC, Gosling T, Hufner T, Richter M, Krettek C. Improved comfort in lower limb lengthening with the intramedullary skeletal kinetic distractor. Principles and preliminary clinical experiences. *Arch Orthop Trauma Surg* 2004;124:129-33.
- Aldegheri R. Femoral callotasis. *J Pediatr Orthop B* 1997;6:42-7.
- Brunner UH, Cordey J, Schweiberer L, Perren SM. Force required for bone segment transport in the treatment of large bone defects using medullary nail fixation. *Clin Orthop Relat Res* 1994;(301):147-55.
- Younger AS, Mackenzie WG, Morrison JB. Femoral forces during limb lengthening in children. *Clin Orthop Relat Res* 1994;(301):55-63.