



## Radiological evaluation of combined valgus extension osteotomy and tectoplasty for the treatment of Herring group C Perthes patients

Herring grup C Perthes hastalarının tedavisinde valgus ekstansiyon osteotomisi ile tektoplasti kombinasyonunun radyolojik değerlendirilmesi

Mehmet Emre Baki, M.D.,<sup>1</sup> Duygu Baki, M.D.,<sup>2</sup> Hafız Aydın, M.D.,<sup>3</sup>  
Servet Kerimoğlu, M.D.,<sup>3</sup> Celal Baki, M.D.<sup>3</sup>

Department of <sup>1</sup>Orthopedics and Traumatology, <sup>2</sup>Radiology, Erzurum Regional Training and Research Hospital, Erzurum, Turkey;  
<sup>3</sup>Department of Orthopedics and Traumatology, Medical Faculty of Karadeniz Technical University, Trabzon, Turkey

**Objectives:** In this study we evaluated the results of combined proximal femoral valgus extension osteotomy and tectoplasty in the treatment of Herring group C Perthes disease with hinge abduction.

**Patients and methods:** This study was carried out in 11 male patients who underwent combined proximal femoral valgus extension osteotomy and tectoplasty for hinge abduction related to Perthes disease between January 2002 and February 2009. All patients were assessed as group C according to the Herring lateral pillar classification. The mean age at the time of surgery was nine years and one month with an age range of six years to 11 years and two months. All patients had pain and hinge abduction preoperatively.

**Results:** The mean follow-up was 65 months (range 26 to 111 months). In the patients who received a proximal valgus extension osteotomy and tectoplasty, the postoperative femoral head containment was significantly increased radiographically. The postoperative femoral head containment was evaluated on radiographs which were taken one and three months after the surgery. After healing of the osteotomy, one-year and final control graphies were evaluated. We carried out a comprehensive evaluation of preoperative and postoperative radiographs that included measuring; subluxation ratio, femoral head coverage ratio, femoral head size ratio, Sharp's angle, CE (center-edge) angle, neck-shaft angle, caput index and acetabular depth index. Consequently there were significant radiographic healing and improvements from time of initial follow-up to final follow-up.

**Conclusion:** This study has shown that, in the short-term, combined valgus extension osteotomy and tectoplasty relived pain and corrected deformity in patients with hinge abduction. As growth continues the remodelling of hip joint is influenced in a positive way.

*Key words:* Perthes disease; osteotomy; treatment outcome.

**Amaç:** Bu çalışmada hinge abduksiyonuyla seyreden Herring grup C Perthes hastalığının tedavisinde proksimal femoral valgus ekstansiyon osteotomisi ile tektoplasti kombinasyonunun sonuçları değerlendirildi.

**Hastalar ve yöntemler:** Bu çalışma Ocak 2002 ile Şubat 2009 tarihleri arasında Perthes hastalığına bağlı hinge abduksiyonu için proksimal femoral valgus ekstansiyon osteotomisi ile tektoplasti kombinasyonu uygulanan 11 erkek hasta üzerinde yapıldı. Hastaların tamamı Herring lateral kolon sınıflandırmasına göre grup C olarak değerlendirildi. Ameliyat sırasındaki ortalama yaş dokuz yıl bir ay, yaş aralığı ise altı yıl-11 yıl iki ay şeklindeydi. Ameliyat öncesinde hastaların tamamında ağrı ve hinge abduksiyon vardı.

**Bulgular:** Ortalama takip süresi 65 ay (dağılım 26-111 ay) idi. Proksimal valgus ekstansiyon osteotomisi ve tektoplasti uygulanan hastalarda, ameliyat sonrası femur başı kapsanması radyolojik olarak anlamlı derecede artmıştı. Ameliyat sonrası femur başı kapsanması cerrahi sonrası bir ve üçüncü aylarda çekilen grafilerle değerlendirildi. Osteotomi iyileştikten sonra, birinci yıl ve son kontrol grafileri değerlendirildi. Ameliyat öncesi ve ameliyat sonrası grafiler; subluksasyon oranı, femur başı örtülme oranı, femur başı boyut oranı, Sharp açısı, CE (merkez-kenar) açısı, boyun cisim açısı, kaput indeksi ve asetabuler derinlik endeksi gibi ölçümler üzerinden kapsamlı bir şekilde değerlendirildi. Sonuç olarak başlangıçtaki takip ve son takip grafileri değerlendirildiğinde radyolojik olarak anlamlı iyileşme ve gelişmeler tespit edildi.

**Sonuç:** Bu araştırma göstermiştir ki, valgus ekstansiyon osteotomisi ve tektoplasti uygulanan hinge abduksiyonlu hastalarda kısa sürede ağrı azalmış ve deformite düzelmiştir. Büyüme devam ettikçe, kalça eklemine yeniden şekillenmesi iyi yönde etkilenmektedir.

*Anahtar sözcükler:* Perthes hastalığı; osteotomi; tedavi sonucu.

The major goals of treatment in severe Perthes disease are to achieve femoral head containment and maintenance of hip motion and thus minimize the development of deformities and subsequent osteoarthritis.<sup>[1-3]</sup> Containment means a concentric position of the femoral head in the acetabulum to try to influence the shaping of the femoral head during the healing period.<sup>[1,4-6]</sup> Attention is focused on more definitive solutions by surgical means.<sup>[1,5,7]</sup> Surgical treatment in this study, however, is only indicated in the child "at risk".<sup>[2,3,6,8-11]</sup>

The existence of hinge abduction means the abnormal movement of the hip, which occurs when a deformed femoral head, often with a large uncovered anterolateral segment impinges on the lateral lip of the acetabulum. The end result may be incongruity of the hip and decreased coverage of the femoral head. A number of surgical techniques have been described to try and address hinge abduction, ranging from cheilectomy to shelf procedures. The valgus extension osteotomy also attempts to address lateral impingement on abduction as a salvage procedure.<sup>[2,8,9]</sup>

In this study, tectoplasty was combined with valgus extension osteotomy of the proximal femur. Tectoplasty is a type of acetabuloplasty devised in 1961 by Mizuno then Saito et al.<sup>[12]</sup> for the hip with multiple dysplastic acetabular deficiencies. The aim of this acetabuloplasty is to provide an extra-articular weight-bearing surface at the hip joint. We performed this combination on Herring group C hips, especially at older ages and with hinge abduction deformity. The purpose of this study was to evaluate the clinical outcomes of femoral valgus extension osteotomy combined with tectoplasty in head-at-risk Herring group C Perthes disease with radiographic results according to the Stulberg classification criteria and "containment" of the femoral head according to hip joint coverage, ratio of femoral head, and subluxation.<sup>[2,3,7]</sup>

## PATIENTS AND METHODS

All patients undergoing the operation of valgus extension osteotomy combined with tectoplasty between January 2002 and February 2009 were prospectively assessed and have been reviewed. The study group of 11 patients was male and classified as Herring group C according to the lateral pillar classification.

The mean age at the time of surgery was nine years and one month with an age range of six years to 11 years and two months. All patients had pain, decreased range of motion, limp and hinge abduction preoperatively. The minimum follow-up in all

patients was two years and three months and the mean follow-up was 5.5 years (range 2.2 to 9.3 years). We performed tectoplasty according to the definition of Saito et al.<sup>[12]</sup> A lateral approach for the valgus-extension osteotomy was performed to the proximal femoral shaft.<sup>[9]</sup> Extension was built in to the osteotomy. Partial weight bearing was permitted with crutches after graft union was observed on the radiograph, then the patient was advanced to full weight bearing.<sup>[8,9]</sup>

All radiographs were evaluated with key measurements made on the immediate preoperative, one-year postoperative and the final follow-up films. Preoperative extent of the disease was graded according to the lateral pillar classification of Herring et al.<sup>[7]</sup> These standard measurements including: subluxation ratio, femoral head coverage ratio, femoral head size ratio, Sharp angle, CE (center-edge) angle, neck shaft angle, caput index and acetabular depth index were obtained preoperatively, one year postoperatively and at the latest follow-up. At the latest follow-up, radiographic outcome was assessed using the modified Stulberg classification.<sup>[3]</sup>

Statistical analysis was performed using repeated measure variance analysis. There were no cases of non-union, infection or any other postoperative complication.

## RESULTS

Pain, moderate to severe limitation of range of movement, and limp were observed in all patients before surgery. Postoperative range of movement increased compared with preoperative values. Preoperative, one-year postoperative and final follow-up radiographic measured parameters are given as in the table 1.

The radiographic results at final follow-up revealed near full coverage of the femoral head; however, the femoral head remained larger than normal. Acetabular coverage increased from 68% to 89% ( $p < 0.000$ ) and subluxation ratio improved from 1.7 to 1.3 ( $p < 0.000$ ). Femoral head size ratio increased from 1.1 to 1.2 ( $p = 0.033$ ). Sharp angle decreased from 46.8° to 36.6° ( $p < 0.000$ ). CE angle increased from 14.5° to 38.6° ( $p < 0.000$ ). Neck shaft angle increased from 142.5° to 148.8° ( $p < 0.000$ ). Acetabular depth index improved from 0.27 to 0.31 ( $p = 0.028$ ). Caput index (sphericity =  $h/(d/2) \times 100\%$ ) changed from 69% to 74% and there was no significance with a  $p = 0.198$ . Using the radiographic classification of Stulberg et al.<sup>[3]</sup> 54% of our patients were classed as good (class II), 27% fair (class III) and 19% poor (class V) postoperatively.

TABLE I

Average of radiographic data for entire patient series

Parameter	Preoperative	Postoperative 1	Postoperative 2	<i>p</i>
	Mean±SD	Mean±SD	Mean±SD	
Subluxation ratio	1.7±0.4	1.5±0.3	1.3±0.2	<0.000
Femoral head coverage ratio	0.68±0.1	1.0±0.1	0.89±0.1	<0.000
Femoral head size ratio	1.1±0.1	1.2±0.2	1.2±0.1	0.033
Sharp angle	46.8±6.9	33.4±5.3	36.6±3.5	<0.000
Center-edge angle	14.5±5.7	44.1±6.1	38.6±7.7	<0.000
Neck shaft angle	142.5±9.3	152.8±8.3	148.8±6.0	<0.000
Caput index	0.69±0.14	0.66±0.16	0.74±0.09	0.198
Acetabular depth index	0.27±0.03	0.32±0.06	0.31±0.07	0.028

SD: Standard deviation.

## DISCUSSION

The biologic processes of Perthes disease constitute a self-healing disorder. There are no known treatments to speed the return on blood flow to the femoral head. Thus, treatment is indicated for control of symptoms, including pain, limp and limited range of motion and for severe disease (defined as a child older than six years of age, greater than 50% involvement of femoral head or 50% loss in the height of the lateral pillar and signs of femoral head extrusion or subluxation).<sup>[1,6,7,11]</sup>

The efficacy of treatment is the most controversial aspect of Perthes disease. Salter outlined the methods of treatment that are still used as guidelines today.<sup>[13]</sup> The goals of treatment include the elimination of hip irritability; restoration of a normal range of motion; prevention of subluxation, extrusion, or hinging; and maintenance of a round femoral head. A common thread running through these treatment goals is the concept of "containment". The purpose of containment is to contain the femoral head within the acetabulum to prevent deformity, permit physiologic motion, and promote remodeling.<sup>[3,9,14]</sup>

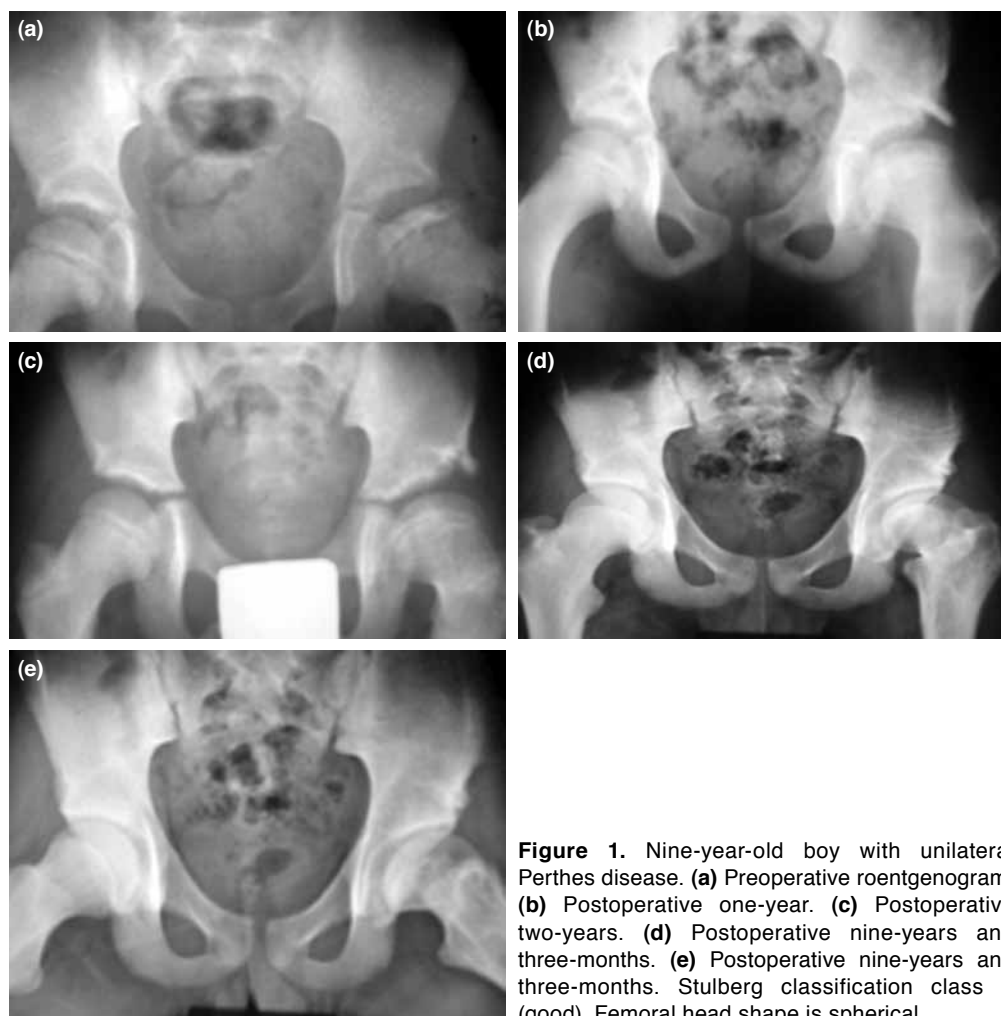
Preliminary results from multicenter studies of Perthes disease treatments suggest that operative management provides the best outcome in cases of severe disease.<sup>[15-17]</sup> Surgical containment can be achieved by proximal femoral varus osteotomy, valgus osteotomy, innominate osteotomy, an acetabular-shelf procedure, or some combination of femoral and pelvic procedures.<sup>[1,14,18]</sup> Proximal femoral osteotomy has been widely used in the surgical treatment of Perthes disease. By using the intraosseous venography technique Heikkinen et al. proved that intertrochanteric osteotomy lessens the venous stasis and achieves faster healing.<sup>[19-21]</sup>

Hinge abduction in Perthes disease occurs in later stages when the extruded, deformed femoral head

impinges on the lateral margin of the acetabulum during abduction of the hip, preventing containment and causing the medial surface of the femoral head to pull away from the medial wall of the acetabulum during attempted abduction.<sup>[8,9,11,22,23]</sup>

The shelf procedure and Chiari osteotomy are not designed to reduce lateral impingement during abduction. However, these two procedures result in improved coverage and pain relief in some patients.<sup>[7-9,14,18,24]</sup> In contrast, valgus extension osteotomy of the proximal femur unloads the lateral aspect of the femoral head and reestablishes the abductor mechanism while relieving impingement. Some authors postulated that the favorable remodeling was the result of the unloading of the lateral part of the femoral head. The advantage of this procedure is that it relieves pain, improves leg length, restores the normal abductor lever and in consequence improves the limp which is one of the patient's chief complaints. In this study we combined tectoplasty with the extension valgus osteotomy of the proximal femur.<sup>[7-9,14,24]</sup> Tectoplasty is a type of acetabuloplasty that aims to enlarge the weight-bearing surface at the hip and to prevent probable progression of osteoarthritis. We conclude that valgus-extension osteotomy combined with tectoplasty is an effective treatment for symptoms resulting from hinge abduction in Perthes disease. Good results are achievable in patients presenting at a later age and classified as Herring group C.<sup>[6-8,12]</sup>

In this study we found that the subluxation ratio, femoral head size ratio, Sharp angle, CE angle, neck shaft angle, lower extremity lengths, range of abduction and total range of motion were closer to normal after tectoplasty combined with valgus extension osteotomy. In our study 54% of the hips healed with Stulberg class II, 27% of the hips healed



**Figure 1.** Nine-year-old boy with unilateral Perthes disease. **(a)** Preoperative roentgenogram. **(b)** Postoperative one-year. **(c)** Postoperative two-years. **(d)** Postoperative nine-years and three-months. **(e)** Postoperative nine-years and three-months. Stulberg classification class II (good). Femoral head shape is spherical.

with Stulberg class III and 19% of the hips healed with Stulberg class V (Figure 1a-e).

Our data showed that tectoplasty procedure stimulated acetabular depth growth, whereas the femoral valgus osteotomy also has a stimulatory effect. This stimulatory effect is the result of stretching of the upper capsule due to Bombelli's valgus-extension osteotomy.<sup>[6,8,9,25]</sup> The radiological results of this study showed that Herring group C with hinge abduction hips had satisfactory outcome especially after nine years of age in patients treated with valgus osteotomy combined with tectoplasty. The cause of Perthes disease remains unknown, but the child who is at risk for a poor outcome has been identified and surgical containment appears to yield the best outcome with respect to a round femoral head. The outcome of the treatment depends on femoral head coverage since the more deformed and extruded the femoral head becomes, the worse the prognosis.<sup>[22]</sup> However a surgical solution to a

biological process like Perthes disease is not always successful.

#### Declaration of conflicting interests

The authors declared no conflicts of interest with respect to the authorship and/or publication of this article.

#### Funding

The authors received no financial support for the research and/or authorship of this article.

#### REFERENCES

1. Roy DR. Current concepts in Legg-Calvé-Perthes disease. *Pediatr Ann* 1999;28:748-52.
2. Willett K, Hudson I, Catterall A. Lateral shelf acetabuloplasty: an operation for older children with Perthes' disease. *J Pediatr Orthop* 1992;12:563-8.
3. Stulberg SD, Cooperman DR, Wallensten R. The natural history of Legg-Calvé-Perthes disease. *J Bone Joint Surg [Am]* 1981;63:1095-108.

4. Reddy RR, Morin C. Chiari osteotomy in Legg-Calve-Perthes disease. *J Pediatr Orthop B* 2005;14:1-9.
5. Skaggs DL, Tolo VT. Legg-Calve-Perthes Disease. *J Am Acad Orthop Surg* 1996;4:9-16.
6. Domzalski ME, Glutting J, Bowen JR, Littleton AG. Lateral acetabular growth stimulation following a labral support procedure in Legg-Calve-Perthes disease. *J Bone Joint Surg [Am]* 2006;88:1458-66.
7. Herring JA, Kim HT, Browne R. Legg-Calve-Perthes disease. Part II: Prospective multicenter study of the effect of treatment on outcome. *J Bone Joint Surg [Am]* 2004;86:2121-34.
8. Bankes MJ, Catterall A, Hashemi-Nejad A. Valgus extension osteotomy for 'hinge abduction' in Perthes' disease. Results at maturity and factors influencing the radiological outcome. *J Bone Joint Surg [Br]* 2000;82:548-54.
9. Myers GJ, Mathur K, O'Hara J. Valgus osteotomy: a solution for late presentation of hinge abduction in Legg-Calvé-Perthes disease. *J Pediatr Orthop* 2008;28:169-72.
10. Grzegorzewski A, Bowen JR, Guille JT, Glutting J. Treatment of the collapsed femoral head by containment in Legg-Calve-Perthes disease. *J Pediatr Orthop* 2003;23:15-9.
11. Aksoy MC, Cankus MC, Alanay A, Yazici M, Caglar O, Alpaslan AM. Radiological outcome of proximal femoral varus osteotomy for the treatment of lateral pillar group-C Legg-Calvé-Perthes disease. *J Pediatr Orthop B* 2005;14:88-91.
12. Saito S, Takaoka K, Ono K. Tectoplasty for painful dislocation or subluxation of the hip. Long-term evaluation of a new acetabuloplasty. *J Bone Joint Surg [Br]* 1986;68:55-60.
13. Salter RB. The present status of surgical treatment for Legg-Perthes disease. *J Bone Joint Surg [Am]* 1984;66:961-6.
14. Crutcher JP, Staheli LT. Combined osteotomy as a salvage procedure for severe Legg-Calvé-Perthes disease. *J Pediatr Orthop* 1992;12:151-6.
15. Kim WC, Hiroshima K, Imaeda T. Multicenter study for Legg-Calvé-Perthes disease in Japan. *J Orthop Sci* 2006;11:333-41.
16. Annamalai SK, Buckingham R, Cashman J. Perthes disease: a survey of management amongst members of the British Society for Children's Orthopaedic Surgery (BSCOS). *J Child Orthop* 2007;1:107-13.
17. Hefti F, Clarke NM. The management of Legg-Calvé-Perthes' disease: is there a consensus?: A study of clinical practice preferred by the members of the European Paediatric Orthopaedic Society. *J Child Orthop* 2007;1:19-25.
18. Poussa M, Yrjönen T, Hoikka V, Osterman K. Prognosis after conservative and operative treatment in Perthes' disease. *Clin Orthop Relat Res* 1993;297:82-6.
19. Atlıhan D, Subaşı M, Yıldırım H. Proximal femoral osteotomy for Perthes disease. *Eklem Hastalik Cerrahisi* 1999;10:155-9.
20. Heikkinen ES, Puranen J, Suramo I. The effect of intertrochanteric osteotomy on the venous drainage of the femoral neck in Perthes' disease. *Acta Orthop Scand* 1976;47:89-95.
21. Ghanem I, Haddad E, Haidar R, Haddad-Zebouni S, Aoun N, Dagher F, et al. Lateral shelf acetabuloplasty in the treatment of Legg-Calvé-Perthes disease: improving mid-term outcome in severely deformed hips. *J Child Orthop* 2010; 4:13-20.
22. Zenios M, Hutchinson C, Galasko CS. Radiological evaluation of surgical treatment in Perthes' disease. *Int Orthop* 2001;25:305-7.
23. Kuwajima SS, Crawford AH, Ishida A, Roy DR, Filho JL, Milani C. Comparison between Salter's innominate osteotomy and augmented acetabuloplasty in the treatment of patients with severe Legg-Calvé-Perthes disease. Analysis of 90 hips with special reference to roentgenographic sphericity and coverage of the femoral head. *J Pediatr Orthop B* 2002;11:15-28.
24. Wenger DR, Pring ME, Hosalkar HS, Caltoun CB, Lalonde FD, Bastrom TP. Advanced containment methods for Legg-Calvé-Perthes disease: results of triple pelvic osteotomy. *J Pediatr Orthop* 2010;30:749-57.
25. Bombelli R. Osteoarthritis of the hip. 2nd ed. Berlin Heidelberg New York: Springer-Verlag, 1983.