



A lipoma causing separation of toes in the second web space of the foot

Ayakta ikinci parmak aralığında parmaklarda ayrılmaya yol açan lipom

Rahmi Can Akgün, M.D.,¹ Esra Circi, M.D.,² Hüseyin Demirörs, M.D.,¹ İsmail Cengiz Tuncay, M.D.¹

¹Department of Orthopedics and Traumatology, Medicine Faculty of Başkent University, Ankara, Turkey;

²Department of Orthopedics and Traumatology, Sarkisla State Hospital, Sivas, Turkey

Lipomas are common and benign soft tissue neoplasms which are composed of fat cells. These tumors often develop where adipose tissue is present; however, they can be rarely found in the foot. In this article, we present a 55-year-old male case with a lipoma leading to separating toes in the second web space of the foot and mechanical discomfort.

Key words: Benign tumor; difficulty of shoe wearing; forefoot; lipoma; second web space.

Lipomlar sık görülen ve yağ hücrelerinden oluşan benign, yumuşak doku tümörleridir. Bu tümörler sıklıkla yağ dokunun bulunduğu yerlerde gelişir; bununla birlikte nadiren ayakta da bulunabilir. Bu yazıda, ayak ikinci parmak aralığında parmaklarda ayrılmaya ve mekanik sorunlara neden olan lipomu olan 55 yaşında bir erkek olgu sunuldu.

Anahtar sözcükler: Benign tümör; ayakkabı giymekte zorluk; ön ayak; lipom; ikinci parmak aralığı.

A lipoma is composed of well-differentiated adipocytes and is the most common soft tissue mass. This benign, slow-growing, circumscribed tumor can originate at any site of the body that contains adipose tissue. Most lipomas usually present as non-painful, asymptomatic, round, mobile masses with a characteristic soft, doughy texture. They can be diagnosed via clinical examination and do not require treatment. Some lipomas are believed to develop after blunt trauma. Reports of a lipoma in the foot exist, but the occurrence of the tumor in this location is rare.^[1-6] We present a benign lipoma occurring on the foot in the second web space that caused separating toes in the second web space and mechanical discomfort in a male.

CASE REPORT

A 55-year-old man with swelling in the second web space of the right foot that made wearing shoes and walking difficult presented to our orthopedic clinic. The swelling had been present for five years and had grown slowly. There was no history of trauma or infection. The patient had no systemic disease.

On physical examination, the mass involved the second web space displacing the second and third toes (Figure 1). This mass was soft on palpation and produced no pain for the man. No inflammation was noted. The results of a vascular examination were normal, but hypoesthesia existed on the dorsum of the second and third toes. Radiographs showed a soft tissue shadow in the second web space with mild displacement of the adjacent toes; no bony pathology was present (Figure 2). A magnetic resonance imaging scan showed a lesion with high intensity consistent with adipose tissue on T1- and T2-weighted imaging; it extended up between the second and third toes (Figure 3). Owing to the patient's complaint, surgical treatment was advised. Under regional anesthesia and tourniquet hemostasis, the lesion was approached through a curvilinear incision over the central portion of the mass. Blunt dissection was then used to identify the borders of the mass which was then excised. Gross examination showed a 5x3x2 cm elliptical, encapsulated, soft, yellow mass (Figure 4). It resembled normal adipose tissue. Histologic examination

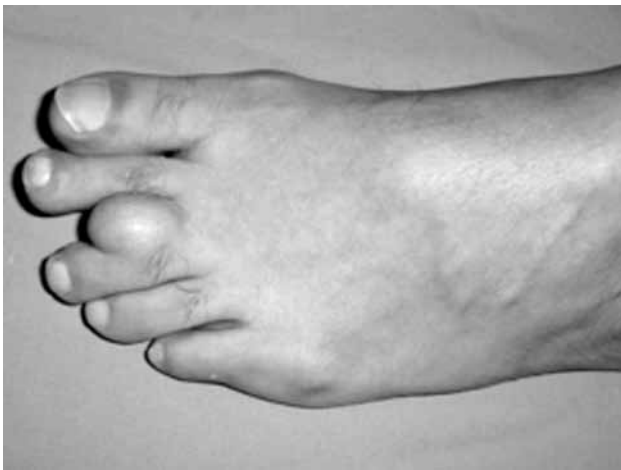

Figure 1. Clinical view of the soft-tissue mass in the second web space.

revealed a lipoma characterized by mature adipocyte clusters separated by well-vascularized collagen bundles showing myxoid degeneration (Figure 5). The postoperative healing was uneventful. At three month's follow-up, there was no hypoesthesia and no mechanical discomfort and the patient could wear proper footwear.

DISCUSSION

Soft-tissue tumors of the foot are not particularly common,^[7,8] among these, foot lipomas are rare. The occurrence of a lipoma of the interdigital area is very rare. A few cases of lipomas at different sites of the foot have been reported previously.^[1,2,4-6]

Milgram et al.^[9] reported a massive fibrolipoma of a toe and Pirela-Cruz et al.^[10] reported a lipoblastoma that contained immature fat cells involving the second toe. Lisch et al.^[11] reported a lipoma that completely involved the fourth digit of the foot. Vandeweyer et

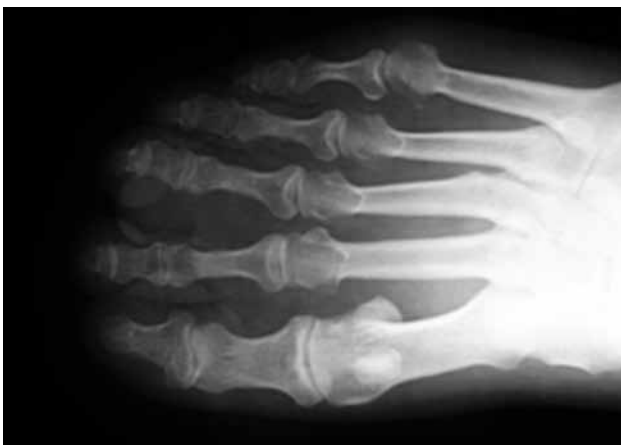

Figure 2. Radiography showing the soft tissue shadow, no bony involvement.

al.^[12] reported a lipoma on the plantar aspect of the second toe. Kerman and Foster^[13] described a lipoma in the lateral plantar aspect of the left heel and Abenavoli^[14] reported a lipoma in the dorsum of the foot that implicated a second toe. To our knowledge, this is the first report of a lipoma involving the second web space.

Karaçal et al.^[15] reported a 13 cm expanding lipoma on the first toe. Similarly, Azam et al.^[16] presented a rapidly expanding 10 cm lipoma on the lateral aspect of the third toe encompassing the third web space. In the patient reported here, the mass started as a small swelling and grew slowly for five years to its presenting size.

Lipomas may recur, although after local excision, the recurrence rate less than 5%.^[17] Malignant changes have been reported in the literature in only a few cases.^[18]

Our patient's lipoma was not painful when touched or when deep pressure was applied. Tumorlike lesions with clinical characteristics similar to those of a lipoma of the foot and rare variants of a lipoma must be

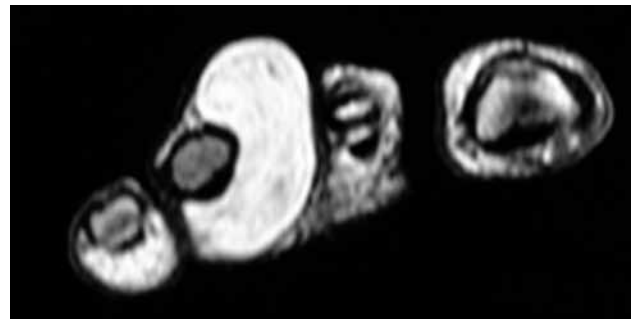


Figure 3. T1-weight coronal magnetic resonance imaging showing a well-defined lobulated mass surrounding the second web space, consistent with lipomatous tumor.

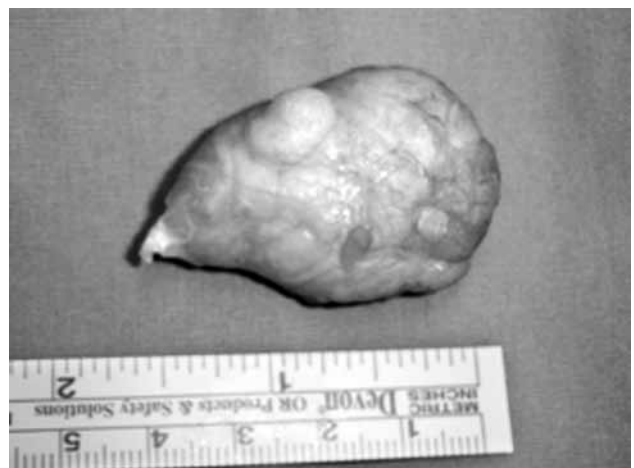

Figure 4. Well-defined, encapsulated mass after excision.

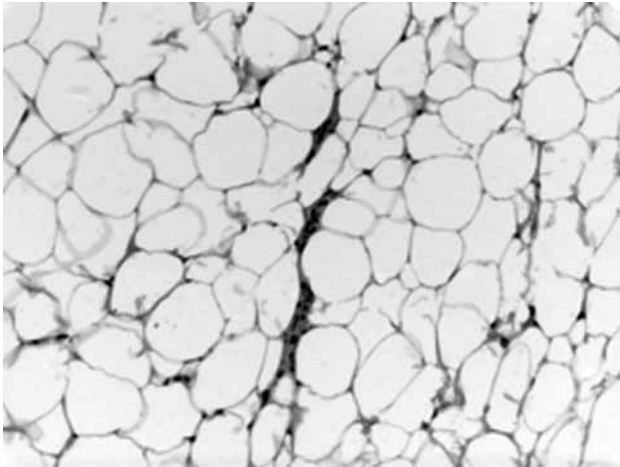


Figure 5. Photomicrography of the mass, showing viable mature fat cells (H-E x 20).

considered. Several histologic subtypes of lipoma (fibrolipoma, spindle cell lipoma, infiltrating lipoma, angioliipoma, myxoid lipoma, atypical lipoma, and pleomorphic lipoma) have also been reported.^[19] Other lesions (synovial, ganglion, or epidermal inclusion cysts) and infections are more easily differentiated from lipoma.^[20] In our patient, diagnosis was confirmed by the results of histologic evaluation.

In conclusion, although lipomas of the foot in the interdigital area are rare, they must be considered in the differential diagnosis of soft tissue masses of the foot. However, if the mass causes neurovascular compromise, causes separating toes and mechanical discomfort or interferes with wearing shoes and/or with walking, it should be excised.

Declaration of conflicting interests

The authors declared no conflicts of interest with respect to the authorship and/or publication of this article.

Funding

The authors received no financial support for the research and/or authorship of this article.

REFERENCES

1. Copeland CL, Kanat IO. A large lipoma involving the foot. *J Foot Surg* 1991;30:571-3.
2. Cristofaro RL, Maher JO 3rd. Digital lipoma of the foot in a child. A case report. *J Bone Joint Surg [Am]* 1988;70:128-30.
3. Greenberg GS. Lipomas: discussion and report of an unusual case. *J Foot Surg* 1980;19:68-70.
4. Yildirim FB, Yildirim A, Sarikcioglu L, Ucar Y. Deep-seated lipoma of the foot. *West Indian Med J* 2007;56:388-9.
5. Weissinger WJ, Gerber JH. A bizarre lipoma of the hallux. *J Am Podiatr Med Assoc* 1985;75:101-4.
6. Yu GV, Sellers CS. Extensive lipoma of the foot. A case report. *J Am Podiatr Med Assoc* 1995;85:488-92.
7. Özcan Ö, Boya H, Araç Ş, Tandoğan R. Subungual osteochondroma: a case report. *Eklem Hastalik Cerrahisi* 2006;17:53-5.
8. Kalacı A, Özkan C, Sevinç TT, Yanat AN. Giant-cell tumor of the tendon sheath in the toe: a report of three cases. [Article in Turkish] *Eklem Hastalik Cerrahisi* 2008;19:33-7.
9. Milgram JW. Massive fibrolipoma of a toe. *J Foot Ankle Surg* 1999;38:223-6.
10. Pirela-Cruz MA, Herman D, Worrell R, Miller RA. Lipoblastoma circumscripta of the toe: a case report and review of the literature. *Foot Ankle* 1992;13:478-81.
11. Lisch M, Mittleman M, Albin R. Digital lipoma of the foot: an extraordinary case. *J Foot Surg* 1982;21:330-4.
12. Vandeweyer E, Van Geertruyden J, de Fontaine S. Lipoma of the toe. *Foot Ankle Int* 1998;19:246-7.
13. Kerman BL, Foster LS. Lipoma of the foot: a large and unusual case. *J Foot Surg* 1985;24:345-8.
14. Abenavoli FM. An unusual foot lipoma. *Plast Reconstr Surg* 2000;105:1906.
15. Karaçal N, Yavuz E, Topal U, Ambarcioğlu O, Kutlu N. Massive expanding lipoma of the toe. *Plast Reconstr Surg* 2004;113:1100-1.
16. Azam A, Rajagopalan S, Niezywinski WA. A rapidly expanding massive lipoma of the toe. *J Foot Ankle Surg* 2007;46:499-501.
17. Pontious J, Zielaskowski LA, King G. Extensive lipoma of the foot. *J Am Podiatr Med Assoc* 2003;93:402-5.
18. Shmookler BM, Enzinger FM. Pleomorphic lipoma: a benign tumor simulating liposarcoma. A clinicopathologic analysis of 48 cases. *Cancer* 1981;47:126-33.
19. Weiss SW. Lipomatous tumors. *Monogr Pathol* 1996;38:207-39.
20. Crundwell N, O'Donnell P, Saifuddin A. Non-neoplastic conditions presenting as soft-tissue tumours. *Clin Radiol* 2007;62:18-27.