



Does surgically fixation of pubic fracture increase the stability of the operated posterior pelvis?

Pubis kırığının cerrahi tespiti ameliyat edilen arka pelvisin stabilitesini artırır mı?

Tamás Bodzay, M.D. PhD.,¹ Gergely Sztrinkai, M.D.,¹ Sándor Pajor, M.D.,¹ Tamás Gál, M.D.,²
Zoltán Jónás, M.D.,³ Péter Erdős,⁴ Károly Váradi, PhD, D.Sc.⁴

¹Trauma Centre, Péterfy Hospital, Budapest, Hungary

²Department Trauma, Semmelweis University, Budapest, Hungary

³Department of Orthopaedic Surgery, University of Debrecen, Medical and Health Centre, Debrecen, Hungary

⁴Faculty of Mechanical Engineering, Institute of Machine Design, University of Technology and Economics, Budapest, Hungary

Objectives: This study aims to investigate whether surgical treatment of pubic rami fractures increases the stability of the posterior pelvis.

Material and methods: A finite element pelvic model with improved geometric and material characteristics was analyzed. By imitating a standing position, a type I Denis sacrum fracture and a unilateral pubis fracture, we measured the differences in tension and displacement. The posterior injury was treated with a direct plate synthesis or transsacral plate synthesis, while the pubis fracture was left without fixation or fixed with either a retrograde pubic screw or plate synthesis.

Results: The operative fixation of pubic rami fractures decreased the movement in the fracture gap not only at the site of the pubis fracture, but also at the site of the fixed sacrum fracture. The plate synthesis provided greater stability of the anterior fracture than the retrograde screw. The tensions in the implants were below the allowed values.

Conclusion: We concluded that surgically fixation of pubic fracture increases the stability of the operated posterior pelvis.

Key words: Finite element analysis; pelvic ring; pubic fracture; pubic plate; retrograde pubic screw.

Amaç: Bu çalışmada pubis rami kırıklarının cerrahi tedavisinin arka pelvisin stabilitesini artırıp artırmadığı araştırıldı.

Gereç ve yöntemler: Düzeltilmiş geometrik ve materyal özellikleri ile sonsuz eleman pelvis modeli incelendi. Ayakta iken tip I Denis sakrum kırığı ve tek taraflı pubis kırığı taklit edilerek, gerilim ve yer değiştirme açısından farklar ölçüldü. Arka yaralanma direkt plak sentezi veya transsakral plak sentezi ile tedavi edilirken, pubis kırığına tespit yapılmadı veya retrograd pubis vidası veya plak sentezi ile tespit yapıldı.

Bulgular: Cerrahi tespit yapılan pubis rami kırıkları, yalnızca pubis kırığı bölgesinde değil, aynı zamanda tespit yapılan sakrum kırığı bölgesinde de kırık boşluğundaki hareketi azalttı. Plak sentezi ile retrograd vidaya kıyasla ön kırıkta daha fazla stabilizasyon sağlandı. İmplantlardaki gerilim, izin verilen değerlerin altındaydı.

Sonuç: Pubis kırığının cerrahi tespiti, ameliyat edilen arka pelvisin stabilitesini artırır.

Anahtar sözcükler: Sonlu eleman analizi; pelvis halkası; pubis kırığı; pubis plağı; retrograde pubis vidası.

The posterior portion of the pelvis plays a significant role in the weight bearing of the pelvic ring. The entire weight of the upper body is transferred to the hip joints and lower limbs through the lumbar five-sacral one (LV-SI) connection, the sacrum and the linea terminalis. Therefore, the priority is the

surgical fixation of the posterior ring in type C pelvis injuries. Currently, many surgical fixation methods are available such as iliosacral screw fixation,^[1,2] plate synthesis on the ventral side of the sacroiliac (SI) joint,^[3] transsacral plate synthesis,^[4,5] and local plate synthesis with the decompression of the sacral nerve

roots on the dorsal cortex of the sacrum.^[6] The choice of the operative method depends on the overall and hemodynamic status of the patient, associated injuries, condition of the soft tissue surrounding the pelvis, the configuration of the pelvic injury, as well as the preference of surgical team. The surgical fixation of a symphysiolysis larger than 2-3 cm is mandatory in anterior pelvic ring injuries.^[7] It is, however, questionable whether the simultaneous operative synthesis of the pubic fracture is necessary during the surgical fixation of the posterior ring injury. Of 105 cases of pubic fractures associated with pelvis injuries, Matta^[8] did not identify re-dislocation in the surgically fixed posterior ring injury in 88 cases. Later, Simonian et al.^[9] performed stability tests in these cases and found that significantly less movement was detected in the SI joint in surgically treated pubic fractures. The plate synthesis of the pubic fracture offered greater stability than the retrograde pubic ramus screw. In our present study, we used finite element modeling to try to answer the question that if the posterior pelvic ring injury was surgically fixed, then how much does the fixation of pubic fracture increase the stability of the posterior synthesis.

MATERIAL AND METHODS

Anatomic model

In our previous studies, we used the simplified geometric pelvis models. In the first phase of our present study, we first created a more realistic model by three dimensional (3D) scanning a plastic pelvis model.^[10] This was followed by modeling a Denis type I sacrum fracture and ipsilateral inferior and superior pubis rami fractures. The surgical fixation methods were as follows: the pubic bone fracture was left without fixation or fixed with either a retrograde pubic screw or a plate synthesis containing four screw holes. The fixation of the sacrum fracture was performed either with the most stable direct plate synthesis or the least stable transsacral plate, based on our previous studies.

Geometric model

In the more realistic geometric model, we modeled node-to-node contact in the hip joint and at the fracture site, whereas a bonded contact was modeled in all other intact joints (symphysis, sacroiliac joints, and intervertebral joints).

Material model

In this examination, similarly to the previous model, we also differentiated between the cortical and cancellous bone at the fracture and synthesis sites.

We used a homogenous bone mass in the indifferent zones, with proportion to volume of that area, since our present program is also incapable of modeling the separate cortical and cancellous matter of the entire pelvis. In our previous model, we estimated the cortical-cancellous bone ratio to be 10-90%. The present model was developed using the computed tomography (CT) imaging of an intact pelvis. Ten slices of cortical and cancellous bone ratios were calculated each in the sacrum and hip bones, and using these "slices", we calculated the "homogenous" bone characteristics in proportion to cortical and cancellous bone.^[11] As in the previous examinations, the material properties were chosen according to data of Abé et al.^[12] The validation of the model was performed on cadaver experiments, as mentioned in our previous publication,^[13] that is, we modeled Denis type I sacrum fracture and symphysiolysis; the symphysiolysis was fixed with a four-hole plate and the sacrum fracture was fixed with either a transsacral plate or direct plate synthesis.

Load and boundary parameters

Case 1, 2– Inferior and superior pubic rami fractures and Denis type I sacrum fracture, weight bearing on both lower limbs: load on the promontorium, in the Z-axis, 500 N, both femurs fixed, the pelvis is posteriorly supported against displacement in the Y-axis; node-to-node contact in both hip joints and at the fracture site; bonded contact in other joints; No fixation in the pubic fractures, direct plate or transsacral plate synthesis of the sacrum.

Case 3, 4– Inferior and superior pubic rami fractures and Denis type I sacrum fracture, weight bearing on both lower limbs: retrograde screw fixation of the pubic rami fractures; all other parameters are identical to case 1.

Case 5, 6– Inferior and superior pubic rami fractures and Denis type I sacrum fracture, weight bearing on both lower limbs: The pubic rami fractures are fixed with four-hole plate synthesis; all other parameters are identical to case 1.

SolidWorks 2013 program was used for the finite element analysis; the finite element model contained approximately 140,000 hexahedron elements (Figure 1).

RESULTS

The main results were as follows

Case 1– Inferior and superior pubic rami fractures and Denis type I sacrum fracture; no fixation in the pubic fractures, direct plate synthesis of the sacrum.

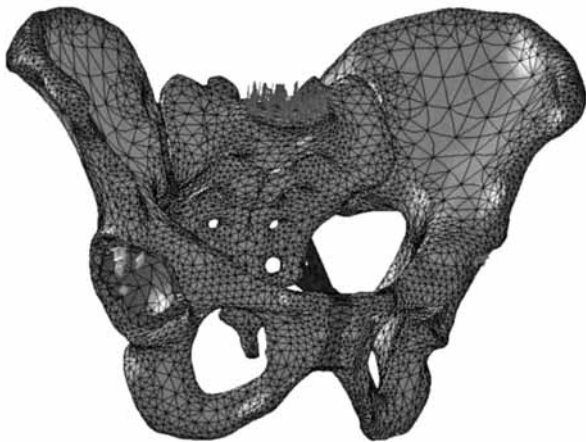


Figure 1. New pelvic model and finite element model.

Maximum tension in the bones was 26.7 MPa, in the metals was 62.8 MPa; displacement in the fracture gap of the sacrum was 0.4 mm, displacement in the fracture gap of the pubic rami was 0.2 mm.

Case 2– Inferior and superior pubic rami fractures and Denis type I sacrum fracture; no fixation in the pubic fractures, transsacral plate synthesis of the sacrum. Maximum tension in the bones was 242.7 MPa, in the metals was 616.6 MPa; displacement in the fracture gap of the sacrum was 2.9 mm, displacement in the fracture gap of the pubic rami was 3.1 mm.

Case 3– Inferior and superior pubic rami fractures and Denis type I sacrum fracture; retrograde pubic screw fixation in the pubic fractures, direct plate synthesis of the sacrum. Maximum tension in the bones was 102.8 MPa, in the metals was 100.1 MPa; displacement in the fracture gap of the sacrum was 2.9 mm, displacement in the fracture gap of the pubic rami was 3.1 mm (Figure 2).

Case 4– Inferior and superior pubic rami fractures and Denis type I sacrum fracture; retrograde pubic

screw fixation in the pubic fractures, transsacral plate synthesis of the sacrum. Maximum tension in the bones was 32.8 MPa, in the metals was 103.6 MPa; displacement in the fracture gap of the sacrum was 1.06 mm, displacement in the fracture gap of the pubic rami was 0.1 mm.

Case 5– Inferior and superior pubic rami fractures and Denis type I sacrum fracture; four-hole plate synthesis of the pubic fractures, direct plate synthesis of the sacrum. Maximum tension in the bones was 104.3 MPa, in the metals was 461.5 MPa; displacement in the fracture gap of the sacrum was 0.01 mm, displacement in the fracture gap of the pubic rami was 0.04 mm (Figure 3).

Case 6– Inferior and superior pubic rami fractures and Denis type I sacrum fracture; four-hole plate synthesis of the pubic fractures, transsacral plate synthesis of the sacrum. Maximum tension in the bones was 36.1 MPa, in the metals was 123.5 MPa; displacement in the fracture gap of the sacrum was 1.3 mm, displacement in the fracture gap of the pubic rami was 0.02 mm (Figure 4). The measured results are summarized in Table 1.

DISCUSSION

From a mechanical point of view, the stability of the posterior portion of the pelvic ring is outstanding. The weight of the upper body is transferred to the lower limbs through the sacrum and the linea terminalis into the hip joints. As a result, there are numerous studies concerning the operative fixation of the posterior pelvic ring injuries, and the stability values which were provided by the chosen operative procedures are known.^[14] Of the anterior pelvic ring injuries, the indication for the surgical fixation of symphysiolysis is also obvious: in cases where the symphysiolysis is greater than 2-3 cm, operative stabilization is necessary^[7] The necessity for the operative synthesis of pubic fractures is questionable.

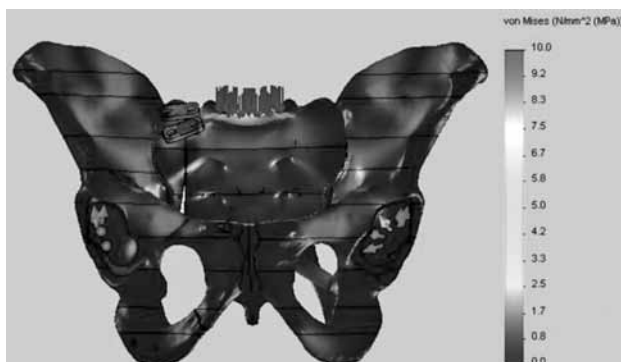


Figure 2. Distribution of tension in the model in Case 3.

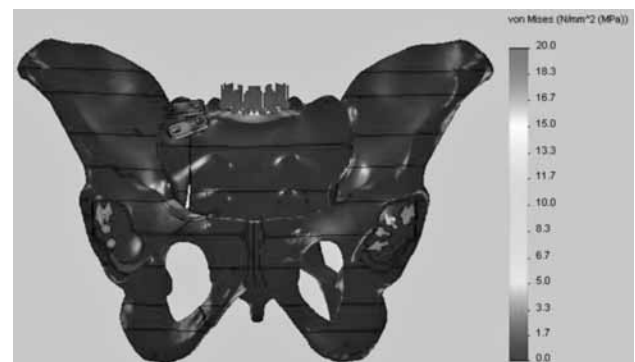


Figure 3. Distribution of tension in the model in Case 5.




Figure 4. Distribution of tension in the model in Case 6. (a) Anterior view; (b) Posterior view.

There are several methods available including the stabilization of the anterior ring with external fixators as an indirect technique, or internal fixation methods such as retrograde pubic medullary screws and plate syntheses. Internal fixation may be appropriate in cases during the treatment of associated visceral injuries caused by the pubic bone fracture, or in women of fertile age, where there is a greater dislocation of the pubic fracture. Simonian et al.^[9] performed biomechanical tests in this direction using cadaver experiments. He examined the movements in the SI joints and the ipsilateral pubic fractures, without any fixation to the SI lysis. In the first case, the pubic fracture was not fixed, then he examined plate synthesis and retrograde medullary pubic ramus screw fixation methods. For comparison, he examined the SI joint movements of intact pelvis. He found that significantly less movement was detected in the injured SI joint, if the pubic fracture was operatively treated. The plate synthesis of the pubic fracture offered greater stability than the retrograde pubic ramus screw.^[12] In our present study, we measured the stability of the internal osteosynthesis used for fixation of the pubic fracture. We used a more realistic geometric pelvic model than the one in our previous tests. We also modified the material properties of the pelvic bone stock using the data from CT scans. As opposed to the SI joint lysis in cadaver experiments

by Simonian et al.,^[9] we modeled a sacrum fracture; this posterior ring injury was operatively stabilized on the model with either a direct plate synthesis, which provides the most stability or with the least stable transsacral plate. With our calculations, we determined that the surgical fixation of the pubic fracture not only reduced the movements in the fracture gap of the pubic fracture itself, but in all cases reduced the displacement values in the operatively stabilized sacrum fracture also. The plate synthesis of the pubic fracture offers greater stability in the anterior pelvic ring fracture and better protects the posterior osteosynthesis than the retrograde pubic ramus screws. However, as clinical practice and our previous measurements demonstrated that the stabilization of the posterior ring injury alone provides enough stability, the question arises that when is it worth it or necessary to perform operative fixation of the pubis fracture? In an analogy to the surgical treatment of a symphysiolysis which is performed as a final step in case of a laparotomy, it seems evident that the pubic fracture is to be treated with a plate synthesis when an intrapelvic procedure becomes necessary, such as in the case of the treatment of urinary bladder injury, or the removal of a previously inserted hemostatic pelvic tamponade. In case of no need for intrapelvic treatment, the retrograde pubic medullary ramus screws are then preferable for the

TABLE I

Maximum tension and displacement values in six models

	Max. strain of bone (MPa)	Max. strain of implant (MPa)	Dislocation in fracture gap. Sacrum (mm)	Dislocation in fracture gap. Os pubis (mm)
Case 1	26.7	62.8	0.4	0.2
Case 2	242.7	616.6	2.9	3.1
Case 3	102.8	100.1	0.04	0.1
Case 4	32.8	103.6	1.06	0.1
Case 5	104.3	461.5	0.01	0.04
Case 6	36.1	123.5	1.3	0.02

treatment of bilateral pubis injuries associated with bilateral posterior ring injuries. It is also necessary to perform retrograde ramus screw fixation of the pubis fracture if it is located on the contralateral side of an associated posterior ring injury, which requires a period of non-weight bearing during healing.

Declaration of conflicting interests

The authors declared no conflicts of interest with respect to the authorship and/or publication of this article.

Funding

The authors received no financial support for the research and/or authorship of this article.

REFERENCES

1. Routt ML Jr, Meir MC, Kregor PK, Mayo KM. Percutaneous iliosacral screws with the patient supine technique. *Operat Tech Orthop* 1993;3:35-45.
2. Routt ML Jr, Kregor PJ, Simonian PT, Mayo KA. Early results of percutaneous iliosacral screws placed with the patient in the supine position. *J Orthop Trauma* 1995;9:207-14.
3. Ragnarsson B, Olerud C, Olerud S. Anterior square-plate fixation of sacroiliac disruption. 2-8 years follow-up of 23 consecutive cases. *Acta Orthop Scand* 1993;64:138-42.
4. Szita J. Treatment of pelvic injuries. In: Cziffer E, editor. *Operatív Treatment of the Fractures (in Hungarian)*. Budapest: Springer Hungarica; 1997. p. 417-425
5. Mears DC, Capito CP, Deleuw H. Posterior pelvic disruptions managed by the use of the Double Cobra Plate. *Instr Course Lect* 1988;37:143-50.
6. Pohlemann T, Angst M, Schneider E, Ganz R, Tscherne H. Fixation of transforaminal sacrum fractures: a biomechanical study. *J Orthop Trauma* 1993;7:107-17.
7. Tile M. Pelvic ring fractures: should they be fixed? *J Bone Joint Surg [Br]* 1988;70:1-12.
8. Matta JM. Indications for anterior fixation of pelvic fractures. *Clin Orthop Relat Res* 1996;329:88-96.
9. Simonian PT, Routt ML Jr, Harrington RM, Tencer AF. Internal fixation of the unstable anterior pelvic ring: a biomechanical comparison of standard plating techniques and the retrograde medullary superior pubic ramus screw. *J Orthop Trauma* 1994;8:476-82.
10. Sztrinkai G, Bodzay T, Pajor S, Erdős P, Vendégh Z, Jónás Z, et al. Further development of our finite element pelvic model to compare fixation methods for pelvic fractures. *Eklek Hastalik Cerrahisi* 2014;25:8-14.
11. Scholz R, Hoffmann F, von Sachsen S, Drossel WG, Klöhn C, Voigt C. Validation of density-elasticity relationships for finite element modeling of human pelvic bone by modal analysis. *J Biomech* 2013;46:2667-73.
12. Abé H, Hayashi K, Sato M. *Data Book on Mechanical Properties of Living Cells, Tissues, and Organs*, 1st. ed Tokyo: Springer Verlag; 1996.
13. Bodzay T, Szita J, Manó S, Kiss L, Jónás Z, Frenyó S, et al. Biomechanical comparison of two stabilization techniques for unstable sacral fractures. *J Orthop Sci* 2012;17:574-9.
14. Bodzay T, Flóris I, Váradi K. Comparison of stability in the operative treatment of pelvic injuries in a finite element model. *Arch Orthop Trauma Surg* 2011;131:1427-33.