



Effect of Ankaferd blood stopper® on tendon healing: an experimental study in a rat model of Achilles tendon injury

Ankaferd Kanama Durdurucu®'nun tendon iyileşmesi üzerine etkisi:
Sıçan Aşil tendon yaralanma modelinde deneysel çalışma

Bahattin Kerem Aydın, MD.,¹ Egemen Altan, MD.,¹ Mehmet Ali Acar, MD.,¹
Ömer Faruk Erkoçak, MD.,¹ Serdar Ugraş, MD.²

¹Department of Orthopedics and Traumatology, Medical Faculty of Selçuk University, Konya, Turkey

²Department of Pathology, Konya Training and Research Hospital, Konya, Turkey

ABSTRACT

Objectives: This *in vivo* study aims to investigate the effects of Ankaferd Blood Stopper® (ABS) which is a recently developed topical hemostatic agent on tendon healing using a rat Achilles tendon injury model.

Materials and methods: Twelve male Wistar-Albino rats were used in the study. Right legs of the rats were assigned as the study group, and left legs were assigned as the control group. Under anesthesia, bilateral Achilles tendon injuries were created and repaired surgically. To the surgical sites, 1 mL of ABS for the right side and 1 mL of serum physiologic solution for the left side were applied. Animals were euthanized on the 21st postoperative day, and tendon samples were collected from the extremities. Histological analyses were performed according to the semiquantitative tendon scoring system (Bonar Scale).

Results: Total tendon healing scores were significantly poorer in the study group compared to the control group. Although there were no significant differences between the groups in terms of tenocyte morphology, degree of ground substance staining, and vascularity, the collagen morphology scores were significantly poorer in the study group.

Conclusion: In our study, application of ABS had histologically negative effect on tendon healing in rats. However, further biomechanical and immune histochemical studies are required to support these results.

Keywords: Achilles tendon; Ankaferd Blood Stopper; hemorrhage; hemostasis; tendon injuries.

ÖZ

Amaç: Bu *in vivo* çalışmada yeni geliştirilen topikal bir hemostatik ajan olan Ankaferd Kanama Durdurucu®'nun (ABS) sıçan Aşil tendon yaralanma modeli kullanılarak tendon iyileşmesi üzerine etkileri araştırıldı.

Gereç ve yöntemler: Çalışmada 12 erkek Wistar-Albino sıçan kullanıldı. Sıçanların sağ bacakları çalışma grubu, sol bacakları kontrol grubu olarak belirlendi. Anestezi altında iki taraflı Aşil tendon yaralanmaları oluşturuldu ve cerrahi olarak tamir edildi. Cerrahi sahalara sağ taraf için 1 mL ABS, sol taraf için ise 1 mL serum fizyolojik solüsyonu uygulandı. Hayvanlara ameliyat sonrası 21. günde ötenazi yapıldı ve ekstremitelerden tendon örnekleri alındı. Histolojik analizler yarı kantitatif tendon skorlama sistemine (Bonar Sınıflaması) göre yapıldı.

Bulgular: Toplam tendon iyileşmesi skorları çalışma grubunda kontrol grubuna göre anlamlı şekilde kötüydü. Tenosit morfolojisi, esas madde boyama derecesi ve vaskülarite açısından gruplar arasında anlamlı farklılık olmasa da kollajen morfolojisi skorları çalışma grubunda anlamlı şekilde kötüydü.

Sonuç: Çalışmamızda, ABS uygulaması sıçanlarda tendon iyileşmesi üzerinde histolojik olarak olumsuz etkiye sahipti. Öte yandan, bu sonuçları desteklemek için ileri biyomekanik ve immünohistokimyasal çalışmalar gereklidir.

Anahtar sözcükler: Aşil tendonu; Ankaferd Kanama Durdurucu; kanama; hemostaz; tendon yaralanmaları.

Injuries to tendons are among the most common injuries to the body.^[1] Tendon injuries are not only responsible for large health care costs, but they also result in lost work time and individual morbidity.^[2] For adequate repair, proper visualization of the ends of the injured tendons and avoiding the postoperative adhesions and the bleeding are necessary. Although tourniquets are used during tendon repairs, surgery time can sometimes be longer than two hours due to multiple tendon injuries, additional nerve, vascular and bone procedures which may prevent safe usage of the tourniquets. Also, during the postoperative period, bleeding in surgical site may cause hematoma and prolonged drainage which may lead to patient discomfort. Moreover, tourniquets are not effective for some surgical sites such as proximal biceps and proximal rectus femoris.

In vitro and *in vivo* studies have reported about different hemostatic agents that are commonly used for the management of hemorrhage.^[3-6] The effects of hemostatic agents on different soft tissues for wound healing are still being investigated.

Ankaferd Blood Stopper® (ABS) (Ankaferd İlaç Kozmetik A.Ş, İstanbul, Turkey) is a recently developed topical hemostatic agent that has been approved in the management of external hemorrhage by the Ministry of Health in Turkey.^[5] In the late 2000s, Turkish physicians standardized ABS as a modern hemostatic agent by making known its pharmacodynamics and molecular mechanisms.^[3,5-7] Ankaferd Blood Stopper® has been shown to have hemostatic and regenerative proliferation effects in studies conducted *in vivo* and *in vitro*.^[8,9] Ankaferd Blood Stopper® stimulates the construction of a protein network with an alternative pathway via affecting cellular mechanisms.^[8] Ankaferd Blood Stopper®-induced formation of the protein network with vital erythroid aggregation covers the entire physiological hemostatic process.^[10]

Studies were reported in the literature about the effects of ABS on wound healing in different kinds of tissues such as bone, liver, esophagus, and dermal wound injuries.^[5,11-13] No negative effects on wound healing have been reported. Still, there is a lack of information about the effects of ABS on tendon healing. Therefore, in this study, we aimed to investigate the effects of ABS on tendon healing using a rat Achilles tendon injury model.

MATERIALS AND METHODS

Twelve male Wistar-Albino rats weighing a mean of 410 g (400 g - 425 g) were used in this study.

The experimental design and all procedures were approved by the Selçuk University Animal Research and Ethics Committee, and the experimental animals were obtained from the Laboratory of Experimental Animals, Selçuk University, Konya, Turkey.

A well-known rat tendon injury model was used for this study.^[14-16] The right legs of the rats were assigned as the study group (ABS), and the left legs were assigned as the control group (0.9% NaCl). Operations were conducted under general anesthesia with intraperitoneal injection of ketamine 50 mg/kg (Ketalar; Eczacıbasi, İstanbul, Turkey) and xylazine hydrochloride 10 mg/kg (Rompun; Bayer, Leverkusen, Germany). Bilaterally, the lower limbs were shaved and disinfected using povidone-iodine, and surgery was performed under sterile conditions. After extremity preparation, a posterior midline incision was made to expose the Achilles tendon. Bilateral Achilles and plantaris tendons were exposed and tenotomised with no. 15 scalpels at approximately 5 mm proximal to the insertion to the calcaneus. One mL of ABS was applied to the right legs and 1 mL isotonic NaCl was applied to the left legs. Dosages were determined according to a previous experimental study.^[9] All tendons were repaired with 4/0 polypropylene suture (Propilen; Doğsan, Trabzon, Turkey) using a modified Kessler-type technique (Figure 1). The surgical wounds were closed primarily with skin sutures only, which were 3/0 polypropylene (Propilen, Doğsan, Trabzon, Turkey) monofilament uninterrupted sutures. No wound dressing or casting was used after the operations. All rats were allowed to mobilize freely and were fed with standard laboratory food and tap water. Rats were euthanized with an overdose of ketamine hydrochloride 21 days following the tenotomy. After that, the Achilles tendons were dissected and harvested for histological examination.

Histological analyses were performed by an experienced pathologist who was blinded to the study conditions. A buffered formalin solution was used for fixation of the specimens, and the tendons were embedded in paraffin. Five longitudinal serial sections, each 5 mm thick, were taken from the injured site's "core area" of each tendon. Hematoxylin and Eosin (H-E) and Alcian blue staining were performed (Figure 2-5). The samples were scored according to Bonar histological grading scale. This classification includes the tenocyte morphology, tenocyte proliferation, collagen bundle characteristics, neovascularization, and the presence or absence of ground substance parameters

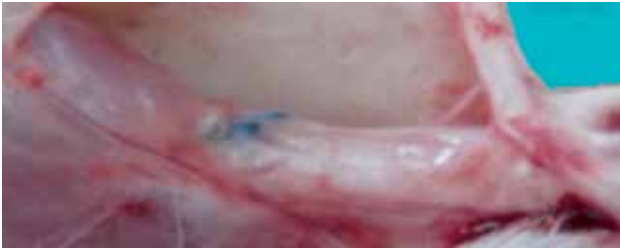

Figure 1. Achilles tendon was repaired with 4/0 polypropylene suture using a modified Kessler-type technique.

(Table I).^[17,18] According to this scale, higher scores indicate poorer tendon healing.

Statistical analysis

The Mann-Whitney U test was used to evaluate the differences between the two groups (study and control). A p value <0.05 was considered to be statistically significant.

RESULTS

After the scarifications, macroscopically all the Achilles tendons were fully healed. Total mean Bonar score was higher in the study group ($p=0.001$). When the parameters of the Bonar score were analyzed separately, only the collagen morphology revealed significantly superior results in the control group compared to the study group (0.001). The other parameters including tenocyte morphology, ground substance, and vascularity did not show any significant difference between the two groups.

Results of Bonar histological grading scale are presented in Table II. The collagen variables scores and total mean Bonar sum-scores revealed significantly superior results in the control group compared to the study group ($p=0.001$ and $p=0.001$), respectively.

DISCUSSION

This study suggests that topical ABS application during tendon repair surgery might affect the healing process negatively in an animal model. To our knowledge, no studies have been reported about the histological effects of ABS on tendon healing.

Among four main parameters used for histological analyses, results showed significant difference in terms of collagen morphology. However, this difference also affected total Bonar score. As ABS is a novel hemostatic agent, this difference may be secondary to its limiting effect on hemorrhage. Inflammation, repair, and remodeling are the main phases of tendon healing.

Tendon and soft tissue injuries constitute an important part of orthopedic and plastic surgeons' daily working activities. Surgical repair of ruptured tendons needs a proper visualization of the injured tendons and the surgical site. For proper suturing, surgeons' comfort, particularly avoiding bleeding of the surgical site, should be managed. When methods such as compression, suture, electrocautery, and tourniquets are not effective or cannot be

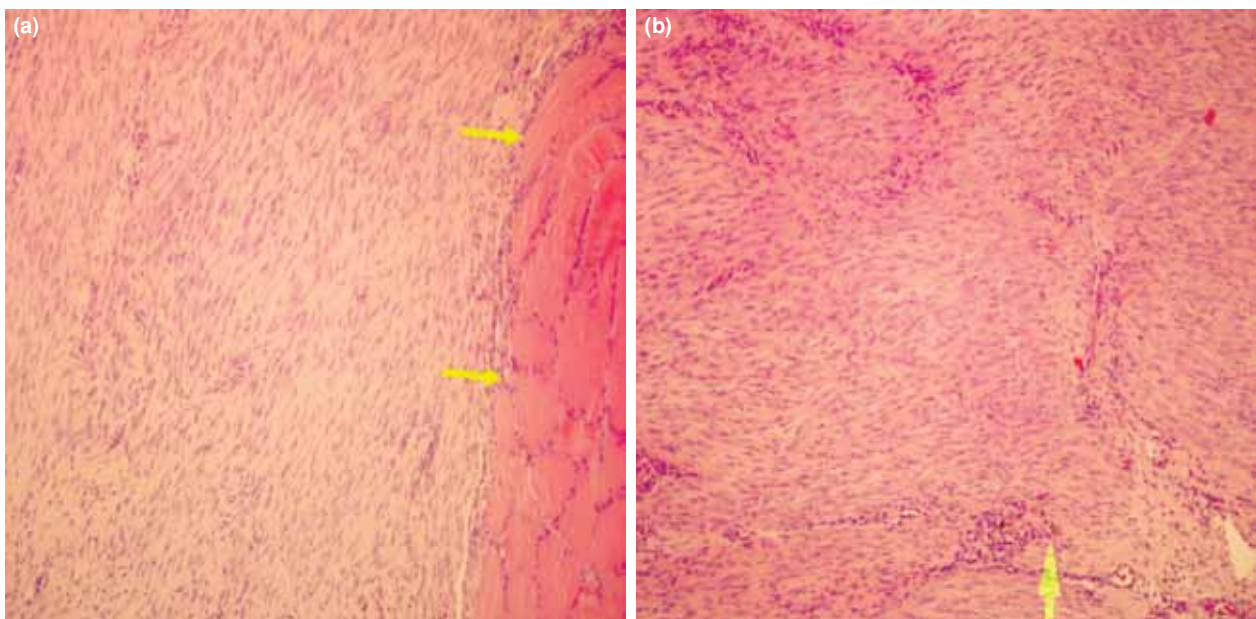


Figure 2. (a) Microscopic view of control group with well-arranged bundles and muscle cells at left side (two arrows). (b) Microscopic view of study group with hemosiderin-loaded macrophages (arrow) and diminished cell organizations. (H-E $\times 100$).

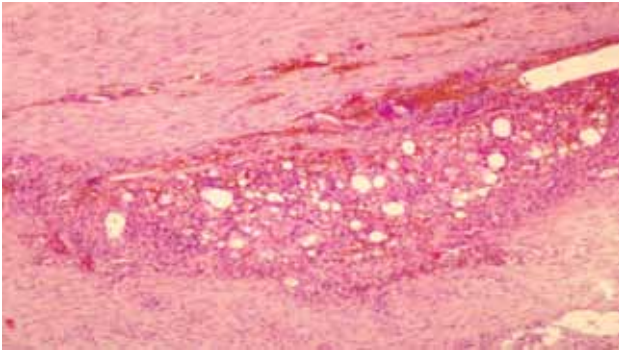


Figure 3. Fewer foreign body type giant cells and plenty hemosiderin pigments in an Ankaferd Blood Stopper® applied rat tendon injury (H-E x 100).

performed for hemostasis in primary wound care, a hemostatic agent can be helpful. Hemostatics prevent hemorrhage, decrease the use of systemic coagulants, help reducing surgical time, and contribute to a patient's quick recovery.

Ankaferd Blood Stopper® has been used to stop hemorrhage in various kinds of injuries, such as those on skin surfaces, abdominal lacerations or during dental procedures.^[3,7] Ankaferd Blood Stopper® is a standardized extract from the following plants: *Glycyrrhiza glabra*, *Vitis vinifera*, *Alpinia officinarum*, *Urtica dioica*, and *Thymus vulgaris* in a weight ratio of 9: 8: 7: 6: 5, respectively.^[19,20] *Alpinia officinarum* has an inhibitory effect on nitric oxide production by lipopolysaccharide-activated mouse peritoneal macrophages.^[21] *Urtica dioica* acts as a vasodilator via stimulating nitric oxide production by the endothelium.^[22] *Glycyrrhiza glabra* inhibits angiogenesis and decreases vascular endothelial growth factor production and cytokine-induced neovascularization by its anti-inflammatory, anti-thrombin, anti-platelet, anti-oxidant, anti-atherosclerotic, and anti-tumor activities.^[23] *Thymus*

vulgaris has anti-oxidative effects,^[24] and *Vitis vinifera* has anti-tumor and anti-atherosclerotic effects.^[25,26] The action mechanism of ABS maintains the formation of an encapsulated protein network,^[19] and this ABS-induced protein network formation involves the erythrocytes in particular.^[19]

Hemostatic efficacy of ABS was reported in multiple studies. In a study, the tail tip bleeding model was used to assess *in vivo* effect of ABS, which shortened hemostasis time and reduced amount of bleeding.^[27] Kose et al.^[28] studied skin bleeding in an animal model using rats. They demonstrated that ABS is an effective agent to shorten bleeding time and amount of bleeding also with heparin treatment. The hemostatic effects of ABS were reported in detail in different studies.^[6,10,19] Main action mechanism is the formation of an encapsulated protein network that provides focal points for erythrocyte aggregation.^[19]

Tendon healing occurs in three overlapping phases. Any problems during these stages may lead to delay or failure of the healing process. The first phase is the inflammatory phase during which the erythrocytes and inflammatory cells accumulate at the site of injury. This phase takes approximately 24 hours. During this period, phagocytosis of necrotic materials occurs by the monocytes and the macrophages. The second phase is the repair phase during which the vasoactive and chemotactic factors are released with increased vascular permeability. The start of angiogenesis and tenocyte proliferation, and accumulation of more inflammatory cells take place during this second phase. Also, tenocytes begin to migrate to the wound, and type III collagen synthesis is started. A few days later, the remodeling phase begins as the synthesis of type III collagen peaks, which lasts for a few weeks. During the remodeling stage, the healing tissue is resized and reshaped with the decrease in cellularity and

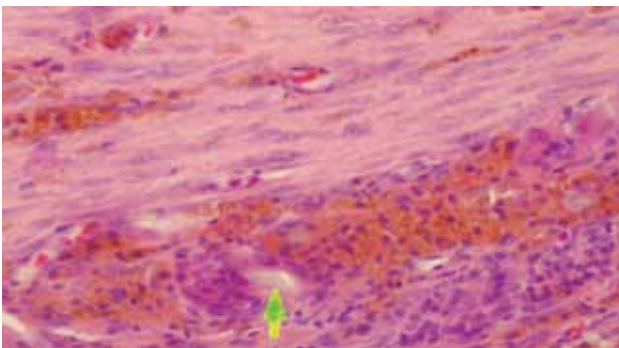


Figure 4. Large amounts of hemosiderin pigment deposition and foreign body type giant cells (arrow) in an Ankaferd Blood Stopper® applied tendon healing section (H-E x 400).

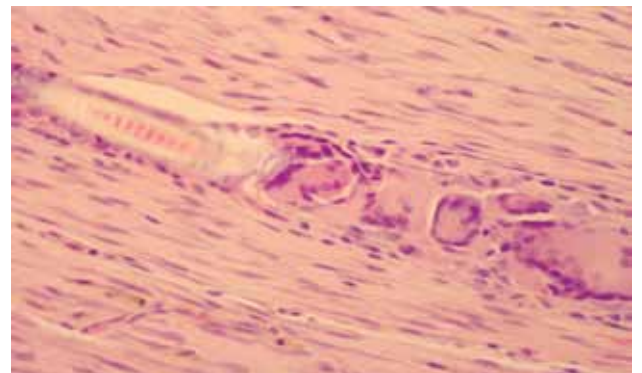


Figure 5. Foreign body type giant cells in section of isotonic NaCl applied rat tendon healing model (H-E x 400).

TABLE I
Bonar histological grading scale

Variables	Grade 0	Grade 1	Grade 2	Grade 3
Tenocytes	Inconspicuous elongated spindle-shaped nuclei with no obvious cytoplasm upon light microscopy	Increased roundness: nucleus becomes more ovoid to round in shape without conspicuous cytoplasm	Increased roundness and size: nucleus is round, slightly enlarged and a small amount of cytoplasm is visible	Nucleus is round, large with abundant cytoplasm and lacuna formation (chondroid change)
Ground substance	No stainable ground substance	Stainable mucin between fibers but bundles still discrete	Stainable mucin between fibers with loss of clear demarcation of bundles	Abundant mucin throughout with inconspicuous collagen staining
Collagen	Collagen arranged in tightly cohesive well-demarcated bundles with a smooth dense bright homogeneous polarization pattern with normal crimping	Diminished fibers polarization: separation of individual fibers with maintenance of demarcated bundles	Bundle changes: separation of fibers with loss of demarcation of bundles giving rise to expansion of the tissue overall and clear loss of normal polarization pattern	Marked separation of fibers with complete loss of architecture
Vascularity	Inconspicuous blood vessels coursing between bundles	Occasional cluster of capillaries, less than one per 10 high power fields	1-2 clusters of capillaries per 10 high power fields	Greater than two clusters per 10 high power fields

also the collagen and glycosaminoglycan synthesis occurs.^[1]

According to our results, ABS has negative effect on tendon healing. Up to date, no study was reported about the effects of ABS on tendon healing. But similar studies about the effect of ABS on dermal wound injuries were performed. Most of these studies showed negative or ineffective effect on healing process similarly to our study results. In a study, Yüce et al.^[29] used experimental skin incision model in rabbits. They reported that ABS has negative effect on wound healing in the early periods while it has no negative effect on healing in the late periods. They concluded that ABS does not exert any negative effects on wound healing as it is a secure and effective method for achieving hemostasis. In another study on fibroblast culture model, three hemostatic agents (ABS, fibrin glue, tranexamic acid) were compared in terms of their effects on healing. This study showed that all three hemostatic agents have negative effects on fibroblasts, with ABS having the lowest values of cell proliferation, cell number, and cell viability.^[30] Also, the efficacy of ABS on healing of dermal wounds was studied in a rat model, which revealed that ABS has positive effects on wound healing and wound contraction percentage. But the time period

for histological examination was 14 days and the contraction percentages were studied on 3rd, 7th, 10th and 14th days. To our knowledge, this is the only study reporting ABS having a positive effect on wound healing.^[31]

The effects of ABS on different tissues and healing has been studied previously.^[5,6,10] Okumuş et al.^[5] investigated the basic histopathological changes under a light microscope in deep tissue injuries as well as remote organs such as brain, heart, kidney, and liver, when ABS was applied on the punctured femoral vein region in rats. They reported that ABS did not lead to any degeneration of regional tissue and systemic tissues. In the present study, there was

TABLE II
Histological results according to Bonar histological grading scale

Parameter	Mean score		p
	Right (ABS)	Left (Control)	
Tenocytes	0.00	0.583	0.071
Ground substance	2.91	2.91	
Collagen	0.91	0.00	0.001*
Vascularity	2.00	2.16	0.480
Total sum score	6.58	4.91	0.001*

ABS: Ankaferd Blood Stopper®.

no negative effect on tendon healing to the left side when ABS was applied to the right side; however, the negative effects on the collagen organization parameter were detected only in the right side. This suggests that ABS has no systemic negative effects on wound healing.

The effects of ABS on bone tissue were also studied in different animal model studies. İşler et al.^[9] studied the effects of ABS on bone healing in rats. They reported that ABS has positive effects on early bone healing, as well as negative effects on inflammation and necrosis process, which are associated with antioxidant effects of ABS. They also reported that bone defects treated with ABS were free of inflammation, which is probably related to the anti-inflammatory activity of ABS. Şimşek et al.^[32] also studied on rat femoral defect models for the effects of ABS on bone defects. They concluded that ABS has an acceleratory effect on short-term bone healing process; however, its effect on long-term bone healing process is insignificant. In another study which was performed to evaluate radiologic results and serum changes of oxidative stress markers during fracture healing process with and without ABS application to bone fracture, it was shown that ABS was ineffective on fracture healing in early healing period except for bleeding control.^[33]

Cancan et al.^[7] studied the effects of ABS on colonic anastomosis. They showed that ABS may support anastomotic healing in septic conditions. Also, the topical ABS application controlling the mucosal bleeding at the cut ends of the colon may also improve the anastomotic wound healing by positively affecting the angiogenesis.

As inflammation is an indispensable stage for successful wound healing, over inflammation may lead to impaired wound healing due to increased collagenolysis and delayed reepithelization.^[7] Theoretically, anti-inflammatory effect of ABS may inhibit collagenolysis. According to our study, ABS has a significantly negative effect on collagen bundle organization and the total Bonar score. These results may be secondary to the anti-inflammatory effect of ABS. Our study showed that ABS decreases collagen bundle organization, which is one of the indicators of the healing process. However, Cancan et al.^[7] showed that topical ABS improves collagen production, and may support anastomotic healing in septic conditions in rats. These opposite results may be secondary to the different aseptic surgical and aseptic healing conditions that exist between the studies.

There are some limitations of our study. First, there is the lack of biomechanical analyses. Although histological evaluation is important for tendon healing process, biomechanical test results are also important for the evaluation of tendon repairs as the primary functions of tendons are to transfer loads and enable movement of the extremities. A second limitation of this study is the euthanization time. All of the rats were sacrificed at 21 days following tenotomy, and the time period of three weeks is adequate for Achilles tendon healing in rats. But in some studies, tendon healing process has been studied for as long as six weeks in rats.^[1] With this present study, the stage at which the ABS affects the healing process is unclear. The euthanization time may be longer or may be studied with three-week and a six-week time periods with more animals. Early and late effects of ABS on tendon healing process may be better studied by using more animal groups. The last limitation of this study is about the histological examination. One of the popular topics about healing studies is to test the amount of hydroxyproline in repair tissues. As hydroxyproline is a marker of collagen, which means better healing tissue, immunohistochemical investigations to measure the amount of collagen may be added for proper histological results. We were unable to investigate this parameter due to the high cost of immunohistochemical agents.

In conclusion, ABS may affect collagen fiber bundle organization negatively, which results in the inhibition of the entire tendon healing process. Further studies including biomechanical and immunohistochemical analysis are needed to investigate the effects of ABS application on tendon healing.

Declaration of conflicting interests

The authors declared no conflicts of interest with respect to the authorship and/or publication of this article.

Funding

The authors received no financial support for the research and/or authorship of this article.

REFERENCES

1. Akamatsu FE, Saleh SO, Teodoro WR, Silva AQ, Martinez CA, Duarte RJ, et al. Experimental model of Achilles tendon injury in rats. *Acta Cir Bras* 2014;29:417-22.
2. Atik OS, Bölükbaşı S, Kanatlı U. Does surgical repair of acute Achilles tendon rupture cause structural changes on 15-year follow-up? *Eklem Hastalik Cerrahisi* 2011;22:54-5.
3. Kozen BG, Kircher SJ, Henao J, Godinez FS, Johnson AS. An alternative hemostatic dressing: comparison of CELOX,

- HemCon, and QuikClot. *Acad Emerg Med* 2008;15:74-81.
4. Wedmore I, McManus JG, Pusateri AE, Holcomb JB. A special report on the chitosan-based hemostatic dressing: experience in current combat operations. *J Trauma* 2006;60:655-8.
 5. Okumuş M, Yüksel KZ, Özbağ D, Çıralık H, Yılmaz Z, Gümüştalan Y, et al. Medicinal plant extract (Ankaferd Blood Stopper) application in deep tissue injuries in rats: histopathological investigation of the effect on regional and systemic tissues. *Ulus Travma Acil Cerrahi Derg* 2013;19:1-7.
 6. Haznedaroglu BZ, Haznedaroglu IC, Walker SL, Bilgili H, Goker H, Kosar A, et al. Ultrastructural and morphological analyses of the in vitro and in vivo hemostatic effects of Ankaferd Blood Stopper. *Clin Appl Thromb Hemost* 2010;16:446-53.
 7. Cancan G, Teksoz S, Aytac E, Arıkan AE, Erman H, Uzun H, et al. Effects of Ankaferd on anastomotic healing of colon. *J Invest Surg* 2014;27:1-6.
 8. Akkoç N, Akçelik M, Haznedaroglu I, Göker H, Aksu S, Kirazlı Ş, et al. In vitro antibacterial activities of Ankaferd Blood Stopper. *Int J Lab Hematol* 2008;30(Suppl 1):1-14.
 9. İşler SC, Demircan S, Cakarar S, Cebi Z, Keskin C, Soluk M, et al. Effects of folk medicinal plant extract Ankaferd Blood Stopper on early bone healing. *J Appl Oral Sci* 2010;18:409-14.
 10. Haznedaroglu BZ, Beyazit Y, Walker SL, Haznedaroglu IC. Pleiotropic cellular, hemostatic, and biological actions of Ankaferd hemostat. *Crit Rev Oncol Hematol* 2012;83:21-34.
 11. Teker AM, Korkut AY, Gedikli O, Kahya V. Prospective, controlled clinical trial of Ankaferd Blood Stopper in children undergoing tonsillectomy. *Int J Pediatr Otorhinolaryngol* 2009;73:1742-5.
 12. Kurt M, Kacar S, Onal IK, Akdogan M, Haznedaroglu IC. Ankaferd Blood Stopper as an effective adjunctive hemostatic agent for the management of life-threatening arterial bleeding of the digestive tract. *Endoscopy* 2008;40:E262.
 13. Kilic O, Gonen M, Acar K, Yurdakul T, Avunduk MC, Esen HH, et al. Haemostatic role and histopathological effects of a new haemostatic agent in a rat bladder haemorrhage model: an experimental trial. *BJU Int* 2010;105:1722-5.
 14. Murrell GA, Lilly EG, Collins A, Seaber AV, Goldner RD, Best TM. Achilles tendon injuries: a comparison of surgical repair versus no repair in a rat model. *Foot Ankle* 1993;14:400-6.
 15. Majewski M, Betz O, Ochsner PE, Liu F, Porter RM, Evans CH. Ex vivo adenoviral transfer of bone morphogenetic protein 12 (BMP-12) cDNA improves Achilles tendon healing in a rat model. *Gene Ther* 2008;15:1139-46.
 16. Ozer H, Taşkesen A, Kul O, Selek HY, Turanlı S, Köse K. Effect of glucosamine chondroitine sulphate on repaired tenotomized rat Achilles tendons. *Eklemler Hastalıkları Cerrahisi* 2011;22:100-6.
 17. Cook JL, Feller JA, Bonar SF, Khan KM. J Abnormal tenocyte morphology is more prevalent than collagen disruption in asymptomatic athletes' patellar tendons. *Orthop Res* 2004;22:334-8.
 18. Maffulli N, Longo UG, Franceschi F, Rabitti C, Denaro V. Movin and Bonar scores assess the same characteristics of tendon histology. *Clin Orthop Relat Res* 2008;466:1605-11.
 19. Goker H, Haznedaroglu IC, Ercetin S, Kirazlı S, Akman U, Ozturk Y, et al. Haemostatic actions of the folkloric medicinal plant extract Ankaferd Blood Stopper. *J Int Med Res* 2008;36:163-70.
 20. Ankaferd web site. Available at: <http://www.ankaferd.com/eng/abs-formul.php> Accessed March 20, 2010.
 21. Matsuda H, Ando S, Kato T, Morikawa T, Yoshikawa M. Inhibitors from the rhizomes of *Alpinia officinarum* on production of nitric oxide in lipopolysaccharide-activated macrophages and the structural requirements of diarylheptanoids for the activity. *Bioorg Med Chem* 2006;14:138-42.
 22. Testai L, Chericoni S, Calderone V, Nencioni G, Nieri P, Morelli I, et al. Cardiovascular effects of *Urtica dioica* L. (Urticaceae) roots extracts: in vitro and in vivo pharmacological studies. *J Ethnopharmacol* 2002;81:105-9.
 23. Sheela ML, Ramakrishna MK, Salimath BP. Angiogenic and proliferative effects of the cytokine VEGF in Ehrlich ascites tumor cells is inhibited by *Glycyrrhiza glabra*. *Int Immunopharmacol* 2006;6:494-8.
 24. Lee SJ, Umamo K, Shibamoto T, Lee KG. Identification of volatile components in basil (*Ocimum basilicum* L.) and thyme leaves (*Thymus vulgaris* L.) and their antioxidant properties. *Food Chem* 2005;91:131-7.
 25. Zhao J, Wang J, Chen Y, Agarwal R. Anti-tumor-promoting activity of a polyphenolic fraction isolated from grape seeds in the mouse skin two-stage initiation-promotion protocol and identification of procyanidin B5-3'-gallate as the most effective antioxidant constituent. *Carcinogenesis* 1999;20:1737-45.
 26. Yamakoshi J, Kataoka S, Koga T, Ariga T. Proanthocyanidin-rich extract from grape seeds attenuates the development of aortic atherosclerosis in cholesterol-fed rabbits. *Atherosclerosis* 1999;142:139-49.
 27. Sogut O, Erdogan MO, Kose R, Boleken ME, Kaya H, Gokdemir MT, et al. Hemostatic Efficacy of a Traditional Medicinal Plant Extract (Ankaferd Blood Stopper) in Bleeding Control. *Clin Appl Thromb Hemost* 2013 Sep 19. [Epub ahead of print]
 28. Kose R, Sogut O, Demir T, Koruk I. Hemostatic efficacy of folkloric medicinal plant extract in a rat skin bleeding model. *Dermatol Surg* 2012;38:760-6.
 29. Yüce S, Çandırılı C, Yenidünya S, Muslu B. New hemostatic agent: the effect of Ankaferd Blood Stopper on healing wounds in experimental skin incision model. *Turk J Med Sci* 2014;44:288-94.
 30. Emes Y, Aybar B, Vural P, İşsever H, Yalçın S, Atalay B, et al. Effects of hemostatic agents on fibroblast cells. *Implant Dent* 2014;23:641-7.
 31. Akalin C, Kuru S, Barlas AM, Kismet K, Kaptanoglu B, Demir A, et al. Beneficial effects of Ankaferd Blood Stopper on dermal wound healing: an experimental study. *Int Wound J* 2014;11:64-8.
 32. Simşek HO, Tüzüm MŞ, Baykul T, Güreler IE, Başsorgun Cİ. Experimental investigation of the effects of a blood stopper agent (ankaferd blood stopper) on bone surfaces. *Turk J Haematol* 2013;30:177-83.
 33. Amanvermez R, Gunay M, Piskin A, Keles G, Tomak L. TNF- α , IL-1 β , and oxidative stress during fracture healing with or without ankaferd. *Bratisl Lek Listy* 2013;114:621-4.