





The efficiency of ozone therapy in the prevention of heterotopic bone formation in an animal model

Özgür Doğan Aydın, MD¹, Tayfun Bacaksız, MD², İhsan Akan, MD², Aysu Hayriye Tezcan, MD³,
Tuğrul Bulut, MD², Cemal Kazımoglu, MD²

¹Department of Orthopedics and Traumatology, İzmir City Hospital, İzmir, Türkiye

²Department of Orthopedics and Traumatology, İzmir Katip Çelebi University, İzmir, Türkiye

³Department of Anesthesiology and Reanimation, İzmir Atatürk Training and Research Hospital, İzmir, Türkiye

Heterotopic ossification (HO) is a recognized medical disorder characterized by the development of bone in the soft tissues and it is a complex issue which can significantly restrict the range of motion in a joint.^[1,2] The only viable solution for acquired HO is surgical excision. Consequently, there is significant interest in the prevention of HO through prophylaxis. Currently, non-steroidal anti-inflammatory drugs (NSAIDs) and radiation therapy are widely regarded as the most effective methods for preventing HO.^[3]

The occurrence of HO is initiated by local inflammation resulting from trauma and surgical procedures, which activates intricate biological mechanisms. The conversion of nearby fibroblasts into pluripotent mesenchymal cells and osteoblasts resulted in increased osteoblastic

Received: January 25, 2025

Accepted: April 12, 2025

Published online: May 02, 2025

Correspondence: Özgür Doğan Aydın, MD. İzmir Şehir Hastanesi, Ortopedi ve Travmatoloji Kliniği, 35540 Bayraklı, İzmir, Türkiye.

E-mail: aydinozgurdogan@gmail.com

Doi: 10.52312/jdrs.2025.2174

Citation: Aydın ÖD, Bacaksız T, Akan İ, Tezcan AH, Bulut T, Kazımoglu C. The efficiency of ozone therapy in the prevention of heterotopic bone formation in an animal model. Jt Dis Relat Surg 2025;36(3):1-10. doi: 10.52312/jdrs.2025.2174.

©2025 All right reserved by the Turkish Joint Diseases Foundation

This is an open access article under the terms of the Creative Commons Attribution-NonCommercial License, which permits use, distribution and reproduction in any medium, provided the original work is properly cited and is not used for commercial purposes (<http://creativecommons.org/licenses/by-nc/4.0/>).

ABSTRACT

Objectives: In our study, we aimed to evaluate the efficacy of prophylactic ozone therapy (OT) for heterotopic ossification (HO) development after hip surgery in a rat model.

Materials and methods: We randomly divided a total of 20 Wistar albino rats into two equal groups (n=10) as the control group (Group 1) receiving daily intraperitoneal injections of 1 mL of Ringer's lactate solution for a duration of two weeks after undergoing hip surgery and the group (Group 2) receiving OT daily at a dose of 1 mL of an ozone/oxygen combination via intraperitoneal route for a period of two weeks after hip surgery. Hip surgery was performed to mimic the formation of HO. After 12 weeks, the animals were evaluated functionally and sacrificed. Following sacrifice, histopathological, and radiological assessments were performed.

Results: The modified Brooker staging method was used for radiological evaluation, and all animals in the control group showed at least Stage 1 HO formation. However, only three animals (30%) in the OT group showed HO formation (p=0.006). In histopathological evaluation, the median HO rates in the high-power field were 42.5 (range, 30 to 55) in the control group and 0 (range, 0 to 25) in the OT group (p=0.003), and the median leukocyte count was 5.5 (range, 3 to 7) in the control group and 1 (range, 0 to 3) in the ozone group (p=0.006). Radiological HO, histopathological HO, and inflammation were significantly lower in the ozone group (p<0.05).

Conclusion: Our study results suggest that OT is effective in decreasing HO formation in rats following hip surgery.

Keywords: Heterotopic ossification, hip surgery, ozone therapy.

activity. Endochondral ossification is the main process responsible for the formation of traumatic HO. Proinflammatory substances, such as interleukin (IL)-1, prostaglandin E1 (PGE1), and E2 (PGE2), accelerate the process that includes bone morphogenic protein (BMP).^[3,4] Hence, the suppression of proinflammatory factors is essential

in the prevention of HO. Selective COX-2 inhibitors and standard NSAIDs are frequently utilized in daily practice to disrupt this intricate inflammatory cascade.

The method of drug administration is critical in influencing therapeutic outcomes. To illustrate, intraperitoneal (IP) administration has been shown to be as effective as intravenous (IV) administration, as it allows for systemic absorption through the peritoneal membranes, thereby enabling comparable therapeutic effects.^[5,6] The impact of ozone therapy (OT) on human physiology through oxidative preconditioning has been extensively studied.^[7] Ozone therapy has gained popularity as a treatment for various extra-skeletal diseases, as it influences the nuclear factor-kappa B (NF-κB)/nuclear factor erythroid 2-related factor 2 (Nrf2) pathways and the cytokines IL-6 and IL-1β, which may be advantageous

in addressing several disorders, including novel coronavirus disease 2019 (COVID-19).^[8-11]

In the present study, we hypothesized that OT could hinder the development of HO by altering the microenvironment, as it could reduce the inflammatory process associated with traumatic HO generation through its anti-inflammatory properties (Figure 1). We, therefore, aimed to examine the efficacy of prophylactic ozone therapy for HO development after hip surgery in a rat model.

MATERIALS AND METHODS

The study included a total of 20 Wistar albino rats, with each rat weighing between 400 and 500 g. The rats were provided with rat chow and water freely, without restriction. The rats were kept in a controlled environment with a 12-h light/dark cycle.^[12] All animals received equal humane care.

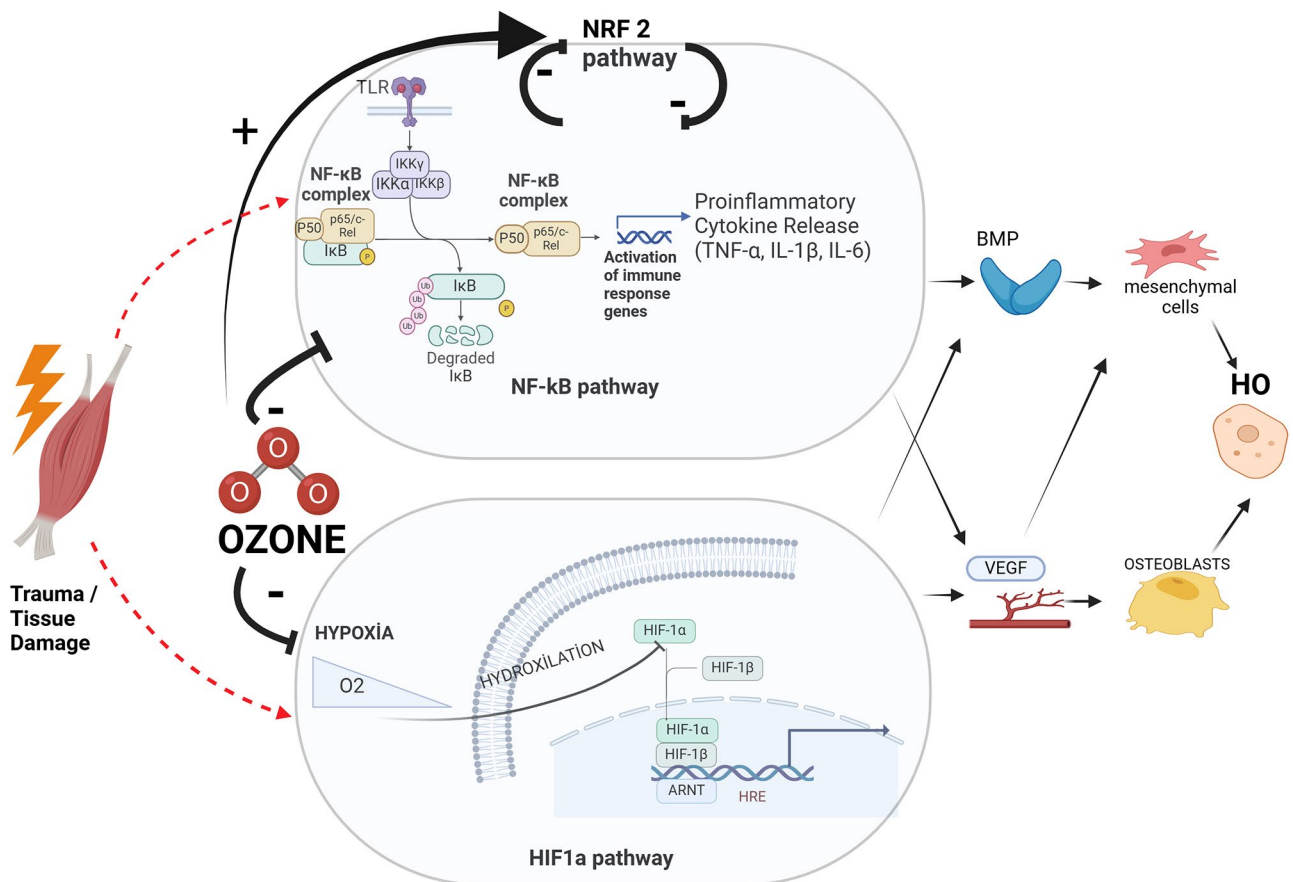


FIGURE 1. Demonstration of the mechanism of heterotopic ossification and our hypothesis that ozone inhibits this mechanism by regulating different pathways. HO: Heterotopic ossification; VEGF: Vascular endothelial growth factor; BMP: Bone morphogenetic protein; Nrf2: Nuclear factor erythroid 2-related factor 2; TLR: Toll-like receptors; NF-κB: Nuclear factor-kappa B; TNF-α: Tumor necrosis factor alpha; IL: Interleukin; HIF1α: Hypoxia-inducible factor 1-alpha; ARNT: Aryl hydrocarbon receptor nuclear translocator; HRE: Hypoxia response element; BMP: Bone morphogenetic protein; VEGF: Vascular endothelial growth factor. (Created in BioRender, (2025) <https://BioRender.com/cxy7kyj>).

The study protocol was approved by the Dokuz Eylül University Animal Experiments Local Ethics Committee (date: 06.06.2022, IRB: 17/2022).

We conducted a random allocation of the animals into two equal groups (n=10): (i) The control group (Group 1) was administered daily IP injections of 1 mL of Ringer's lactate solution for a duration of two weeks after undergoing hip surgery; (ii) The group (Group 2) receiving OT was given a daily dose of 1 mL of an ozone/oxygen combination via IP route for a period of two weeks after hip surgery. The mixture contained 30 $\mu\text{g}/\text{mL}$ of ozone.^[13-15] The inflammatory phase, which is crucial in the development of HO, occurs during this process, which is the primary reason that ozone was applied for two weeks beginning in the early postoperative period in the present study. In addition, OT was applied for 10 to 14 days in well-designed rat studies to utilize the anti-inflammatory effect of ozone, and successful results were reported.^[16-18]

The animals exhibited no indications of postoperative complications. The primary criteria for exclusion were experiencing early death and surgical failure. No early death or surgical failure was observed in our study. After 12 weeks of follow-up, a functional assessment was performed, and the animals were subsequently euthanized by carbon dioxide (CO_2) inhalation. The site containing the pelvis and bilateral proximal femurs was resected and removed together with the surrounding soft tissue. Radiological and histopathological evaluation were performed.

Surgical procedures

All surgical procedures were conducted under general anesthesia using a sterile method. We administered 100 mg/kg of ketamine (Ketalar®; Pfizer Türkiye, İstanbul, Türkiye), and 10 mg/kg of xylazine (XYLASED®; Bioveta, Czech Republic) via IP route.

We performed a 3-cm skin incision on the greater trochanter, which extended down to the bone and resulted in dissection along the muscle fiber line. We performed a surgical procedure to expose the great trochanter and then used a 2-mm Kirschner wire (K-wire) to drill the bone deep into the medullary cavity. We carried out this procedure to facilitate the access of pluripotent mesenchymal stem cells (Figure 2). Subsequently, muscle damage was carried out to replicate the comprehensive hip surgery as described by Anthonissen et al.^[19]

Radiographic evaluation

We utilized a micro-computed tomography (CT) device (Micro-CT 50; Scanco Medical AG, Switzerland) to examine hip samples stored in a formaldehyde solution. We conducted three-dimensional (3D) modeling of the sample photos (Figure 3).

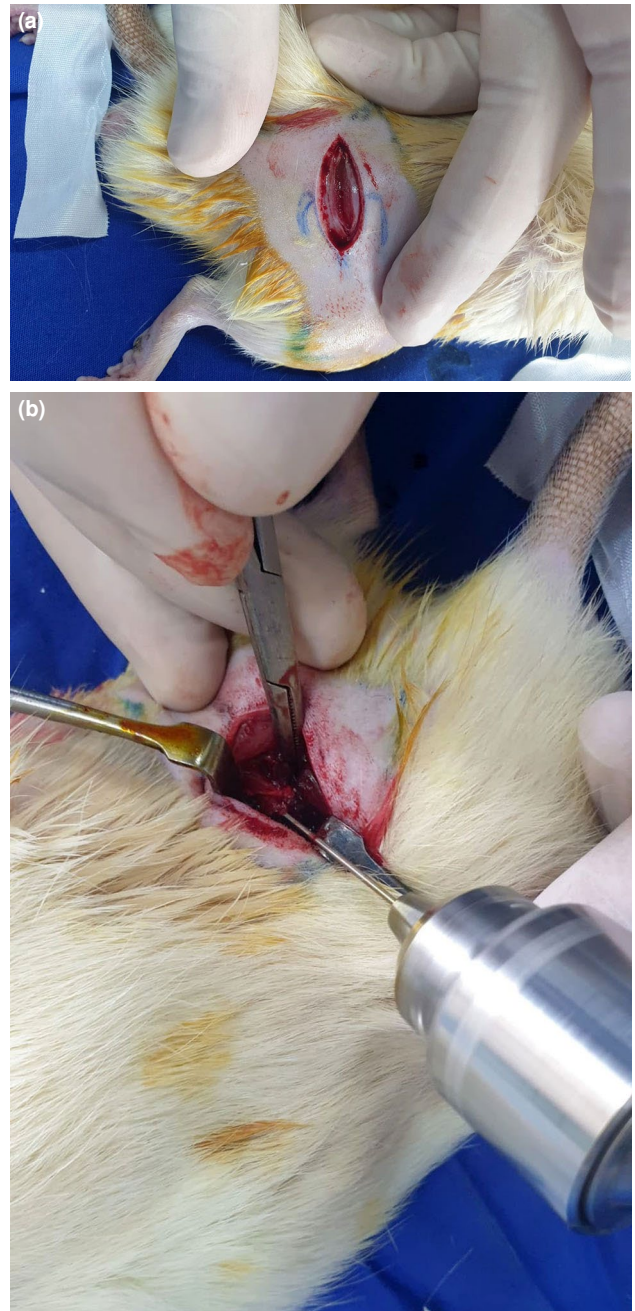
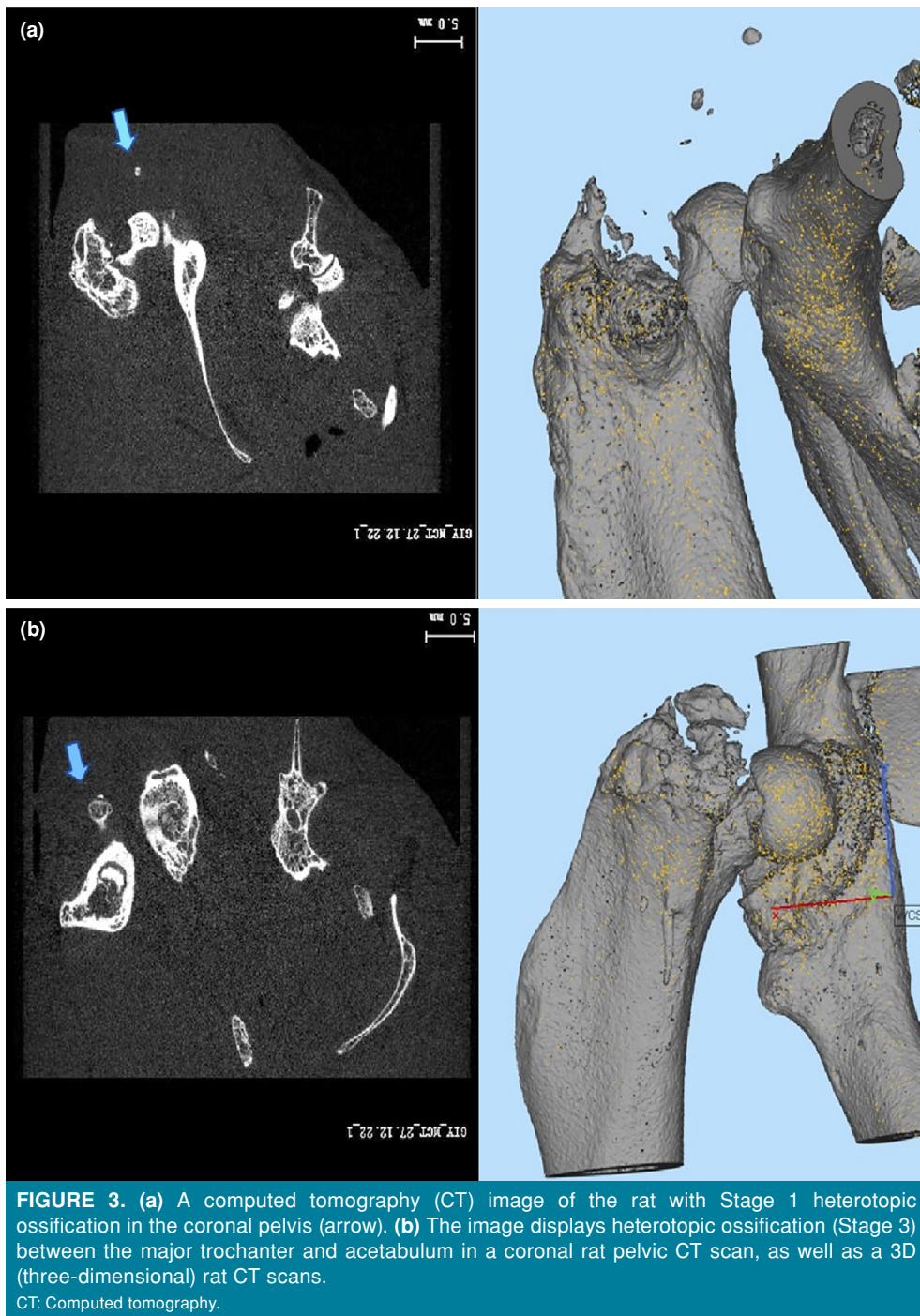


FIGURE 2. (a) Intraoperative image showing blunt dissection of the gluteal muscles after the skin incision. (b) Exposure to the greater trochanter and drilling procedure.



We assessed the presence of HO in animal models using the modified Brooker grading system, as described by Anthonissen et al.^[19] Two orthopedic specialists examined all photos to ascertain the existence and progression of HO, and a musculoskeletal radiologist with 25 years of expertise in radiography confirmed these findings. Any dispute or disagreement was settled by reaching a consensus.

Histopathological assessment

We collected sample slices by sacrificing the femoral head along the reference sagittal line. The samples were immersed in a 4% paraformaldehyde solution at a temperature of 4°C for a duration of 48 h. Subsequently, they were subjected to decalcification using a 7% formic acid solution. After the process of decalcification, we placed the

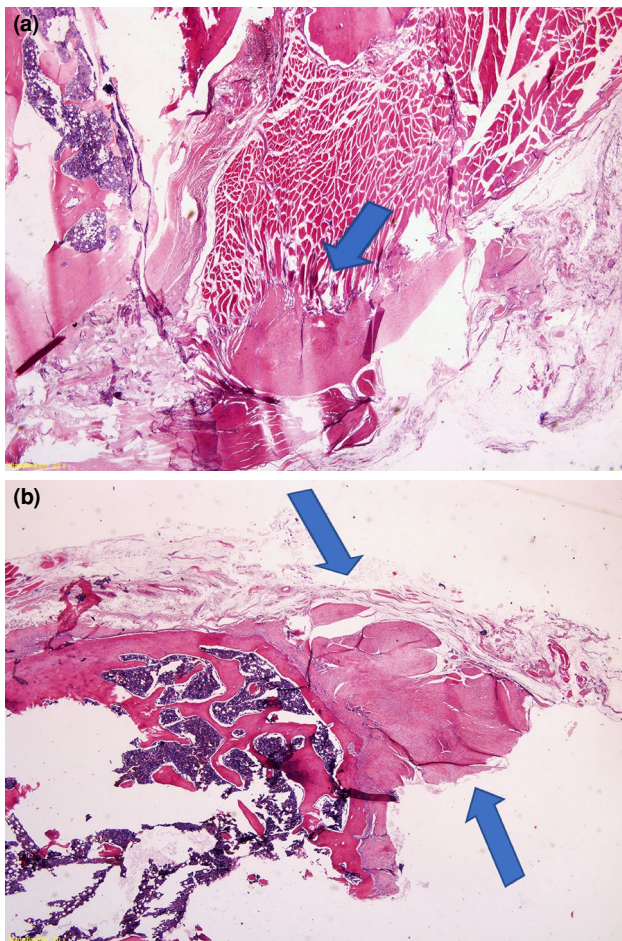


FIGURE 4. (a) The image shows heterotopic ossification (Stage 1), with hematoxylin and eosin (H&E) at 2× magnification (arrow). (b) Stage 2 heterotopic ossification observed at 2× magnification (arrows).

samples in a paraffin block and sliced them into slices that were 7 μm in thickness. We applied hematoxylin and eosin (H&E) and Masson's trichrome dye to the sections to create stains. Heterotopic ossification was characterized as the process of forming new bone in soft tissues (Figure 4).

All histopathological assessments were conducted by blinded observers using coded samples to ensure that the evaluators were unaware of the group allocation. Both a musculoskeletal pathologist with two decades of expertise and an orthopedist examined all samples to determine the existence and stage of HO, as well as the inflammatory response. Any dispute or disagreement was settled by reaching a consensus. We conducted the histological assessment by examining the maximum level of magnification under the microscope. We considered the density of cells in the region where inflammatory alterations were most apparent, as well as the proportion of the area where osseous tissue was visible. We assessed the extent of inflammatory infiltration by counting the number of leukocytes in the high-power field (HPF) of the microscope with the greatest cellular density. After applying H&E and Masson's trichrome stains to the hip samples, we assessed the extent of HO by quantifying the area of the most prominently seen region under the highest magnification in the microscope field. Histopathological evaluations were carried out numerically in terms of leukocyte count and HO ratio in the HPF area. Thereafter, data were categorized and evaluated according to the grading system used by Ohlmeier et al.^[20] (Table I).

Functional assessment

We employed hindpaw prints specifically for the purpose of functional assessment, following the methodology as described by de Medinaceli et al.^[21] The animals were encouraged to walk along a narrow pathway that was enclosed, with a dimly lit refuge at the far end. We immersed the hindpaws in various hues of ink and permitted them to traverse a walking track coated with white copier paper. The functional assessments were done preoperatively and postoperatively at 12 weeks.

TABLE I
Histopathological staging

| Stage | Heterotopic ossification | Inflammatory infiltration |
|-------|---|---------------------------------|
| 0 | No heterotopic ossification | No leukocytes |
| 1 | The bone formation area was less than one-third of the evaluated area. | Less than 5 leukocytes/HPF |
| 2 | The bone formation area was between one-third and two-thirds of the evaluated area. | Between 5 and 10 leukocytes/HPF |
| 3 | The bone formation area was over two-thirds of the evaluated area. | More than 10 leukocytes/HPF |

HPF: High-power field.

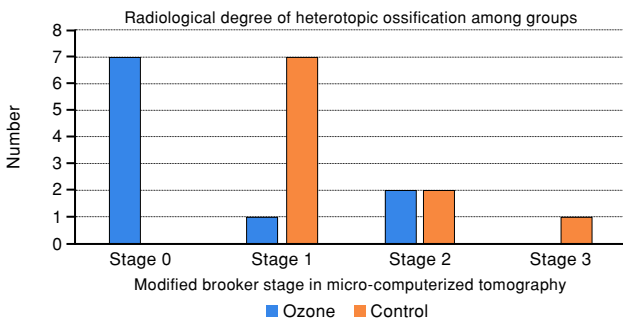


FIGURE 5. Radiological degree of heterotopic ossification in different animal groups.

Statistical analysis

Statistical analysis was performed using the IBM SPSS version 26.0 software (IBM Corp., Armonk, NY, USA). Descriptive data were presented in mean \pm standard deviation (SD), median and interquartile range (1st-3rd IQR) or number or frequency, where applicable. The Shapiro-Wilk normality test was used to determine whether the data were normally distributed. The Mann-Whitney U test was used to analyze non-normally distributed

(non-parametric) variables in the two groups. The chi-square test was used to compare the categorical data obtained by radiological and histopathological staging. A p value of <0.05 was considered statistically significant.

RESULTS

The modified Brooker staging used in radiological evaluation revealed HO formation in seven (70%) subjects in Stage 1, two (20%) in Stage 2, and one (10%) in Stage 3 in the control group, whereas in the OT group, HO formation was seen in three animals (30%), one in Stage 1 and two in Stage 2 (Figure 5). There was a statistically significant difference between the two groups ($p=0.006$). The HO ratios obtained by histopathological evaluation were examined and the median value was 42.5 (range, 30 to 55) in the control group and 0 (range, 0 to 25) in the OT group. A statistically significant relationship was found between the two groups ($p=0.003$). Considering the histopathological staging of HO, in which the severity of HO was categorized, all rats in the control group (100%) exhibited at least Stage 1 HO, while three rats

TABLE II
Histopathological findings related to heterotopic ossification

| | Group 1 (n=10) | | | | Group 2 (n=10) | | | | p |
|----------------------------|----------------|----|--------|-------|----------------|----|--------|------|---------------|
| | n | % | Median | IQR | n | % | Median | IQR | |
| HO area ratios | | | 42.5 | 30-55 | | | 0 | 0-25 | 0.003* |
| HO histopathological stage | | | | | | | | | |
| 0 | 0 | 0 | | | 6 | 60 | | | 0.014† |
| 1 | 3 | 30 | | | 3 | 30 | | | |
| 2 | 6 | 60 | | | 1 | 10 | | | |
| 3 | 1 | 10 | | | 0 | 0 | | | |

IQR: Interquartile range; HO: Heterotopic ossification; * Mann-Whitney U test; † Chi-square test.

TABLE III
Distribution of inflammatory findings in histopathological examination according to groups

| | Group 1 (n=10) | | | | Group 2 (n=10) | | | | p |
|-----------------------------|----------------|----|--------|-----|----------------|----|--------|-----|---------------|
| | n | % | Median | IQR | n | % | Median | IQR | |
| Leukocyte counts | | | 5.5 | 3-7 | | | 1 | 0-3 | 0.006* |
| Inflammatory response stage | | | | | | | | | |
| 0 | 0 | 0 | | | 5 | 50 | | | 0.020† |
| 1 | 5 | 50 | | | 4 | 40 | | | |
| 2 | 5 | 50 | | | 1 | 10 | | | |
| 3 | 0 | 0 | | | 0 | 0 | | | |

IQR: Interquartile range; HO: Heterotopic ossification; * Mann-Whitney U test; † Chi-square test.

in the OT group (30%) had Stage 1 HO and one (10%) had Stage 2 HO (Table II). This resulted in a significant difference between the groups ($p=0.014$). In the histopathological assessment of

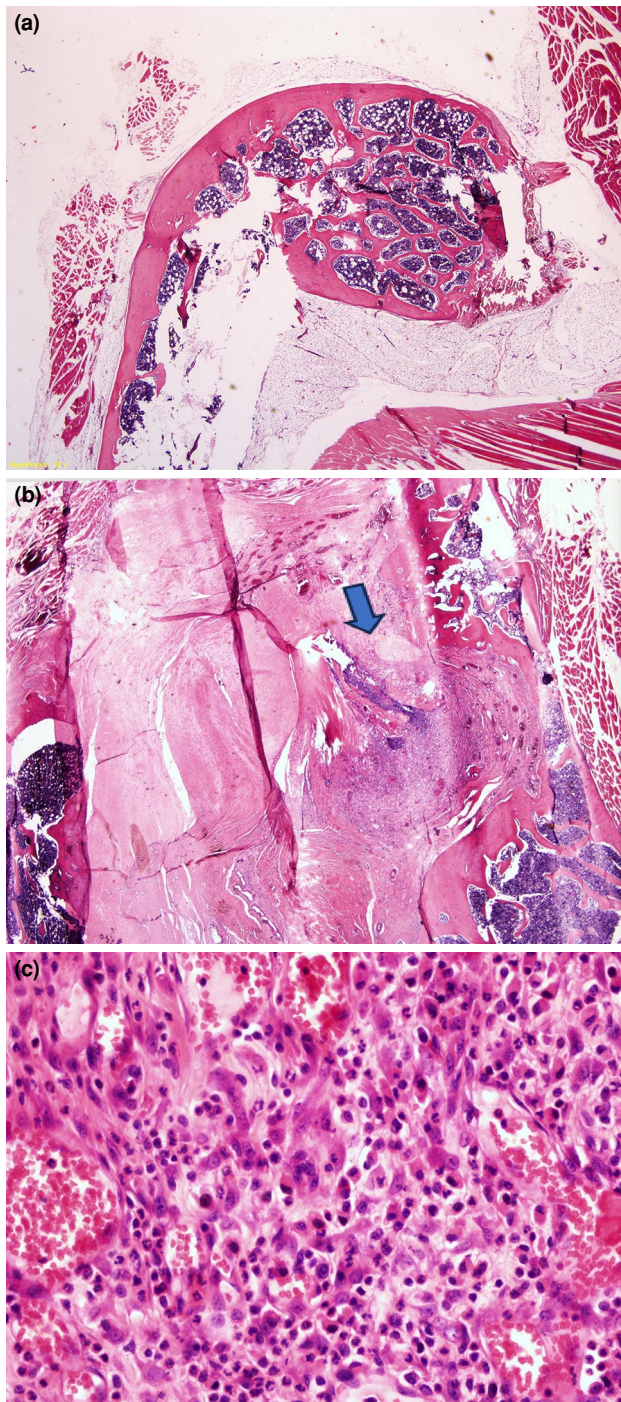


FIGURE 6. (a) An image of the femoral head and its surrounding area shows no inflammation in the ozone therapy (OT) group. (b, c) The image displays inflammation in the femoral region in the control group.

leukocyte counts within the HPF, the median value of leukocytes was 5.5 (range, 3 to 7) in the control group and 1 (range, 0 to 3) in the OT group (Figure 6). A statistically significant relationship was found between the two groups ($p=0.006$). The detailed results of the histopathological stage which classified the severity of inflammation are presented in Table III.

During both the pre- and postoperative periods, there was no statistically significant difference between the groups in terms of functional assessment, regarding walking analysis ($p>0.05$).

DISCUSSION

In the current study, we examined the efficacy of prophylactic ozone therapy for HO development after hip surgery in a rat model. Our study results showed that IP administration of OT effectively reduced the inflammatory response and prevented the formation of traumatic HO following hip surgery in rats. The preventive impact of OT, through its anti-inflammatory properties, may have been crucial in preventing HO. There was no significant difference between the groups in terms of functional assessment. Mobilization with range of motion exercises is one of the current therapy recommendations to prevent HO formation after hip surgery. Thus, the absence of any difference in walking ability and mobilization capacity between the two groups holds significant importance in ensuring the reliability and validity of the findings in the current investigation.

Establishing a HO model in animals is a difficult task. The conventional approaches involve the implantation and overexpression of osteogenic factors within the soft tissues.^[22] The initial investigations are based on the insertion of bone, bone marrow, and periostin into tissues outside the skeletal system to provide the required conditions for the formation of HO.^[22] In 1965, Urist^[23] enhanced this model and introduced the heterotopic implantation model, which achieved a success rate of 60%. However, both this model and the widely utilized model of Buck^[24] do not accurately replicate the precise process of HO formation, which involves cellular, metabolic, and mechanical variables. In rabbits, the osteoprogenitor cells dispersed over the hip area following the drilling of the femoral canal, according to Schneider et al.^[25] This process closely resembled the sequence of HO formation. Anthonissen et al.^[19] adapted and validated this model for use in rats. The authors achieved 90% HO development after hip surgery using their

modified technique. Another important point in creating a HO model is the follow-up period. Heterotopic ossification usually occurs between three and 12 weeks after injury in humans, and this period can be much longer.^[26-28] However, it has been well demonstrated that the basal metabolic rate of rats is three to four times higher than that of humans.^[27,29] This higher metabolic rate affects both the physiological processes such as bone healing and the pathological conditions such as HO. Several authors reported that a period of four to eight weeks was usually sufficient for the formation of HO in rat models.^[26-28] Brady et al.^[27] reported 70% of HO formation within six weeks in a severe trauma model. Additionally, Anthonissen et al.^[19] reported 90% of HO development after 12 weeks of follow-up in their rat model. The current study also repeated the methodology of Anthonissen et al.^[19] and observed HO formation in all rats in the control group after a 12-week follow-up period. This finding is consistent with previous studies. The high rate of HO formation in the control group in our study also indicates that both the 12-week follow-up period is sufficient and the radiological evaluation of micro-CT is successful in showing earlier HO formations.

Prophylaxis is the standard and primary treatment approach for traumatic HO. The effectiveness of surgically removing the bone located outside the skeletal system is a topic of debate, and it is not uncommon for the bone to rebuild after it has been removed.^[30] Therefore, preventative treatment is highly significant, even during surgical excision. Even though bone tissue proliferation is the final stage of HO formation, inflammatory cells (i.e., macrophages, lymphocytes, and mast cells) and signaling pathways (NF- κ B, hypoxia-inducible factor 1- α (HIF-1 α), tumor growth factor- β (TGF- β), and BMP) which trigger cell differentiation play a central role in the initiation of this cascade.^[3,31,32] Also, NSAIDs, bisphosphonates, and radiation therapy are used prophylactically by preventing the pathological process of HO development at different steps.^[33] Despite this, the pathological process cannot be completely inhibited, and these therapeutic modalities have significant adverse effects.^[34] Ozone therapy is recognized to modulate Nrf2-NF- κ B pathways and reduce the production of inflammatory mediators such as IL-1 β , IL-6, PGE1, and PGE2, thereby decreasing osteoblastic activity and BMP activation.^[4,10,32] In this study, both radiological and pathological findings revealed

that the anti-inflammatory mechanism of OT halted the pathological process in HO formation. Furthermore, OT has fewer side effects compared to other methods of suppressing inflammation.^[35]

One of the major effects of OT is the ability to reduce tissue ischemia by increasing the oxygen pressure in the surrounding tissues. Local tissue hypoxia is one of the main triggers of HO along with post-traumatic inflammation. The HIF-1 α levels increase under hypoxic conditions and initiate the HO process by overactivating the BMP signaling pathway.^[33,36] Ozone therapy is known to disrupt the trauma-induced local hypoxia-ischemia cycle by combining anti-inflammatory and hyperoxygenation properties, thereby reducing HIF-1 α /BMP-mediated osteogenic activity.^[33,37] In their experimental study, Güçlü et al.^[37] also proved that OT significantly inhibited HIF-1 α levels in hypoxic tissues by the hyperoxygenation effect. Ranganathan et al.^[33] emphasized the critical importance of this mechanism in HO formation and suggested that techniques that could inhibit this pathway should be investigated for the prevention of HO. Although HIF-1 α and BMP levels that may indicate hyperoxygenation could not be measured in our study, we may speculate that the significant decrease in HO areas in histopathological examination in the OT group is due to the combined anti-inflammatory and hyperoxygenation effects of ozone.

Nonetheless, this study has certain limitations which are essentially inherent to being an experimental animal study, such as a relatively small sample size of animals. Moreover, it is crucial to elucidate the essential therapeutic dosages and the optimal duration of therapy. Although specific ozone concentrations with anti-inflammatory and antioxidant properties have been identified in previous studies, another limitation is that we did not include control groups that received different doses of ozone or alternative anti-inflammatory drugs. Moreover, doing animal sacrifices at various time intervals would provide more significant insights on the anti-inflammatory impact of OT compared to a fixed time interval. The other limitation is the lack of a sham group. However, the injection of placebo (Ringer's) into the control group represents the development of HO without any effective treatment under surgical conditions. Therefore, the main reason for not including the sham group is that the number of animals would increase and lead to unnecessary repetition, contrary to the 3R (replacement, reduction, and

refinement) principles. Another limitation is that biological markers such as HIF-1 α , BMP, alkaline phosphatase, and inflammatory cytokines (IL-6, IL-1B, etc.), which can show the anti-inflammatory and hyperoxygenation effects of ozone and are thought to play a role in the pathogenesis of HO, could not be examined in tissue or blood. Although the negative effects of this examination on systemic inflammation or local complications are debatable, future studies which include these measurements would yield more comprehensive results. On the other hand, this study is the first to assess the efficacy of OT in preventing the formation of traumatic HO which would provide additional contribution to the body of knowledge in the literature.

In conclusion, our study results indicate that OT is effective in decreasing HO formation in rats following hip surgery. Further preclinical and clinical investigations are warranted to optimize the efficacy of OT in the future.

Data Sharing Statement: The data that support the findings of this study are available from the corresponding author upon reasonable request.

Author Contributions: Material preparation and data collection and analysis were performed: Ö.D.A., T.B., İ.A., A.H.T.; The first draft of the manuscript was written: Ö.D.A., T.B.; All reviews and editing of the manuscript were performed: T.B., C.K. All authors contributed to the study conception and design. All authors read and approved the final manuscript.

Conflict of Interest: The authors declared no conflicts of interest with respect to the authorship and/or publication of this article.

Funding: The authors received no financial support for the research and/or authorship of this article.

REFERENCES

- Adıgüzel İF, Orman O, Ünkar EA, Baydar M, Eren M, Öztürk K. Comparing the outcomes of tripod technique and locked plate fixation for the treatment of Mason type 3 radial head fractures. *Jt Dis Relat Surg* 2023;34:716-23. doi: 10.52312/jdrs.2023.1161.
- Köroğlu M, Karakaplan M, Özdeş HU, Maraş Özdemir Z. A rare mass with atypical localization: Heterotopic ossification associated with flexor hallucis longus. *Jt Dis Relat Surg* 2024;35:711-6. doi: 10.52312/jdrs.2024.1804.
- Macfarlane RJ, Han Ng B, Gamie Z, El Masry MA, Velonis S, Schizas C, et al. Pharmacological treatment of heterotopic ossification following hip and acetabular surgery. *Expert Opin Pharmacother* 2008;9:767-86. doi: 10.1517/14656566.9.5.767.
- Matsuo K, Chavez RD, Barruet E, Hsiao EC. Inflammation in fibrodysplasia ossificans progressiva and other forms of heterotopic ossification. *Curr Osteoporos Rep* 2019;17:387-94. doi: 10.1007/s11914-019-00541-x.
- Erel S, Küçük AA, Dikmen KK, Tekin E, Yigit Z, Güven M, et al. Evaluation of the efficacy of ozone therapy on liver tissue in the treatment of sepsis in rats with cecal perforation. *Medicina (Kaunas)* 2024;60:1552. doi: 10.3390/medicina60091552.
- Nadim AH. The effect of ozonized saline solutions processed under intense electric fields in the treatment of infected necrotizing acute pancreatitis: An experimental model. *Int J Med Med Sci* 2014;6:176-82. doi: 10.5897/IJMMS2014.1053.
- Kucukgul A, Erdogan S, Gonenci R, Ozan G. Beneficial effects of nontoxic ozone on H₂O₂-induced stress and inflammation. *Biochem Cell Biol* 2016;94:577-83. doi: 10.1139/bcb-2016-0033.
- Re L, Martínez-Sánchez G, Bordicchia M, Malcangi G, Pocognoli A, Morales-Segura AM, et al. Is ozone preconditioning effect linked to Nrf2/EpRE activation pathway in vivo? A preliminary result. *Eur J Pharmacol* 2014;742:158-62. doi: 10.1016/j.ejphar.2014.08.029.
- Delgado-Roche L, Riera-Romo M, Mesta F, Hernández-Matos Y, Barrios JM, Martínez-Sánchez G, et al. Medical ozone promotes Nrf2 phosphorylation reducing oxidative stress and pro-inflammatory cytokines in multiple sclerosis patients. *Eur J Pharmacol* 2017;811:148-54. doi: 10.1016/j.ejphar.2017.06.017.
- Martínez-Sánchez G, Schwartz A, Di Donna V. Potential cytoprotective activity of ozone therapy in SARS-CoV-2/COVID-19. *Antioxidants (Basel)* 2020;9:389. doi: 10.3390/antiox9050389.
- Simsek EK, Turkbey SD, Mert Ayan D, Araz C, Haberal B. Efficacy of ozone therapy in the treatment of frozen shoulder in rats: An experimental study. *Jt Dis Relat Surg* 2025;36. doi: 10.52312/JDRS.2025.2055.
- Faith RE, Hessler JR. Housing and environment. In: Krinke GJ, editor. *The laboratory rat*. 2nd ed. London: Academic Press; 2006. p. 303–37. doi: 10.1016/B978-012074903-4/50013-3.
- Yu B, Lin QR, Wang BW. Effect of intra-articular ozone injection on degenerative knee cartilage in rats. *Int J Ozone Ther* 2010;9:14-20.
- Üstebay S, Ömür Ö, Bilge A, Ülker D, Aysu Ü, Tezcan H. Impacts of ozone treatment and its relationship with IGF-1 levels after injury of soft tissue: An experimental study in rats model. *Kafkas Univ Vet Fak Derg* 2017;23:949-55. doi: 10.9775/kvfd.2017.18058.
- Ozturk O, Tezcan AH, Adali Y, Yıldırım CH, Aksoy O, Yagmurdu H, et al. Effect of ozone and methylprednisolone treatment following crush type sciatic nerve injury. *Acta Cir Bras* 2016;31:730-5. doi: 10.1590/s0102-865020160110000005.
- Tartari APS, Moreira FF, Pereira MCDS, Carraro E, Cidral-Filho FJ, Salgado AI, et al. Anti-inflammatory effect of ozone therapy in an experimental model of rheumatoid arthritis. *Inflammation* 2020;43:985-93. doi: 10.1007/s10753-020-01184-2.
- Jiang B, Su Y, Chen Q, Dong L, Zhou W, Li H, et al. Protective effects of ozone oxidative preconditioning on long-term injury after renal ischemia/reperfusion in rat. *Transplant Proc* 2020;52:365-72. doi: 10.1016/j.transproceed.2019.10.004.
- Wang L, Chen H, Liu XH, Chen ZY, Weng XD, Qiu T, et al. Ozone oxidative preconditioning inhibits renal fibrosis induced by ischemia and reperfusion injury in rats. *Exp Ther Med* 2014;8:1764-8. doi: 10.3892/etm.2014.2004.

19. Anthonissen J, Ossendorf C, Hock JL, Ritz U, Hofmann A, Rommens PM. A new small-animal model for the study of acquired heterotopic ossification after hip surgery. *Acta Orthop Traumatol Turc* 2015;49:197-202. doi: 10.3944/AOTT.2015.14.0271.
20. Ohlmeier M, Krenn V, Thiesen DM, Sandiford A, Citak M. Heterotopic ossification in orthopaedic and trauma surgery: A histopathological ossification score. *Sci Rep* 2019;9:18401. doi: 10.1038/s41598-019-54986-2.
21. de Medinaceli L, Freed WJ, Wyatt RJ. An index of the functional condition of rat sciatic nerve based on measurements made from walking tracks. *Exp Neurol* 1982;77:634-43. doi: 10.1016/0014-4886(82)90234-5.
22. Bertelsen A. Experimental investigations into post-foetal osteogenesis. *Acta Orthop Scand* 1944;15:139-81. doi: 10.3109/17453674408991069.
23. Urist MR. Bone: Formation by autoinduction. *Science* 1965;150:893-9. doi: 10.1126/science.150.3698.893.
24. Buck RC. Regeneration of tendon. *J Pathol Bacteriol* 1953;66:1-18. doi: 10.1002/path.1700660103
25. Schneider DJ, Moulton MJR, Singapuri K, Chinchilli V, Deol GS, Krenitsky G, et al. Inhibition of heterotopic ossification with radiation therapy in an animal model. *Clin Orthop Relat Res* 1998;355:35-46. doi: 10.1097/00003086-199810000-00005.
26. Yoshida Y, Matsubara H, Fang X, Hayashi K, Nomura I, Ugaji S, et al. Adipose-derived stem cell sheets accelerate bone healing in rat femoral defects. *PLoS One* 2019;14:e0214488. doi: 10.1371/journal.pone.0214488.
27. Brady RD, Zhao MZ, Wong KR, Casilla-Espinosa PM, Yamakawa GR, Wortman RC, et al. A novel rat model of heterotopic ossification after polytrauma with traumatic brain injury. *Bone* 2020;133:115263. doi: 10.1016/j.bone.2020.115263.
28. Fan Y, Leape CP, Hugard S, McCanne M, Thomson A, Wojtkiewicz GR, et al. A longitudinal rat model for assessing postoperative recovery and bone healing following tibial osteotomy and plate fixation. *BMC Musculoskelet Disord* 2023;24:172. doi: 10.1186/s12891-023-06942-5.
29. Terpstra AHM. Differences between humans and mice in efficacy of the body fat lowering effect of conjugated linoleic acid: Role of metabolic rate. *J Nutr* 2001;131:2067-8. doi: 10.1093/jn/131.7.2067.
30. Dey D, Wheatley BM, Cholok D, Agarwal S, Yu PB, Levi B, et al. The traumatic bone: Trauma-induced heterotopic ossification. *Transl Res* 2017;186:95-111. doi: 10.1016/j.trsl.2017.06.004.
31. Wang X, Li F, Xie L, Crane J, Zhen G, Mishina Y, et al. Inhibition of overactive TGF- β attenuates progression of heterotopic ossification in mice. *Nat Commun* 2018;9:551. doi: 10.1038/s41467-018-02988-5.
32. Simsek EK, Sahinturk F, Gul E, Tepeoglu M, Araz C, Haberal B. Effect of ozone therapy on epidural fibrosis in rats. *World Neurosurg* 2023;175:e296-302. doi: 10.1016/j.wneu.2023.03.075.
33. Ranganathan K, Loder S, Agarwal S, Wong VW, Forsberg J, Davis TA, et al. Heterotopic ossification: Basic-science principles and clinical correlates. *J Bone Joint Surg Am* 2015;97:1101-11. doi: 10.2106/JBJS.N.01056.
34. Balboni TA, Gobezie R, Mamon HJ. Heterotopic ossification: Pathophysiology, clinical features, and the role of radiotherapy for prophylaxis. *Int J Radiat Oncol Biol Phys* 2006;65:1289-99. doi: 10.1016/j.ijrobp.2006.03.053.
35. Sagai M, Bocci V. Mechanisms of action involved in ozone therapy: Is healing induced via a mild oxidative stress? *Med Gas Res* 2011;1:29. doi: 10.1186/2045-9912-1-29.
36. Wang H, Lindborg C, Lounev V, Kim JH, McCarrick-Walmsley R, Xu M, et al. Cellular hypoxia promotes heterotopic ossification by amplifying BMP signaling. *J Bone Miner Res* 2016;31:1652-65. doi: 10.1002/jbmr.2848.
37. Güçlü A, Erken HA, Erken G, Dodurga Y, Yay A, Özçoban Ö, et al. The effects of ozone therapy on caspase pathways, TNF- α , and HIF-1 α in diabetic nephropathy. *Int Urol Nephrol* 2016;48:441-50. doi: 10.1007/s11255-015-1169-8.