



# To fix or not to fix: A comparison of grafting with fixation versus grafting alone in proximal femur aneurysmal bone cysts

Ebubekir Eravsar, MD , Ali Güleç, MD , Selim Safalı, MD , Ali Özdemir, MD ,  
Sadettin Çiftci, MD , Bahattin Kerem Aydın, MD 

Department of Orthopedics and Traumatology, Selçuk University Faculty of Medicine, Konya, Türkiye

Aneurysmal bone cysts (ABC) can occur in various parts of the body and often affect long bones.<sup>[1]</sup> Although there is still no definitive consensus on its treatment, curettage, high-speed burring, and grafting are commonly used in the treatment of these cysts.<sup>[2]</sup> Adjuvant procedures such as phenolization, cauterization, and cryotherapy can be applied to the cavity after curettage. Since there is no gold standard for treatment, options may vary depending on clinical practices and surgical experiences. While curettage and grafting are the classical treatments for cystic lesions, there are opinions suggesting the need for internal fixation in cystic lesions of the proximal femur.<sup>[3-5]</sup>

Those who support the use of internal fixation among treatment options have argued that the

Received: January 30, 2025

Accepted: March 02, 2025

Published online: April 05, 2025

**Correspondence:** Ebubekir Eravsar, MD, Selçuk Üniversitesi Tıp Fakültesi Ortopedi ve Travmatoloji Anabilim Dalı, 42250 Selçuklu, Konya, Türkiye.

E-mail: bekireravsar@gmail.com

Doi: 10.52312/jdrs.2025.2187

**Citation:** Eravsar E, Güleç A, Safalı S, Özdemir A, Çiftci S, Aydın BK. To fix or not to fix: A comparison of grafting with fixation versus grafting alone in proximal femur aneurysmal bone cysts. Jt Dis Relat Surg 2025;36(2):358-365. doi: 10.52312/jdrs.2025.2187.

©2025 All right reserved by the Turkish Joint Diseases Foundation

This is an open access article under the terms of the Creative Commons Attribution-NonCommercial License, which permits use, distribution and reproduction in any medium, provided the original work is properly cited and is not used for commercial purposes (<http://creativecommons.org/licenses/by-nc/4.0/>).

## ABSTRACT

**Objectives:** This study aims to evaluate whether adding internal fixation to grafting could improve radiological and functional outcomes compared to grafting alone in patients with aneurysmal bone cysts (ABCs) of the proximal femur and to investigate whether there was a significant difference between these two treatment methods in terms of the need for a second surgery.

**Patients and methods:** Between January 2012 and January 2022, a total of 30 patients (21 males, 9 females; mean age: 13.7±5.1 years; range, 5 to 23 years) with proximal femur ABCs who underwent surgical treatment were retrospectively analyzed. Twelve of them were treated by grafting alone (Group GA), while the remaining 18 were treated by grafting along with fixation using plates and screws (Group GF). The demographic data of these patients, the need for secondary surgery, radiological and functional scores were recorded. The modified Neer Classification was used for radiological evaluations, while the Musculoskeletal Tumor Society (MSTS) scores were utilized for functional assessments.

**Results:** Overall, the mean preoperative MSTS scores were lower than the postoperative MSTS scores in both GF and GA groups ( $p<0.001$  and  $p=0.002$ ). The postoperative radiological scores of the GF group were superior to the GA group ( $p=0.012$ ). However, no significant difference was found in the postoperative MSTS scores between the groups ( $p=0.185$ ). Secondary surgeries were performed in six patients in the GF group due to implant removal and in three patients in the GA group due to recurrence. No significant difference was observed between the GF group and the GA group in terms of secondary surgery ( $p=0.626$ ). Comparisons of final radiological ( $p=0.325$ ) and final MSTS ( $p=0.346$ ) scores after secondary surgeries revealed no significant differences.

**Conclusion:** In proximal femoral ABCs, grafting with fixation may provide more favorable radiological outcomes with lower recurrence rates. While grafting with fixation seems to increase the risk for a secondary surgery due to implant removal, our study shows that recurrence in high-risk regions can also necessitate secondary surgeries with grafting alone. Notably, both approaches can achieve successful outcomes, even with recurrent surgeries.

**Keywords:** Aneurysmal bone cyst, bone cysts, fixation; grafting, proximal femur.

proximal femur is an anatomically critical area, making it prone to complications.<sup>[6]</sup> There are those who consider the key steps in the successful treatment of proximal femoral cystic lesions to include the complete removal of the cystic lesion, filling the cavity with osteoconductive material, and fixation with a plate.<sup>[4]</sup> Given the extended healing time, internal fixation may offer greater benefits by facilitating early mobilization and weight-bearing.<sup>[7]</sup> However, the use of implants associated with internal fixation presents certain challenges, including irritation, the potential need for implant removal, and increased costs.

To the best of our knowledge, there is no comparative study on this subject in the literature. In the present study, our primary objective was to evaluate whether adding internal fixation to grafting could improve radiological and functional outcomes compared to grafting alone. Our secondary objective was to assess whether there was a significant difference between these two treatment methods in terms of the need for a second surgery.

## PATIENTS AND METHODS

This single-center, retrospective study was conducted at Selçuk University Faculty of Medicine, Department of Orthopedics and Traumatology between January 2012 and January 2022. Our center is a referral center in which orthopedic tumor cases from near cities and regions are highly accepted. There is a Medical Council consisting of orthopedic surgeons, radiologists, pathologists, and oncologists and each tumor case is discussed. Treatment decisions for patients are made based on the Medical Council's recommendations. Initially, 88 patients who underwent surgery for ABCs without a pathological fracture were screened. Of them, 54 with involvement in areas other than the proximal femur were excluded. Three patients with less than two years of final follow-up were also excluded from the study. Among the remaining patients, one treated with a synthetic bone graft was excluded. Finally, a total of 30 patients (21 males, 9 females; mean age: 13.7±5.1 years; range, 5 to 23 years) who met the inclusion criteria were recruited. All relevant data of the patients were retrieved from the hospital database. A written informed consent was obtained from the parents and/or legal guardians of the patients. The study protocol was approved by the Selçuk University Faculty of Medicine Local

Ethics Committee (date: 13.02.2024, no: 2024/90). The study was conducted in accordance with the principles of the Declaration of Helsinki.

All of the patients presented to our clinic or were referred due to complaints such as pain and limping. None of the patients had pathological fractures. All of these patients underwent the same surgical procedure, which included curettage, high-speed burring, and the application of allografts for the cysts. No additional adjuvant therapy was applied in both groups. However, of these patients, 18 who were treated with additional fixation with plates and screws in addition to grafting were assigned to the grafting & fixation (GF) group, while 12 patients treated only with grafting were assigned to the grafting alone (GA) group. In deciding whether to perform grafting alone or grafting with fixation in the treatment of patients, factors such as the size of the cyst, the patient's age, and body mass index were not taken into account to avoid bias. In our clinic, previously, grafting alone was usually preferred for the treatment of proximal femoral ABCs. In the subsequent periods, grafting with fixation method started to be adopted for the treatment of these cysts. Samples taken during the surgeries were examined by a pathologist specialized in orthopedic tumors, and it was confirmed that all of the patients were diagnosed with ABCs. Follow-up visits were scheduled at Weeks 2, 6, and 12 postoperatively, followed by monthly visits for the first year and annual check-ups thereafter. In the GF group, toe-touch weight-bearing was initiated one week after surgery and gradually increased. In contrast, patients in the GA group usually started the same process at six to eight weeks postoperatively.

Demographic data, preoperative cyst size, initial surgical procedures performed, and if applicable, secondary surgical procedures were examined for both groups of patients. The term secondary surgery was defined as a second surgery performed for the cyst and its complications or implant removal. Implant removal was performed in patients with complaints such as irritation and those with high growth potential. The preoperative cyst size was assessed by a blinded radiologist and a blinded orthopedic surgeon through three independent measurements, with the mean value utilized for analysis. The cyst boundaries were manually delineated on anterior-posterior X-ray images, and the enclosed area was quantified using the hospital's Picture Archiving and Communication

**TABLE I**  
Modified Neer classification

Score	Classification	Description
1	Healed	Cyst filled with new bone, with or without small radiolucent area(s) <1 cm in size
2	Healed with defects	Radiolucent area(s) <50% of the diameter of the bone with enough cortical thickness to prevent fracture
3	Persistent cyst	Radiolucent area >50% of the diameter of the bone and with a thin cortical rim; no increase of the size of the cyst
4	Recurrent cyst	Cyst reappeared in a previously obliterated area or a radiolucent area has increased in size

System (PACS) software (Enlil PACS, Türkiye). The modified Neer Classification was employed to assess radiological cyst healing (Table I).<sup>[8]</sup> The radiographs taken immediately before the second surgery for patients who underwent two surgeries (the last follow-up after the first surgery), and the radiographs taken at the latest follow-up for patients who underwent only one surgery were scored according to the modified Neer Classification. These scores were, then, compared between the groups as postoperative radiological scores. Functional assessments were conducted using the Musculoskeletal Tumor Society (MSTS) scoring system. Accordingly, higher scores indicate more favorable outcomes, with the maximum score that can be obtained is 30. Pre- and postoperative MSTS scores between the groups were compared. While evaluating the postoperative MSTS scores, scores measured immediately before the second surgery for patients who underwent two surgeries (the last follow-up after the first surgery), and scores measured at the last follow-up for patients who underwent only one surgery were considered.

Patients who required a second surgery due to implant removal or recurrences during follow-up were scheduled for follow-up again after their secondary surgeries were completed, similar to their initial surgeries. The final radiological evaluations of all patients in both groups were compared as the final radiological scores. Additionally, the final MSTS scores obtained at the final follow-ups in both groups were compared as the final MSTS scores.

#### Statistical analysis

Statistical analysis was performed using the IBM SPSS version 22.0 software (IBM Corp., Armonk, NY, USA). Descriptive data were expressed in mean  $\pm$  standard deviation (SD), median (min-max) or number and frequency, where applicable. The assumptions of normality were checked using the Kolmogorov-Smirnov and Levene's tests.

In the cases in which these assumptions were fulfilled, independent sample t-test was used for group comparisons, otherwise non-parametric Mann-Whitney U test was carried out. Pre- and postoperative scores were analyzed by using the Wilcoxon signed-rank test. For comparison of the nominal level of measurement, the chi-square test was utilized. A *p* value of <0.05 was considered statistically significant.

#### RESULTS

The median follow-up duration after the initial surgery for the GF group was found to be 30 (range, 22 to 58) months, while it was 84 (range, 19 to 128) months for the GA group. There was no significant difference in the age ( $p=0.394$ ), sex ( $p=0.745$ ), and cyst size ( $p=0.797$ ) between the groups (Table II). Comparing the postoperative radiological scores between the groups, a superiority was achieved in the GF group compared to the GA group ( $p=0.012$ ) (Table II). Overall preoperative MSTS scores were lower than the postoperative MSTS scores in both GF ( $p<0.001$ ) and GA groups ( $p=0.002$ ). In terms of preoperative MSTS scores, there were no significant difference between the GF and GA groups ( $p=0.983$ ). In terms of postoperative MSTS scores, there were no significant differences between the GF and GA groups ( $p=0.185$ ) (Table II).

All 18 patients in the GF group recovered without the need for a secondary procedure (Figure 1). However, secondary surgery for implant removal was performed in six of these patients after cyst healing. Five of the patients who had their implants removed were younger than 12 years old; three of them developed implant irritation, while two had the implant removed due to concerns about growth expectations and potential future complications. The other patient who underwent implant removal was 16 years old, and the procedure was performed due to implant irritation. None of

TABLE II

The descriptive characteristics, secondary surgery ratios, radiological scores, MSTs scores, and their comparison between the GF group and the GA group

	Grafting & fixation (n=18)			Grafting alone (n=12)			p
	n	%	Mean±SD	n	%	Mean±SD	
Age (year)			13.0±5.0			14.7±5.4	0.394
Sex							0.745
Female	5			4			
Male	13			8			
Cyst size (mm <sup>2</sup> )			1983±864			2059±666	0.797
Secondary surgery	6	33		3	25		0.626
Postoperative radiological scores							<b>0.012</b>
1	13			3			
2	5			6			
3				3			
Preoperative MSTs scores			15.0±3.8			14.8±3.9	0.983
Postoperative MSTs scores			27.8±3.7			26.0±4.2	0.185

MSTs: Musculoskeletal tumor society; GF: Grafting & fixation; GA: Grafting alone; SD: Standard deviation.

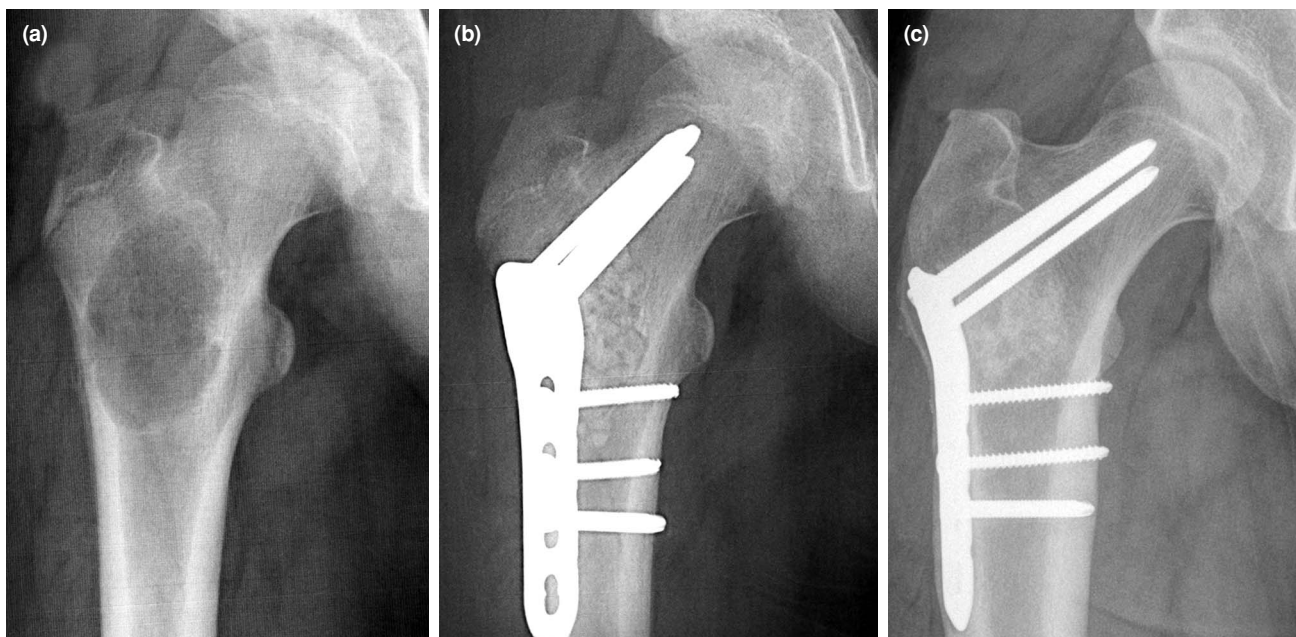
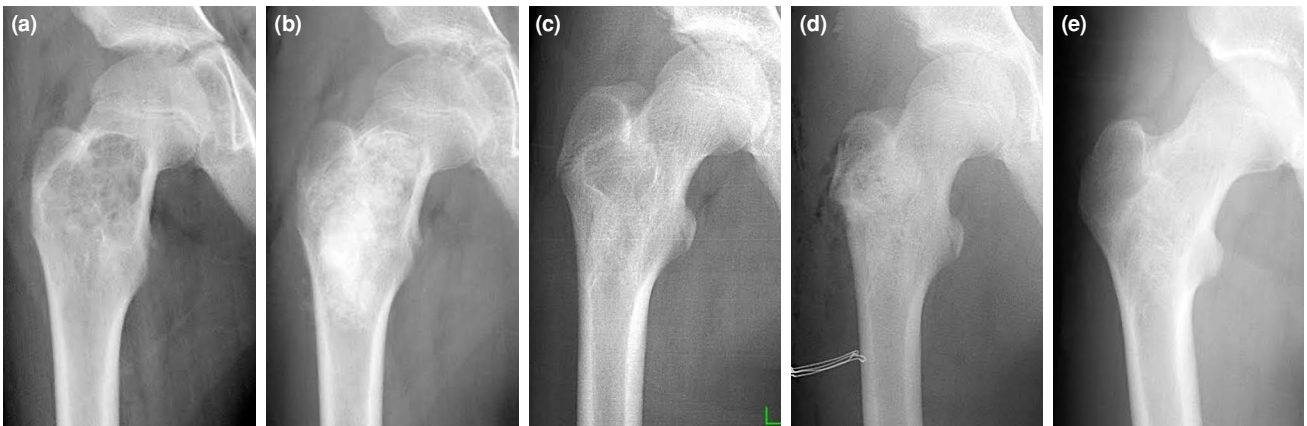


FIGURE 1. (a) Preoperative radiograph of proximal femur aneurysmal bone cyst, (b) fixation application in addition to grafting, (c) healed cyst in follow-ups.

the patients experienced any complications during implant removal. None of the other patients who did not undergo implant removal reported any implant-related issues. Nine of the 12 patients in the GA group who underwent only grafting recovered without the need for a second surgery. In this group, three patients required a secondary surgery due to

recurrence during follow-up (Figure 2). All of these patients had complaints such as pain and impaired functionality, accompanied by radiological findings explaining these symptoms. Comparing the number of secondary surgeries between the two groups, no significant difference was observed ( $p=0.626$ ) (Table II).



**FIGURE 2.** (a) The aneurysmal bone cystic lesion, (b) treated with grafting alone, (c) shows recurrence during follow-ups, (d) re-grafting with secondary surgery, (e) and ultimately healing of the cyst.

The median final follow-up duration was 40 (range, 25 to 58) months in the GF group and 89 (range, 61 to 131) months in the GA group. Comparing the final radiological scores between the groups, no significant difference was found in the radiographic evaluations at the final follow-up ( $p=0.325$ ). In terms of the final MSTS scores, the GF group had a mean score of  $29.4\pm 0.9$ , while the GA group had a mean score of  $28.5\pm 2.1$ . There was no significant difference observed between the groups in the comparison of these scores ( $p=0.346$ ). After secondary surgeries, no functional or radiological differences were observed between the two groups.

## DISCUSSION

In the present study, we investigated the effect of applying additional plates and screws during the treatment of proximal femoral ABCs by grafting. Our study results showed that patients who underwent grafting with fixation applied to the proximal femur had superior postoperative radiological outcomes compared to patients who underwent grafting alone. However, no significant difference was found between the two groups in terms of postoperative functional outcomes and the need for secondary surgery. Patients in the group treated with grafting alone who developed recurrence during follow-up required secondary surgery. On the other hand, in the group treated with grafting combined with fixation, implant removal was performed as a second surgery in patients with implant irritation or growth expectations. In the final evaluations conducted after the completion of secondary surgeries and full recovery of the patients, no significant differences

were observed between the two groups in terms of radiological and functional outcomes. The lack of differences in the ages, sex, and cyst size between the groups in the study is valuable for comparing the relationship between the surgical methods and radiological-functional scores. A similar study conducted previously focused on unicameral cysts, a different pathology, and yielded results similar to those of our study.<sup>[7]</sup> However, to the best of our knowledge, there is no study comparing the application of fixation in proximal femur ABCs. Therefore, we believe that the findings obtained in this study provide a significant contribution to the literature.

One of the noteworthy findings of this study is that postoperative radiological scores were superior in the GF group compared to the GA group. Another significant observation is that all three cases of recurrence occurred in the GA group. In the treatment of ABCs, thorough curettage of the cyst wall and the use of adjuvant therapies, such as high-speed burring, are critical components of the therapeutic process. In patients treated with grafting alone, excessive curettage and burring, which often require the creation of a cortical window, can naturally increase the risk of fracture.<sup>[16]</sup> In this study, differences in recurrence rates may be linked to variations in surgical approach, particularly in the extent of curettage and extent of high-speed burring performed. In patients treated with grafting alone, these procedures may have been performed less aggressively due to concerns about the fracture risk. In contrast, those who underwent grafting with fixation may have received a more aggressive approach, as fixation could provide additional

stability. However, due to the retrospective nature of this study, the exact extent of surgical aggressiveness cannot be established. This variability introduces a potential bias and may help explain the differences in recurrence rates, despite the difficulty in objectively assessing the adequacy of curettage. Furthermore, there is no clear evidence to support the theory that avoiding metallic implants leads to increased recurrence. The higher postoperative radiological scores in the GF group further support this hypothesis. The improved radiological outcomes in this group may be attributed to more aggressive curettage, made possible by the use of fixation. Additionally, previous studies have emphasized the significance of adequate curettage, recognizing it as a key factor in lowering recurrence rates.<sup>[9-11]</sup> Another type of secondary surgery is implant removal. In the current study, among the 18 patients in the GF group, implants were removed in only six cases. Implant removal surgery still remains a controversial topic in the literature, with no consensus regarding its indications, since the risks and complications associated with implant removal surgery are significant and cannot be underestimated.<sup>[12-14]</sup> Therefore, some believe that implant removal should only be considered in cases of infection, mechanical failure, or truly implant-related irritation.<sup>[12]</sup> Prior to surgery, we provided detailed information to patients and their families regarding implant removal, explaining all potential risks associated with the procedure. We also emphasized the high complication rates of implant removal surgeries performed for non-medical reasons.<sup>[13]</sup> Implant removal surgery in this study was guided by two primary indications: implant irritation causing patient discomfort and high growth potential in patients. Based on these criteria, no significant difference was observed in the rates of secondary surgeries. In the literature, the use of fixation in addition to grafting for proximal cysts was investigated by Wilke et al.<sup>[7]</sup> in a study involving 36 patients with unicameral bone cysts. Their findings indicated a higher recurrence rate in patients who did not undergo fixation, which aligns with the results of our study. However, the authors did not discuss the possible reason for the higher recurrence rate in patients who did not undergo fixation. When they examined patients who required a reoperation for reasons other than implant removal, they found a significant increase in the rate of reoperation among those who did not undergo initial fixation previously. However, when implant removal procedures were included, no significant difference was observed in

the overall rate of secondary surgery. Although our study provides similar findings to the mentioned study in these aspects, there are some important differences. First, our study focuses on a different pathology-ABCs. Another key distinction is that Wilke et al.'s<sup>[7]</sup> study included both patients with and without pathological fractures. Additionally, in the group which did not receive internal fixation, some patients underwent grafting alone, while others received steroid injection. The patients in the groups of our study exhibit more homogeneous characteristics in these aspects.

The anatomical characteristics and mechanical loads of the proximal femur make the treatment of cysts in this area highly important. The possibility of developing a pathological fracture in the proximal femur is extremely dangerous in itself, as complication rates in these fractures can be as high as 40%.<sup>[15]</sup> These complications may include nonunion, progression of the lesion, refracture, loss of reduction, limb length discrepancy, avascular necrosis, malunion, and deformity. Pathological fractures and associated complications can significantly impact the functional life of patients. The classical surgical treatment of ABCs, involving curettage and grafting, creates a large defect that predisposes the area to fractures. Additionally, the use of cortical windows in surgery further increases this risk. Considering the frequent occurrences of graft resorption and recurrences despite grafting, it is thought that prophylactic fixation with implants may be necessary in vulnerable areas such as the proximal femur.<sup>[11,16,17]</sup> Considering the prolonged healing duration, internal fixation may also be more beneficial in terms of early mobilization and weight-bearing. Indeed, in this study, patients treated with grafting combined with fixation were able to bear weight earlier. The risk factors for tumoral lesions to develop pathological fractures include location, size, and severity of cortical destruction.<sup>[4]</sup> The risk of pathological fracture was predicted by calculating a bone cyst index based on the measurements of the simple bone cyst area and diaphyseal diameter obtained from radiological images.<sup>[18]</sup> Our study did not calculate this measure, as this index is typically defined for simple bone cysts, which usually have a more asymptomatic nature and may not be suitable for our study. This is largely because all patients presenting with persistent pain were already scheduled for surgical treatment. Additionally, the risk of pathological fracture associated with benign lesions in the proximal femur can be as high as 80%, which is

quite significant.<sup>[4,16]</sup> Due to the critical anatomy of the region where risk cannot be taken, the contribution of this index calculation to treatment planning is quite limited. Additionally, there is also an opinion that the bone cyst index does not have significant predictive value in determining the risk of pathological fractures.<sup>[19]</sup>

In the present study, we used plate and screw fixation. However, review of the literature reveals that elastic nails can be also used as an implant choice for other types of cysts. According to Zhang et al.'s<sup>[20]</sup> study, intramedullary nailing with elastic intramedullary nails was superior to non-nailing in simple bone cysts. Furthermore, a study conducted by Roposch et al.<sup>[21]</sup> indicated that elastic nailing in the treatment of bone cysts allowed for early mobilization and reduced complications such as pathological fractures. It is believed that elastic nailing consistently contributes to the healing process in the treatment of simple bone cysts by causing intramedullary decompression.<sup>[16,20,22,23]</sup> However, in our study, a more stable fixation with plate and screw fixation was used in the ABC patients. According to Tomaszewski et al.,<sup>[4]</sup> the key steps in the successful treatment of cystic lesions included complete removal of the cystic lesion, filling the cavity with osteoconductive material, and fixation with a plate. In our study, allografts were used to fill the defects created after curettage. Although autografts are considered to be more successful as graft materials,<sup>[24]</sup> there are opinions suggesting that the graft type does not affect treatment success.<sup>[8]</sup> Additionally, considering the limited availability of autograft sources and donor site morbidities, allografts are a good option for the treatment of cystic bone lesions. Another graft option is fibular grafts, although they were not preferred in our study. Of note, fibular grafts provide greater stability and may result in less fixation failure.<sup>[17,25]</sup>

The main limitation to the present study is its single-center, retrospective design with a relatively small sample size. While the number of patients in our study is comparable to those in previous studies,<sup>[3,4,17,21,22]</sup> future prospective studies with larger populations would help provide clearer insights into this issue. Another notable limitation relates to secondary surgery, particularly implant removal. This procedure lacks a clear consensus, and the indications for its necessity can vary among surgeons. In our study, implant removal was performed solely based on medical indications. However, in cases where surgeons have broader

indications, the frequency of secondary surgeries may be higher for patients treated with fixation. In addition, there may have been a potential treatment-related bias in our study. Although difficult to quantify, patients treated with curettage alone may not have undergone an excessively aggressive approach due to concerns about fracture risk. While this can be considered a bias, it also reflects a legitimate concern that many surgeons may encounter in practice, highlighting its relevance as an aspect of this study. Another significant limitation is the relatively short follow-up periods. Short follow-up durations may be inadequate for assessing the recurrence and complications of ABCs. Additionally, in the study, while grafting alone was performed in the initial years, grafting with fixation technique was applied in the later years. As a result, the final follow-up period for the grafting with fixation group was noticeably shorter than that of the other group.

In conclusion, in patients with proximal femoral ABCs, grafting combined with fixation may result in more favorable postoperative radiological outcomes with lower recurrence rates. Another important insight concerns secondary surgeries. While it may initially seem that grafting with fixation can increase the risk of secondary surgeries due to potential implant removal, this study demonstrates that complications related to the cyst itself, particularly in this high-risk region, can also necessitate secondary surgeries when grafting alone is used. Therefore, surgeons may not need to adopt excessive caution regarding implant use in the treatment of ABCs in the proximal femur. Furthermore, successful outcomes can be achieved in the treatment of proximal femoral ABCs with both approaches, even if recurrent surgeries are required. Nonetheless, further large-scale, prospective studies are warranted to draw more reliable conclusions on this subject.

**Data Sharing Statement:** The data that support the findings of this study are available from the corresponding author upon reasonable request.

**Author Contributions:** Idea/concept: E.E.; Design: E.E., A.Ö.; Control/supervision, critical review: E.E., B.K.A.; Data collection and/or processing: S.S., S.Ç., A.G.; Analysis and/or interpretation: E.E., A.G., S.S., A.Ö., S.Ç.; Literature review: E.E., S.S., A.Ö., S.Ç., B.K.A.; Writing the article: E.E., A.G., S.S., A.Ö., S.Ç., B.K.A.; References: A.G.; Materials: S.S., S.Ç., A.G.

**Conflict of Interest:** The authors declared no conflicts of interest with respect to the authorship and/or publication of this article.

**Funding:** The authors received no financial support for the research and/or authorship of this article.

## REFERENCES

- Döring K, Puchner S, Vertesich K, Funovics PT, Hobusch G, Sulzbacher I, et al. Results in the surgical treatment of aneurysmal bone cysts - A retrospective data analysis. *Orthop Traumatol Surg Res* 2022;108:103095. doi: 10.1016/j.otsr.2021.103095.
- Kaya İ, Ayhan B, Ulucaköy C, Toğral G, Güngör BŞ. Does the preoperative neutrophil-to-lymphocyte ratio have a prognostic value in aneurysmal bone cysts? *Jt Dis Relat Surg* 2023;34:425-31. doi: 10.52312/jdrs.2023.1048.
- Lin AJ, Siddiqui AA, Fan B, Bennett JT, Illingworth KD, Andras LM, et al. Treatments and sequelae of pediatric pathologic proximal femur fractures due to benign bone cyst. *J Pediatr Orthop* 2022;42:e661-6. doi: 10.1097/BPO.0000000000002128.
- Tomaszewski R, Rutz E, Mayr J, Dajka J. Surgical treatment of benign lesions and pathologic fractures of the proximal femur in children. *Arch Orthop Trauma Surg* 2022;142:615-24. doi: 10.1007/s00402-020-03687-x.
- Jiang X. Application of the locking compression pediatric Hip Plate™ in children with proximal femoral tumors. *J Orthop Surg Res* 2022;17:536. doi: 10.1186/s13018-022-03433-6.
- Mascard E, Gomez-Brouchet A, Lambot K. Bone cysts: Unicameral and aneurysmal bone cyst. *Orthop Traumatol Surg Res* 2015;101:S119-27. doi: 10.1016/j.otsr.2014.06.031.
- Wilke B, Houdek M, Rao RR, Caird MS, Larson AN, Milbrandt T. Treatment of unicameral bone cysts of the proximal femur with internal fixation lessens the risk of additional surgery. *Orthopedics* 2017;40:e862-7. doi: 10.3928/01477447-20170810-01.
- Wu PK, Chen CF, Chen CM, Tsai SW, Cheng YC, Chang MC, et al. Grafting for bone defects after curettage of benign bone tumor - Analysis of factors influencing the bone healing. *J Chin Med Assoc* 2018;81:643-8. doi: 10.1016/j.jcma.2017.08.024.
- Başarir K, Pişkin A, Güçlü B, Yıldız Y, Sağlık Y. Aneurysmal bone cyst recurrence in children: A review of 56 patients. *J Pediatr Orthop* 2007;27:938-43. doi: 10.1097/bpo.0b013e31815a5fd3.
- Çelik S, Uludağ A, Tosun HB, Serbest S, Gürger M, Kılıç S. Unicameral (simple) and aneurysmal bone cysts: The effect of insufficient curettage on recurrence. *Pan Afr Med J* 2016;24:311. doi: 10.11604/pamj.2016.24.311.9624.
- Toğral G, Yapar A, Tolunay T. Which one of the benign tumors and tumor-like lesions located in long bones needs prophylactic fixation during surgery? *Jt Dis Relat Surg* 2021;32:210-7. doi: 10.5606/ehc.2020.75064.
- Cundy PJ, Williams N. Metal implants in children. *J Child Orthop* 2024;18:557-68. doi: 10.1177/18632521241293954.
- Kovar FM, Strasser E, Jandl M, Endler G, Oberleitner G. Complications following implant removal in patients with proximal femur fractures - an observational study over 16 years. *Orthop Traumatol Surg Res* 2015;101:785-9. doi: 10.1016/j.otsr.2015.07.021.
- Montgomery BK, Gamble JG, Kha ST, Hecht GG, Vorhies JS, Lucas JF. Indications for and risks associated with implant removal after pediatric trauma. *J Am Acad Orthop Surg Glob Res Rev* 2022;6:e22.00050. doi: 10.5435/JAAOSGlobal-D-22-00050.
- Shrader MW, Schwab JH, Shaughnessy WJ, Jacofsky DJ. Pathologic femoral neck fractures in children. *Am J Orthop (Belle Mead NJ)* 2009;38:83-6.
- Erol B, Topkar MO, Aydemir AN, Okay E, Caliskan E, Sofulu O. A treatment strategy for proximal femoral benign bone lesions in children and recommended surgical procedures: Retrospective analysis of 62 patients. *Arch Orthop Trauma Surg* 2016;136:1051-61. doi: 10.1007/s00402-016-2486-9.
- Jamshidi K, Mirkazemi M, Izanloo A, Mirzaei A. Locking plate and fibular strut-graft augmentation in the reconstruction of unicameral bone cyst of proximal femur in the paediatric population. *Int Orthop* 2018;42:169-74. doi: 10.1007/s00264-017-3648-2.
- Kaelin AJ, MacEwen GD. Unicameral bone cysts. Natural history and the risk of fracture. *Int Orthop* 1989;13:275-82. doi: 10.1007/BF00268511.
- Vasconcellos DA, Yandow SM, Grace AM, Moritz BM, Marley LD, Fillman RR. Cyst index: A nonpredictor of simple bone cyst fracture. *J Pediatr Orthop* 2007;27:307-10. doi: 10.1097/BPO.0b013e31803409e2.
- Zhang K, Wang Z, Zhang Z. Comparison of curettage and bone grafting combined with elastic intramedullary nailing vs curettage and bone grafting in the treatment of long bone cysts in children. *Medicine (Baltimore)* 2019;98:e16152. doi: 10.1097/MD.00000000000016152.
- Roposch A, Saraph V, Linhart WE. Flexible intramedullary nailing for the treatment of unicameral bone cysts in long bones. *J Bone Joint Surg [Am]* 2000;82:1447-53. doi: 10.2106/00004623-200010000-00011.
- Erol B, Onay T, Topkar OM, Tokyay A, Aydemir AN, Okay E. A comparative study for the treatment of simple bone cysts of the humerus: Open curettage and bone grafting either without instrumentation or with intramedullary nailing. *J Pediatr Orthop B* 2017;26:5-13. doi: 10.1097/BPB.0000000000000353.
- Zhang P, Zhu N, Du L, Zheng J, Hu S, Xu B. Treatment of simple bone cysts of the humerus by intramedullary nailing and steroid injection. *BMC Musculoskelet Disord* 2020;21:70. doi: 10.1186/s12891-020-3054-6.
- Glancy GL, Brugioni DJ, Eilert RE, Chang FM. Autograft versus allograft for benign lesions in children. *Clin Orthop Relat Res* 1991(262):28-33.
- Çetin MÜ, Özçelik İB. Treatment of persistent large cystic lesions of the humerus with vascularized fibular grafts. *Jt Dis Relat Surg* 2022;33:426-34. doi: 10.52312/jdrs.2022.578.