



Hidden blood loss in percutaneous endoscopic lumbar discectomy via the posterolateral approach

Jin-wang Liu, MD¹, Shao-xing Li, MD², Fei Wang, MD³, Yun Yang, MD³, Hua Yu, MD¹

¹Department of Orthopaedics, The First Affiliated Hospital of Chengdu Medical College, Sichuan, PR China

²Department of Gynaecology and Obstetrics, The First Affiliated Hospital of Chengdu Medical College, Sichuan, PR China

³Department of Orthopaedics, The Third People's Hospital of Chengdu, Sichuan, PR China

Percutaneous endoscopic lumbar discectomy (PELD) is one of the most complex surgical procedures for the treatment of lumbar disc herniation (LDH).^[1,2] As a minimally invasive spinal surgery, PELD is increasingly recognized for its minimal trauma, rapid recovery, short hospital stay, and satisfactory clinical outcomes. There are three different surgical approaches for PELD: interlaminar, transforaminal, and posterolateral.^[3] Of these, the posterolateral approach (PLA) is best suited for both foraminal and extraforaminal LDH. Furthermore, the operative area of the PLA is Kambin's triangle, making this approach the safest.^[3] Foraminal and extraforaminal LDH often occur simultaneously. In addition, extraforaminal LDH is sometimes combined with intracanal LDH, which in turn develops into two

ABSTRACT

Objectives: The study aimed to evaluate the hidden blood loss (HBL) and its possible risk factors in patients with lumbar disc herniation undergoing percutaneous endoscopic lumbar discectomy (PELD) via posterolateral approach.

Patients and methods: The clinical data of 170 lumbar disc herniation patients (101 males, 69 females; mean age: 57.7±18.0 years; range, 19 to 87 years) treated with PELD via posterolateral approach between January 2021 and January 2023 were retrospectively analyzed. Demographic characteristics, laboratory data, and surgery-related clinical data of the patients were collected, including age, sex, height, weight, body mass index, albumin, blood glucose, hemoglobin (Hb), hematocrit (Hct), American Society of Anesthesiologists (ASA) score, surgical time, number of puncture, and the need for foraminoplasty. Hidden blood loss was calculated, and multiple linear regression analysis was performed to identify risk factors.

Results: The mean Hb in patients with preoperative anemia was 115.8±8.6 g/L. The mean postoperative Hb loss and Hct loss were 7.0±4.5 g/L and 0.02±0.01%, respectively. The mean number of punctures (1-3 punctures vs. >3 punctures) was 2.4±0.7 and 4.6±0.6, respectively. Satisfactory localization was achieved within three punctures in nearly 60% of the patients. More than half (55.3%) of the patients underwent foraminoplasty. The mean surgical time was 110.9±32.0 min. The mean HBL was 178.4±66.5 mL. The mean follow-up time was 6.9±2.2 months. When comparing the preoperative and postoperative incidence of anemia, we found that the incidence of anemia was significantly associated with HBL ($p<0.001$). Multiple linear regression analysis showed that HBL was positively correlated with the number of punctures, foraminoplasty, and surgical time.

Conclusion: Our results suggest that the number of punctures, foraminoplasty, and surgical time are independent risk factors for HBL after PELD via posterolateral approach. Therefore, HBL should not be ignored in patients with these risk factors to ensure patients' safety in the perioperative period.

Keywords: Hidden blood loss, lumbar disc herniation, percutaneous endoscopic lumbar discectomy, posterolateral approach, risk factors.

Received: November 17, 2024

Accepted: December 12, 2024

Published online: December 18, 2024

Correspondence: Yun Yang, MD. Department of Orthopaedics, The Third People's Hospital of Chengdu, Sichuan, PR China.

E-mail: xgz123yy@163.com

Correspondence: Hua Yu, MD. Department of Orthopaedics, The First Affiliated Hospital of Chengdu Medical College, Sichuan, PR China.

E-mail: 18382454549@sina.cn

Doi: 10.52312/jdrs.2025.2065

Citation: Liu JW, Li SX, Wang F, Yang Y, Yu H. Hidden blood loss in percutaneous endoscopic lumbar discectomy via the posterolateral approach. *Jt Dis Relat Surg* 2025;36(1):56-64. doi: 10.52312/jdrs.2025.2065.

©2025 All right reserved by the Turkish Joint Diseases Foundation

This is an open access article under the terms of the Creative Commons Attribution-NonCommercial License, which permits use, distribution and reproduction in any medium, provided the original work is properly cited and is not used for commercial purposes (<http://creativecommons.org/licenses/by-nc/4.0/>).

types of radiculopathy.^[4] Percutaneous endoscopic lumbar discectomy via PLA has potential advantages in these complex cases.^[5,6]

Blood management has always been a crucial aspect of the accelerated recovery surgical concept, as perioperative anemia is strongly associated with surgical complications, including rebleeding, impaired wound healing, and motor deficits.^[7] In addition, postoperative anemia may lead to longer hospital stays and medical complications.^[8] However, in clinical practice, the focus of many surgeons is usually on visible blood loss, such as intraoperative hemorrhage and postoperative drainage, and the presence of hidden blood loss (HBL) is often overlooked. Studies have confirmed that the amount of blood loss due to infiltration in potential compartments or hemolysis is considerable,^[9,10] even in minimally invasive endoscopic spine surgery.^[10] This is despite the fact that technological innovations and the introduction of new instruments have facilitated the development of microsurgery,^[11] offering the possibility of treating patients with poor general condition who require surgery. For spine surgeons, ignoring the presence of HBL may lead to an incorrect estimation of blood loss, particularly in minimally invasive surgery, which may hamper the treatment of anemia-related complications.^[12] Therefore, focusing on HBL can help ensure patient safety throughout the perioperative period.

The concept of HBL was first proposed by Sehat et al.^[13] in 2000. In recent years, HBL has received increasing attention from surgeons. Numerous studies have shown that HBL accounts for a significant portion of total blood loss (TBL) in both open and minimally invasive surgery.^[14-17] Therefore, the study of HBL is of great significance. To the best of our knowledge, there are few reports of HBL after PELD via PLA in the literature.^[18,19] Previous studies have found that HBL in spinal surgery is associated with demographic characteristics (age,^[9,20] weight,^[21] sex,^[22] diabetes mellitus,^[10] and degree of disc degeneration^[22]), laboratory data (patient blood volume, TBL, postoperative hematocrit (Hct), loss of Hct, fibrinogen levels, preoperative platelet levels, and preoperative hemoglobin (Hb)),^[10,20,23-25] and surgery-related clinical data (surgical time).^[17,21] Therefore, this study aimed to evaluate patients with LDH who underwent PELD via PLA and analyze the HBL of these patients. Furthermore, we further explored the risk factors that may affect the HBL of the patients by taking into account the relevant factors reported in the literature.

PATIENTS AND METHODS

One hundred seventy patients (101 males, 69 females; mean age: 57.7±18.0 years; range, 19 to 87 years) who underwent PELD via PLA for LDH at the Third People's Hospital of Chengdu, Department of Orthopaedics between January 2021 and January 2023 were included in this retrospective study. Inclusion criteria were as follows: (i) diagnosed with L4/5 or L5/S1 disc herniation; (ii) received PELD via PLA; (iii) aged 18 years or older. The exclusion criteria were as follows: (i) previous lumbar spine surgery; (ii) hematological diseases, coagulation disorders, long-term oral antiplatelet, or anticoagulant medications; (iii) use of antifibrinolytic drugs (tranexamic acid or aminocaproic acid) during the procedure; (iv) incomplete medical information; (v) intolerance or refusal to undergo surgery. The study protocol was approved by the Third People's Hospital of Chengdu Ethics Committee (date: December 9, 2020, no: 2020-S-13). All patients provided written informed consent. The study was conducted in accordance with the principles of the Declaration of Helsinki.

Patient data were collected from the hospital's electronic medical record system, including demographic characteristics, laboratory data, and surgery-related data. Demographic data included age, sex, height, weight, body mass index, and comorbidities. Laboratory data included Hb, Hct, albumin, and blood glucose. Surgery-related data were mainly extracted from surgical records, including surgical time, number of punctures, the need for foramenoplasty, and American Society of Anesthesiologists (ASA) score. The Hb concentration was used to define anemia (<120 g/L for females; <130 g/L for males).^[26]

All procedures were performed by the same surgical team under nerve block anesthesia according to standard procedures. The procedure was as follows: the patient was placed in the prone position. Under X-ray guidance, the location of the puncture was confirmed and marked by the surgeon, and then the spinal needle was inserted into the target disc level. In the anteroposterior view, the needle tip was located in the medial pedicle line. In the lateral view, the same needle tip was located in the posterior vertebral line. A guidewire was inserted through the spinal needle and the needle was removed. Next, an incision was made, and a tapered cannulated obturator was inserted along the guidewire. An obturator was inserted into the disc with a hammer blow. Afterward, a working

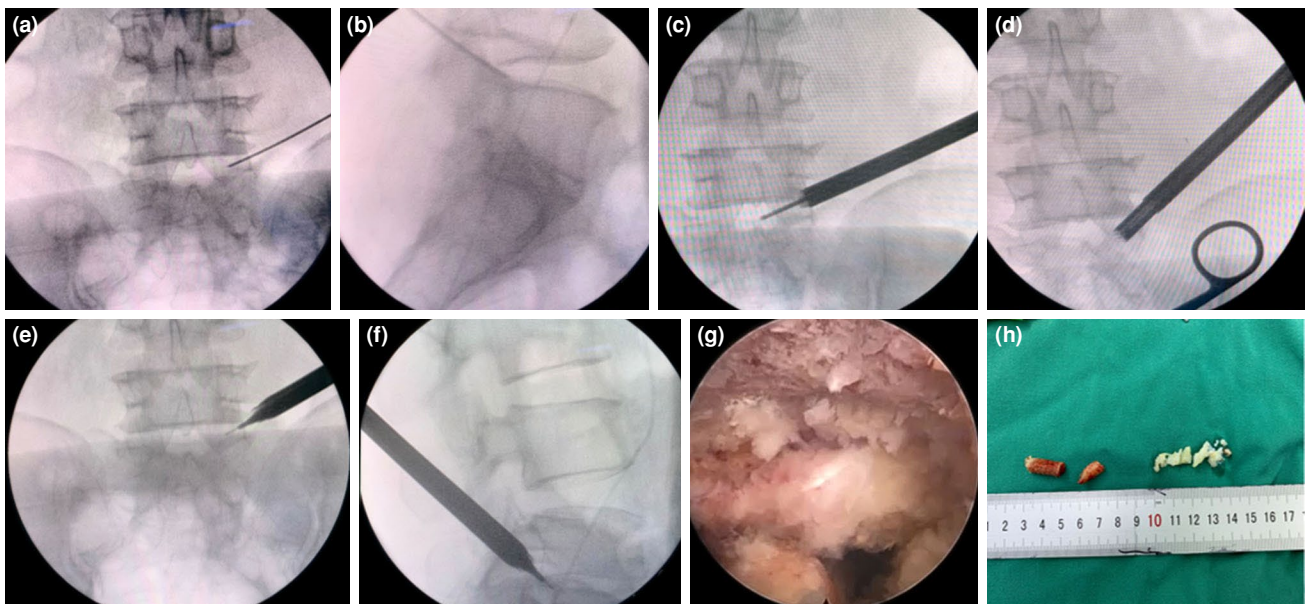


FIGURE 1. Lumbar disc herniation was treated by PELD via PLA (L5/S1 LDH as an example). (a, b) Position of the spinal needle. (c, d) Removal of a portion of the superior articular process by circular sawing. (e, f) Establishment of a working cannula. (g) Endoscopic image showing the relaxation of S1 nerve root after decompression. (h) On the left side of the image was a partial removal of the superior articular process, and on the right side of the image was the removal of the nucleus pulposus.

PELD: Percutaneous endoscopic lumbar discectomy; PLA: Posterolateral approach; LDH: Lumbar disc herniation;

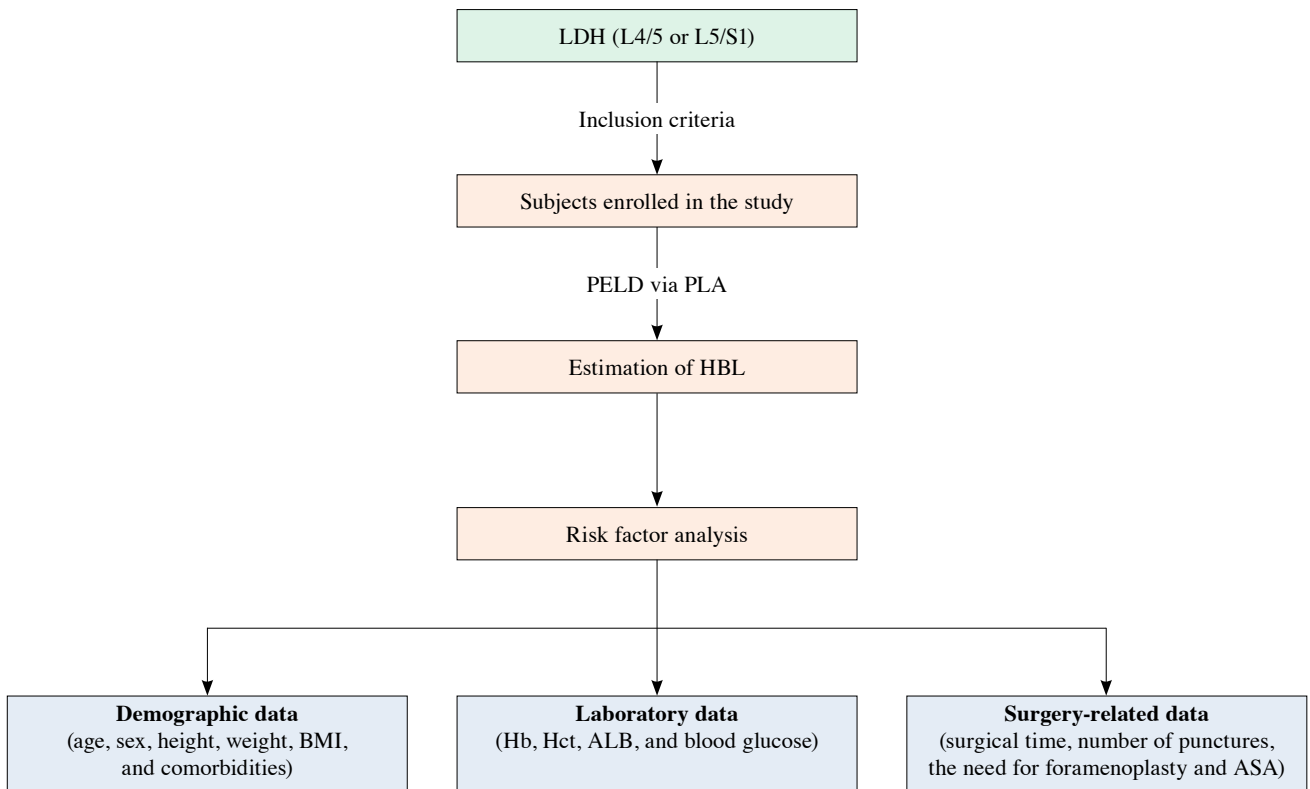


FIGURE 2. Process of inclusion and exclusion of subjects.

LDH: Lumbar disc herniation; PELD: Percutaneous endoscopic lumbar discectomy; PLA: Posterolateral approach; BMI: Body mass index; Hb: Hemoglobin; Hct: Hematocrit; ALB: Albumin; ASA: American Society of Anesthesiologists.

TABLE I
Patient demographics and related factors

| Variables | n | % | Mean±SD |
|-------------------------------------|-----|------|------------|
| Age (year) | | | 57.7±18.0 |
| Sex | | | |
| Male | 101 | 59.4 | |
| Female | 69 | 40.6 | |
| Height (m) | | - | 1.62±0.08 |
| Weight (kg) | | - | 53.9±5.7 |
| BMI (kg/m ²) | | - | 20.6±2.4 |
| Smoking | 23 | 13.5 | |
| Comorbidities | | | |
| Hypertension | 25 | 14.7 | |
| Diabetes mellitus | 57 | 33.5 | |
| CHD | 17 | 10.0 | |
| Preoperative Hb (g/L) | | | 124.4±10.5 |
| Postoperative Hb (g/L) | | | 117.4±11.8 |
| Hb loss (g/L) | | | 7.0±4.5 |
| Preoperative Hct (ratio) | | | 0.36±0.04 |
| Postoperative Hct (ratio) | | | 0.34±0.04 |
| Hct loss (ratio) | | | 0.02±0.01 |
| Preoperative ALB (g/L) | | | 34.8±4.8 |
| Preoperative blood glucose (mmol/L) | | | 5.91±1.28 |
| ASA classification | | | |
| I | 17 | 10.0 | |
| II | 127 | 74.7 | |
| III | 26 | 15.3 | |
| Hb of preoperative anemia (g/L) | | | 115.8±8.6 |
| Preoperative anemia | | | |
| Yes | 73 | 42.9 | |
| No | 97 | 57.1 | |
| Hb of postoperative anemia (g/L) | | | 110.5±10.0 |
| Postoperative anemia | | | |
| Yes | 99 | 58.2 | |
| No | 71 | 41.8 | |
| Number of puncture | | | |
| 1~3 | 99 | 58.2 | |
| >3 | 71 | 41.8 | |
| Foraminoplasty | | | |
| Yes | 94 | 55.3 | |
| No | 76 | 44.7 | |
| Surgical time (min) | | | 110.9±32.0 |
| HBL (mL) | | | 178.4±66.5 |
| Blood transfusion | | | |
| Yes | 0 | 0 | |
| No | 170 | 100 | |
| Follow-up duration (month) | | | 6.9±2.2 |
| Total | 170 | 100 | |

SD: Standard deviation; BMI: Body mass index; CHD: Coronary heart disease; Hb: Hemoglobin; Hct: Hematocrit; ALB: Albumin; ASA: American Society of Anesthesiologists; HBL: Hidden blood loss; Hb loss = Preoperative Hb - Postoperative Hb; Hct loss = Preoperative Hct - Postoperative Hct; Data are presented as mean ± SD.

| | Mean±SD | SE | 95% CI of the difference | | t | p |
|---|-------------|-------|--------------------------|-------|--------|--------|
| | | | Lower | Upper | | |
| Hb loss | 7.0±4.5 | 0.346 | 6.281 | 7.648 | 20.122 | <0.001 |
| Hct loss | 0.017±0.007 | 0.001 | 0.016 | 0.018 | 33.273 | <0.001 |
| Anemia _{pre} -anemia _{post} | 0.153±0.361 | 0.028 | 0.098 | 0.208 | 5.524 | <0.001 |

CI: Confidence interval; SD: Standard deviation; SE: Standard error; Hb: Hemoglobin; Hct: Hematocrit; Hb loss = Preoperative Hb - Postoperative Hb; Hct loss= Preoperative Hct - Postoperative Hct. Pre and postoperative presence of anaemia was set as 1 and pre and postoperative absence of anaemia was set as 2.

cannula was inserted. Finally, an endoscope was inserted through the working cannula, and the herniated disc was removed with endoscopic forceps and a radiofrequency probe (Figure 1). The need for foraminoplasty was determined intraoperatively, a procedure that was accomplished primarily by removing a portion of the superior articular process and surrounding soft tissues (Figures 1e, f, h). Wound drainage was not performed in all patients. No patients received blood transfusion during the perioperative period. Since there was very little visible blood loss during surgery, this portion of blood loss was negligible; therefore, HBL was approximately equal to TBL. All patients underwent complete blood counts on the third day after surgery. At this time, the patient's hemodynamics were stable, and fluid shifts were essentially complete.^[27]

The patient's preoperative blood volume (PBV) was first calculated using Nadler et al.'s^[28] formula: $PBV (L) = k_1 \times \text{height (m)}^3 + k_2 \times \text{weight (kg)} + k_3$. For males, k_1 was 0.3669, k_2 was 0.03219, and k_3 was 0.6041, while for females, k_1 was 0.3561, k_2 was 0.03308, and k_3 was 0.1833. Total blood loss was then calculated by multiplying the change in Hct by PBV according to Gross^[29] formula:

$TBL (L) = PBV (L) \times (Hct_{pre} - Hct_{post}) / Hct_{ave}$, where Hct_{pre} was the initial preoperative Hct, Hct_{post} was the Hct on the third postoperative day, and Hct_{ave} was the mean of Hct_{pre} and Hct_{post} .

Statistical analysis

All data were analyzed using IBM SPSS version 19.0 software (IBM Corp., Armonk, NY, USA). Pearson correlation coefficient analysis (for normally distributed data), Spearman correlation coefficient analysis (for nonnormally distributed data), multiple linear regression analysis, and analysis of variance were performed to determine independent risk factors associated with HBL. A p-value <0.05 was considered statistically significant.

RESULTS

The flowchart of the study is demonstrated in Figure 2. The mean body mass index was 20.6 ± 2.4 kg/m². About one-third (33.5%) of the patients had comorbid diabetes. The mean follow-up time was 6.9 ± 2.2 months. Other demographic data are summarized in Table I.

Hemoglobin decreased from 124.4 ± 10.5 g/L preoperatively to 117.4 ± 11.8 g/L postoperatively, with a mean Hb loss of 7.0 ± 4.5 g/L. Hematocrit decreased from 0.36 ± 0.04 preoperatively to

| Variables | p | Correlation |
|----------------------------|--------|-------------|
| Age | 0.972 | 0.003 |
| Sex | 0.455 | 0.058 |
| Height | 0.575 | 0.043 |
| Weight | 0.254 | 0.088 |
| Body mass index | 0.472 | 0.056 |
| Smoking | 0.801 | 0.019 |
| Hypertension | 0.482 | -0.054 |
| Diabetes mellitus | 0.777 | -0.022 |
| Coronary heart disease | 0.472 | 0.061 |
| Preoperative Hb | 0.177 | -0.104 |
| Preoperative Hct | 0.140 | -0.114 |
| Preoperative albumin | 0.982 | -0.002 |
| Preoperative blood glucose | 0.122 | -0.119 |
| ASA classification | 0.380 | 0.068 |
| Preoperative anemia | 0.360 | -0.071 |
| Surgical time | <0.001 | 0.791 |
| Number of puncture | <0.001 | 0.577 |
| Foraminoplasty | <0.001 | -0.764 |

HBL: Hidden blood loss; Hb: Hemoglobin; Hct: Hematocrit; ASA: American society of Anesthesiologists.

| TABLE IV | | | | | |
|--|---------|--------|---------|--------|--------|
| Multiple linear regression analysis of influencing factors on HBL following PELD via PLA | | | | | |
| Independent variables | B value | SE | β | t | p |
| Constant | 112.538 | 21.104 | - | 5.333 | <0.001 |
| Number of puncture | 20.583 | 6.397 | 0.153 | 3.218 | 0.002 |
| Foraminoplasty | -49.759 | 7.029 | -0.373 | -7.079 | <0.001 |
| Surgical time | 0.980 | 0.115 | 0.471 | 8.498 | <0.001 |

HBL: Hidden blood loss; PELD: Percutaneous endoscopic lumbar discectomy; PLA: Posterolateral approach; SE: Standard deviation; $R^2=0.737$, adjusted $R^2=0.732$, $F=155.039$, $p<0.001$; In the qualitative variables, puncture of 1~3 and foraminoplasty were set as "1." Puncture of >3 and nonforaminoplasty were set as "2."

0.34±0.04 postoperatively, with a mean Hct loss of 0.02±0.01%. Mean preoperative albumin was 34.8±4.8 g/L. More than 50% of patients underwent foraminoplasty. The mean number of punctures was 3.3±1.3, with 41.8% of patients having more than three punctures (Table I).

The mean surgical time was 110.9±32.0 min. The mean HBL was 178.4±66.5 mL. Twenty-six patients without anemia preoperatively developed anemia postoperatively (Table I). The difference between preoperative and postoperative anemia showed that HBL could significantly increase the number of postoperative anemia patients (Table II). Despite this, none of the patients required blood transfusion during the perioperative period.

Pearson and Spearman correlation analysis showed that surgical time, number of punctures, and foraminoplasty were associated with HBL ($p<0.001$; Table III). We used multiple linear regression analysis to examine the relationship between HBL and the risk factors. As shown in Table IV, surgical time, number of punctures, and foraminoplasty were positively correlated with HBL.

DISCUSSION

The PELD technique via PLA has developed rapidly and gained recognition in recent years due to its significant minimally invasive advantages. The technique is minimally invasive, with a skin incision of approximately 6 to 8 mm, and intraoperative visible blood loss is low. Therefore, many spine surgeons consider the blood loss in this procedure to be negligible. A retrospective study found that perioperative HBL for percutaneous endoscopic transforaminal discectomy was 341.04±191.15 mL, which was much higher than visible blood loss (85.04±26.53 mL).^[22] Zhuang et al.^[18] compared the HBL of three lumbar endoscopic surgeries for the treatment of single-segment LDH. They

found that the mean HBL was 381.87±218.01 mL in the unilateral biportal endoscopic discectomy (UBE) group, 252.05±118.44 mL in the percutaneous endoscopic transforaminal discectomy group, and 229.63±143.9 mL in the percutaneous endoscopic interlaminar discectomy group. Jiang et al.^[19] found that the HBL of PELD in the treatment of single-segment LDH was 30.64±22.29 mL, which accounted for nearly 70% of TBL (43.68±24.54 mL). In addition, they found that the HBL of PELD was much lower than that of UBE (332.10±190.17 mL). In our study, the mean perioperative HBL and Hb loss was 178.4 mL and 7.0 g/L, respectively. Although the amount of HBL found in the studies varied, they all illustrated that HBL accounted for a considerable amount of TBL, sometimes exceeding visible blood loss. The variation in HBL was related to the surgical approach, surgical procedure, and calculation method of HBL. In addition, we noted that 26 patients with normal preoperative Hb developed anemia postoperatively. These numbers were much higher than the extremely small amount of intraoperative visible blood loss. In elderly patients, particularly if anemia is already present preoperatively, additional HBL in the perioperative period increases the incidence of adverse events. Given the potential adverse effects of anemia, such patients must be closely monitored after surgery.

Several studies have found that HBL occurs due to intraoperative extravasation of blood into tissues and hemolysis.^[13,17] However, the risk factors associated with the amount of HBL have not been clarified. In this study, we used multiple linear regression analysis to examine the associated factors. This study suggests that the amount of HBL was more in patients with a high number of punctures, the need for foraminoplasty, and a long surgical time.

A retrospective study found a positive correlation between HBL and the number of puncture in

percutaneous vertebroplasty for osteoporotic vertebral compression fractures ($p=0.002$).^[17] Not surprisingly, a greater number of punctures resulted in more soft tissue damage and HBL. Our study found HBL with more than three punctures was significantly higher than HBL with less than three punctures. Therefore, the location and puncture point of the foramen were marked by fluoroscopy on the body surface, and the route of the needle was selected according to the position of the herniated disc. Preoperatively, the patient's imaging data were carefully read to roughly determine the depth of the puncture. These preoperative plans help to reduce excessive HBL from repeated punctures during intraoperative puncture positioning of spinal needle.

Jiang et al.^[19] found that the HBL in the PELD group was significantly lower than that in the UBE group, mainly because PELD utilizes the existing natural access to the intervertebral foramina without the need to remove the lamina and ligamentum flavum. However, in the UBE technique, partial laminectomy may lead to hemorrhage of cancellous bone.^[19] Similar conclusions were found by Wang et al.^[30] who suggested that bone surface bleeding is an influential factor in the increase of HBL in the perioperative period of UBE. Therefore, we hypothesized that foraminoplasty caused partial damage to the superior articular process and surrounding tissues, and the triggered bleeding leaked into the tissue space. While bleeding from soft tissues may be stopped by radiofrequency electrodes, achieving hemostasis for bleeding from bony surfaces is difficult with this method. If there is more bleeding from the bony surface, hemostasis can be achieved by bone wax. For certain types of herniated discs, such as extraforaminal or extreme lateral types, foraminoplasty is not required. Therefore, an appropriate preoperative surgical strategy needs to be developed based on the patient's presentation in conjunction with imaging evidence.

It is easy to determine that HBL is directly related to surgical time.^[17,18,30] Increased surgical time markedly increases the amount of blood flowing into the tissue spaces and dead space, leading to increased HBL. Therefore, preoperative optimization of the surgical procedure and anticipation of possible risks and contingency plans are required. As we mainly used nerve block anesthesia for the surgery, some patients had a poor experience due to severe intraoperative pain and could not cooperate well, which ultimately led to prolonged surgery time. For such cases, local anesthesia can be strengthened; for

example, 0.5% ropivacaine can be used to complete local infiltration anesthesia from shallow to deep layers, up to the articular capsule of the articular process. In addition, prolonged prone position can affect the intra-abdominal pressure and increase epidural vein bleeding.^[31] Therefore, the abdomen should be kept empty intraoperatively to avoid pressure.

Therefore, spinal orthopedic surgeons should take a series of measures to reduce HBL. In addition to some conventional means of hemostasis, such as absorbable gelatin sponges and other hemostatic materials,^[32,33] intraoperative electrode prehemostasis is also crucial. Some studies have also recommended the use of tranexamic acid, which can effectively reduce HBL.^[34-37] In addition G-arm for fluoroscopic localization of the body surface helps to reduce surgical time. It has also been found that PELD produced less HBL in the treatment of single-segment LDH compared to UBE.^[18,19] This may be another unique advantage of PELD. However, the advantage of PELD in reducing HBL over percutaneous endoscopic interlaminar discectomy was not obvious.^[18] Of course, the mentioned studies are single-center retrospective studies with small sample sizes, and each endoscopic technique has its specific indications. More extensive multicenter prospective studies are needed in the future to investigate the role of different endoscopic techniques in reducing HBL.

This study had several limitations. The study was retrospective in design, and the number of patients included in the study was small. Hidden blood loss assessment was based on Hct on the third day after surgery, assuming that fluid shifts would have been completed at this time. However, if this was not the case, it could have resulted in a low HBL. In addition, we ignored the very small amount of intraoperative visible blood loss, which may have led to an overestimation of HBL. Future prospective studies with large samples and multiple centers are needed to further validate our findings.

In conclusion, the current study suggests that HBL is much larger than previously considered in PELD via PLA. Spine surgeons should pay close attention to HBL, particularly in cases involving high number of punctures, foraminoplasty, and a long surgical time, to ensure patients' safety.

Data Sharing Statement: The data that support the findings of this study are available from the corresponding author upon reasonable request.

Author Contributions: Conception and design: F.W., Y.Y.; Collection and assembly of data: Y.Y.; Analysis and interpretation of the data, drafting of the article: J.L., S.L.; Statistical expertise: H.Y., S.L.; Critical revision of the article for important intellectual content: H.Y., Y.Y. All authors read and approved the final manuscript.

Conflict of Interest: The authors declared no conflicts of interest with respect to the authorship and/or publication of this article.

Funding: The authors received no financial support for the research and/or authorship of this article.

REFERENCES

- Sairy K, Egawa H, Matsuura T, Takahashi M, Higashino K, Sakai T, et al. State of the art: Transforaminal approach for percutaneous endoscopic lumbar discectomy under local anesthesia. *J Med Invest* 2014;61:217-25. doi: 10.2152/jmi.61.217.
- Choi G, Lee SH, Deshpande K, Choi H. Working channel endoscope in lumbar spine surgery. *J Neurosurg Sci* 2014;58:77-85.
- Yokosuka J, Oshima Y, Kaneko T, Takano Y, Inanami H, Koga H. Advantages and disadvantages of posterolateral approach for percutaneous endoscopic lumbar discectomy. *J Spine Surg* 2016;2:158-66. doi: 10.21037/jss.2016.09.03.
- Paolini S, Ciappetta P, Raco A, Missori P, Delfini R. Combined intra-extracanal approach to lumbosacral disc herniations with bi-radicular involvement. Technical considerations from a surgical series of 15 cases. *Eur Spine J* 2006;15:554-8. doi: 10.1007/s00586-004-0862-6.
- Yeung AT. The evolution and advancement of endoscopic foraminal surgery: One surgeon's experience incorporating adjunctive technologies. *SAS J* 2007;1:108-17. doi: 10.1016/SASJ-2006-0014-RR.
- Yang JS, Re: Choi KC, Park CK. Percutaneous endoscopic lumbar discectomy for L5-S1 disc herniation: Consideration of the relation between the iliac crest and L5-S1 disc. *Pain Physician* 2019;22:E241-4.
- Lange N, Stadtmüller T, Scheibel S, Reischer G, Wagner A, Meyer B, et al. Analysis of risk factors for perioperative complications in spine surgery. *Sci Rep* 2022;12:14350. doi: 10.1038/s41598-022-18417-z.
- Sachdeva I, Carmouche JJ. Postoperative anemia predicts length of stay for geriatric patients undergoing minimally invasive lumbar spine fusion surgery. *Geriatr Orthop Surg Rehabil* 2020;11:2151459320911874. doi: 10.1177/2151459320911874.
- Raitio A, Heiskanen S, Soini V, Helenius L, Syvänen J, Helenius I. Hidden blood loss and bleeding characteristics in children with congenital scoliosis undergoing spinal osteotomies. *Int Orthop* 2024;48:1569-77. doi: 10.1007/s00264-024-06090-y.
- Li J, Zhang T. Comparison of clinical outcomes and complications of biportal and uniportal endoscopic decompression for the treatment of cervical spondylotic radiculopathy: A systematic review and meta-analysis. *Jt Dis Relat Surg* 2024;35:583-93. doi: 10.52312/jdrs.2024.1820.
- Lewandrowski KU, Ferrara L, Cheng B. Expandable interbody fusion cages: An editorial on the surgeon's perspective on recent technological advances and their biomechanical implications. *Int J Spine Surg* 2020;14:S56-62. doi: 10.14444/7127.
- Zhu L, Zhang L, Shan Y, Feng X, Zhang W. Analysis of hidden blood loss and its risk factors in oblique lateral interbody fusion surgery. *Clin Spine Surg* 2021;34:E501-5. doi: 10.1097/BSD.0000000000001177.
- Sehat KR, Evans R, Newman JH. How much blood is really lost in total knee arthroplasty? Correct blood loss management should take hidden loss into account. *Knee* 2000;7:151-5. doi: 10.1016/s0968-0160(00)00047-8.
- Yang Y, Wang F. Hidden blood loss in unilateral open-door cervical laminoplasty for multilevel cervical spondylotic myelopathy. *Jt Dis Relat Surg* 2024;35:293-8. doi: 10.52312/jdrs.2024.1439.
- Sasagawa T, Takeuchi Y, Aita I. Postoperative blood loss including hidden blood loss in early and late surgery using percutaneous pedicle screws for traumatic thoracolumbar fracture. *Spine Surg Relat Res* 2020;5:171-5. doi: 10.22603/ssr.2020-0152.
- Hu M, Zhang Y, Zhao WJ, Liu X, Shi PZ, Wang JW, et al. Perioperative hidden blood loss in lumbar disk herniation patients with percutaneous endoscopic transforaminal discectomy and influencing factors. *Clin Spine Surg* 2022;35:E438-43. doi: 10.1097/BSD.0000000000001282.
- Yang Y, Peng YX. Hidden blood loss and its risk factors in percutaneous vertebroplasty surgery for osteoporotic vertebral compression fractures. *Arch Orthop Trauma Surg* 2023;143:5575-81. doi: 10.1007/s00402-023-04873-3.
- Zhuang H, Li J, Guo S, An N, Fan Z, Tan H, et al. Hidden blood loss in three different endoscopic spinal procedures for lumbar disc herniation. *Ann Med Surg (Lond)* 2024;86:655-9. doi: 10.1097/MS9.0000000000001644.
- Jiang HW, Chen CD, Zhan BS, Wang YL, Tang P, Jiang XS. Unilateral biportal endoscopic discectomy versus percutaneous endoscopic lumbar discectomy in the treatment of lumbar disc herniation: A retrospective study. *J Orthop Surg Res* 2022;17:30. doi: 10.1186/s13018-022-02929-5.
- Zhou Y, Fu X, Yang M, Ke S, Wang B, Li Z. Hidden blood loss and its possible risk factors in minimally invasive transforaminal lumbar interbody fusion. *J Orthop Surg Res* 2020;15:445. doi: 10.1186/s13018-020-01971-5.
- Kolz JM, Neal KM. Hidden blood loss in adolescent idiopathic scoliosis surgery. *Orthop Traumatol Surg Res* 2022;108:103216. doi: 10.1016/j.otsr.2022.103216.
- Hu M, Zhang Y, Zhao WJ, Liu X, Shi PZ, Wang JW, et al. Perioperative hidden blood loss in lumbar disk herniation patients with percutaneous endoscopic transforaminal discectomy and influencing factors. *Clin Spine Surg* 2022;35:E438-43. doi: 10.1097/BSD.0000000000001282.
- Lei F, Li Z, He W, Tian X, Zheng L, Kang J, et al. Hidden blood loss and the risk factors after posterior lumbar fusion surgery: A retrospective study. *Medicine (Baltimore)* 2020;99:e20103. doi: 10.1097/MD.00000000000020103.
- Yang JH, Kim HJ, An M, Suh SW, Chang DG. Hidden blood loss and its risk factors for oblique lumbar interbody fusion. *J Clin Med* 2024;13:1454. doi: 10.3390/jcm13051454.
- Khshab M, Alswat MM, Samman AT, Elkhalfi M. Hidden blood loss in transforaminal lumbar interbody fusion: An analysis of underlying factors. *Cureus* 2023;15:e35126. doi: 10.7759/cureus.35126.
- Beghé C, Wilson A, Ershler WB. Prevalence and outcomes of anemia in geriatrics: A systematic review of the literature. *Am J Med* 2004;116 Suppl 7A:3S-10S. doi: 10.1016/j.amjmed.2003.12.009.

27. Sehat KR, Evans RL, Newman JH. Hidden blood loss following hip and knee arthroplasty. Correct management of blood loss should take hidden loss into account. *J Bone Joint Surg Br* 2004;86:561-5.
28. Nadler SB, Hidalgo JH, Bloch T. Prediction of blood volume in normal human adults. *Surgery* 1962;51:224-32.
29. Gross JB. Estimating allowable blood loss: corrected for dilution. *Anesthesiology* 1983;58:277-80. doi: 10.1097/00000542-198303000-00016.
30. Wang H, Wang K, Lv B, Li W, Fan T, Zhao J, et al. Analysis of risk factors for perioperative hidden blood loss in unilateral biportal endoscopic spine surgery: A retrospective multicenter study. *J Orthop Surg Res* 2021;16:559. doi: 10.1186/s13018-021-02698-7.
31. Mastracci TM, Bhandari M, Mundi R, Rizoli SB, Nascimento BA, Schreiber M; Evidence-Based Reviews in Surgery Group. Operative blood loss, blood transfusion and 30-day mortality in older patients after major noncardiac surgery. *Can J Surg* 2012;55:426-8. doi: 10.1503/cjs.025212.
32. Wu J, Jin Y, Zhang J, Shao H, Yang D, Chen J. Hemostatic techniques following multilevel posterior lumbar spine surgery: A randomized control trial. *J Spinal Disord Tech* 2014;27:442-6. doi: 10.1097/BSD.0000000000000063.
33. Xu D, Ren Z, Chen X, Zhuang Q, Sheng L, Li S. A randomized controlled trial on effects of different hemostatic sponges in posterior spinal fusion surgeries. *BMC Surg* 2016;16:80. doi: 10.1186/s12893-016-0197-3.
34. Wang W, Duan K, Ma M, Jiang Y, Liu T, Liu J, et al. Tranexamic Acid decreases visible and hidden blood loss without affecting prethrombotic state molecular markers in transforaminal thoracic interbody fusion for treatment of thoracolumbar fracture-dislocation. *Spine (Phila Pa 1976)* 2018;43:E734-9. doi: 10.1097/BRS.0000000000002491.
35. Mu X, Wei J, Wang C, Ou Y, Yin D, Liang B, et al. Intravenous administration of tranexamic acid significantly reduces visible and hidden blood loss compared with its topical administration for double-segment posterior lumbar interbody fusion: A single-center, placebo-controlled, randomized trial. *World Neurosurg* 2019;122:e821-7. doi: 10.1016/j.wneu.2018.10.154.
36. Zhang Y, Zhao W, Hu M, Liu X, Peng Q, Meng B, et al. The efficacy and safety of topical saline irrigation with tranexamic acid on perioperative blood loss in patients treated with percutaneous endoscopic interlaminar discectomy: A retrospective study. *J Neurol Surg A Cent Eur Neurosurg* 2024;85:280-7. doi: 10.1055/s-0043-1769127.
37. Sun H, Deng L, Deng J, Wang J, Zhang H, Chen K, et al. The efficacy and safety of prophylactic intravenous tranexamic acid on perioperative blood loss in patients treated with posterior lumbar interbody fusion. *World Neurosurg* 2019;125:e198-204. doi: 10.1016/j.wneu.2019.01.040.