








# Comparison of histopathological and biomechanical changes of ligamentum mucosum in patients with anterior cruciate ligament rupture

Yalçın Turhan, MD<sup>1</sup>, Mehmet Arıcan, MD<sup>2</sup>, Zekeriya Okan Karaduman, MD<sup>2</sup>,  
Mehmet Ali Sungur, MD<sup>3</sup>, Mehmet Gamsızkan, MD<sup>4</sup>

<sup>1</sup>Department of Orthopedics and Traumatology, Health Sciences University, Bilkent City Hospital, Ankara, Türkiye

<sup>2</sup>Department of Orthopedics and Traumatology, Düzce University Faculty of Medicine, Düzce, Türkiye

<sup>3</sup>Department of Biostatistics and Medical Informatics, Düzce University Faculty of Medicine, Düzce, Türkiye

<sup>4</sup>Department of Pathology, Düzce University Faculty of Medicine, Düzce, Türkiye

Ligamentum mucosum (LM) is located in the synovial layer of the knee joint. This ligamentous structure originates from the intercondylar notch of the femur and inserts to the infrapatellar fat pad (IFP), also known as Hoffa's fat pad.<sup>[1]</sup> In some cases, LM partially or completely attaches to the anterior cruciate ligament (ACL).<sup>[2]</sup>

Recent studies have shown the importance of the LM as a significant contributor to the stability of the knee joint.<sup>[3]</sup> Although LM has been originated from the synovial membrane, its dense connective tissue content is similar with the other ligaments of the knee joint.<sup>[4]</sup> Previous

## ABSTRACT

**Objectives:** The aim of this study was to identify the biomechanical and histopathological changes of ligamentum mucosum (LM) in patients with intact versus ruptured anterior cruciate ligament (ACL).

**Patients and methods:** A total of 67 patients (45 males, 22 females; mean age: 33.2±7.9 years; range, 18 to 45 years) who underwent arthroscopic knee surgery for intraarticular pathologies between July 2022 and January 2023 were prospectively analyzed. The patients with LM were divided into two groups as the ACL intact group (n=31) and ACL ruptured group (n=36). Biomechanical tests and histopathological examinations were performed in all LM patients.

**Results:** Age and body mass index distributions were similar between the groups (p>0.05). Peak force values of the LM in the ACL ruptured group were significantly higher than the ACL intact group (p=0.037). No significant difference was found between the groups in terms of collagen index (p=0.103) and fibroblast count (p=0.821).

**Conclusion:** The peak force values of the LM were significantly higher in the ACL ruptured group as compared to the ACL intact group, which is probably due to the adaptation of LM in patients with ACL rupture against increased deforming forces to maintain knee stability.

**Keywords:** Anterior cruciate ligament, arthroscopy, infrapatellar plica, knee, ligamentum mucosum, rupture.

Received: March 20, 2024

Accepted: May 28, 2024

Published online: July 08, 2024

**Correspondence:** Yalçın Turhan, MD. Sağlık Bilimleri Üniversitesi, Bilkent Şehir Hastanesi, Ortopedi ve Travmatoloji Anabilim Dalı, 06700 Çankaya, Ankara, Türkiye.

E-mail: yturhan\_2000@yahoo.com

Doi: 10.52312/jdrs.2024.1761

**Citation:** Turhan Y, Arıcan M, Karaduman ZO, Sungur MA, Gamsızkan M. Comparison of histopathological and biomechanical changes of ligamentum mucosum in patients with anterior cruciate ligament rupture. Jt Dis Relat Surg 2024;35(3):610-617. Doi: 10.52312/jdrs.2024.1761.

©2024 All right reserved by the Turkish Joint Diseases Foundation

This is an open access article under the terms of the Creative Commons Attribution-NonCommercial License, which permits use, distribution and reproduction in any medium, provided the original work is properly cited and is not used for commercial purposes (<http://creativecommons.org/licenses/by-nc/4.0/>).

biomechanical studies have reported that LM has a protective role against anterior subluxation of the IFP<sup>[5]</sup> and stabilizes the knee joint, menisci, patella, and the ligaments.<sup>[6]</sup> Another study found that the IFP contributed to the neovascularization process following ACL reconstruction.<sup>[7]</sup> This neovascularization theory was also supported by

another study which identified the robust arterial blood supply to the IFP and LM.<sup>[8]</sup>

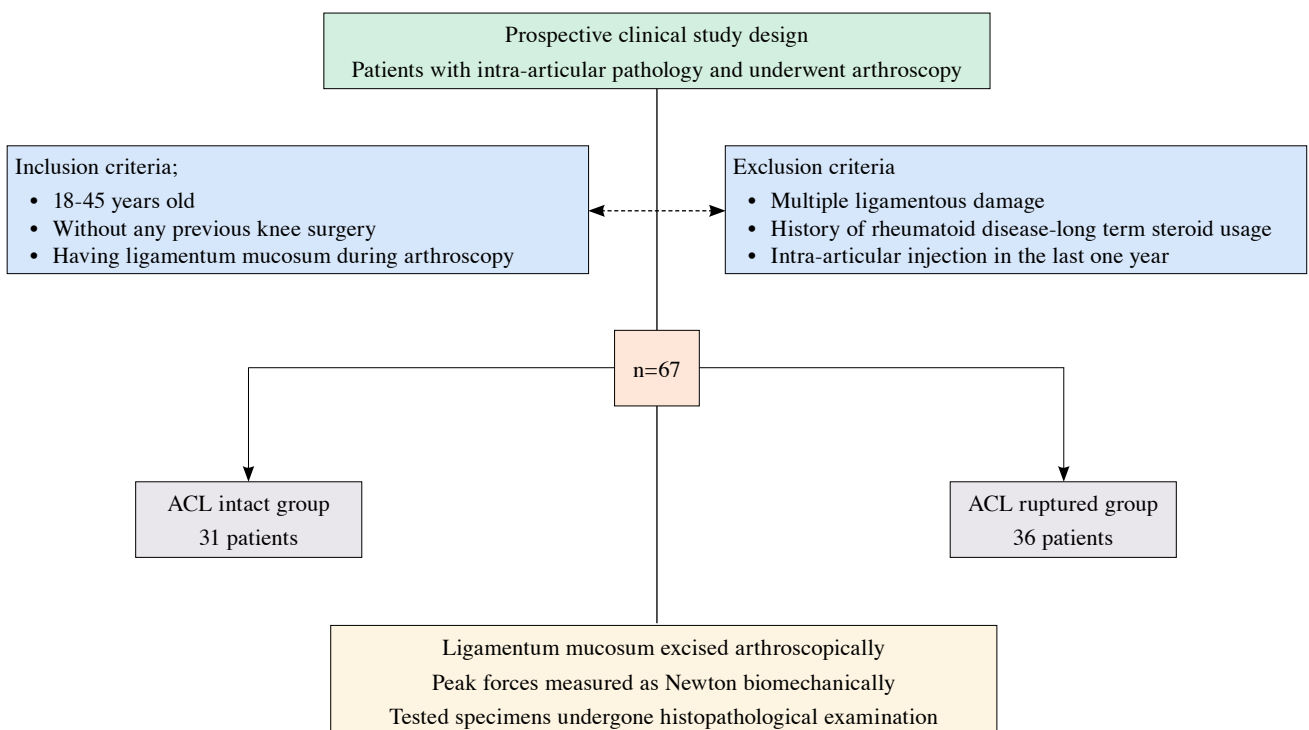
Currently, clinical significance of the LM is recognized well; however, most of the previous studies are mainly focused on its potential involvement in the anterior knee pain and its anatomical and immunohistochemical structures.<sup>[9]</sup> Its role in anterior knee pain is not fully proven and most of these studies still remain hypothetical.<sup>[2]</sup> Implications about the association of LM with anterior knee pain are mostly based on cadaveric studies and small case series. Considering what is known about this ligament, we hypothesized that mechanical strength of the LM increased, as an adaptation to the ACL rupture. In the present study, we, therefore, aimed to investigate the biomechanical and histological changes in LM in patients with ACL rupture compared to the patients with intact ACL.

## PATIENTS AND METHODS

### Study design and study population

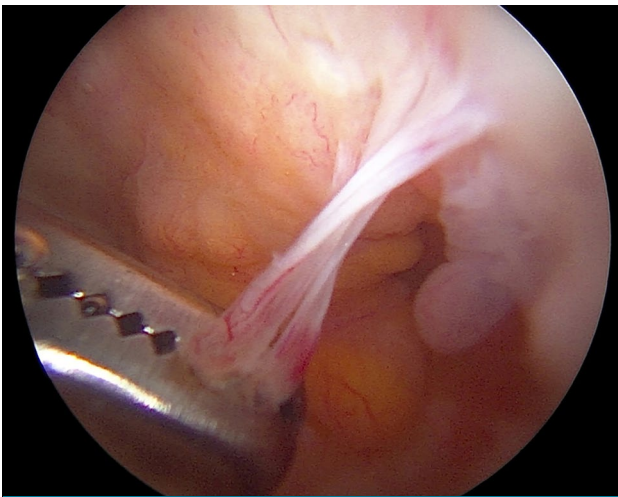
This single-center, prospective clinical study was conducted at Düzce University Faculty of Medicine, Department of Orthopedics and Traumatology

between July 2022 and January 2023. Patients with a complaint of knee pain who underwent arthroscopic intervention due to intraarticular knee pathologies were evaluated. All the patients underwent a detailed knee examination in the outpatient setting. Additionally, anteroposterior and lateral knee joint radiographs were obtained. Magnetic resonance imaging (MRI) of the knee joint was taken in patients with suspected intraarticular pathology after clinical examination. Arthroscopic intervention was performed under general anesthesia in patients with intraarticular pathologies. Inclusion criteria were as follows: age between 18 and 45 years; having no previous knee surgery, and having LM structure visualized during the arthroscopy. Exclusion criteria were as follows: having previous knee surgery, multiple ligamentous injury, history of rheumatoid joint disease, any intraarticular injection in the past one year, and long-term use of corticosteroids. Finally, a total of 67 patients (45 males, 22 females; mean age:  $33.2 \pm 7.9$  years; range, 18 to 45 years) were included in the study. Patients having LM with an intact and ruptured ACL were included in the ACL intact group ( $n=31$ ) and ACL ruptured group ( $n=36$ ), respectively. The study flowchart is shown in Figure 1.



**FIGURE 1.** Flow diagram of the study.

ACL: Anterior cruciate ligament rupture.




**FIGURE 2.** Arthroscopic view of the ligamentum mucosum, the distal end of the ligament was held with grasper after revealing with the help of shaver and punches.

Data including demographic characteristics of the patients such as age, sex, and body mass index (BMI) and operative and postoperative data were recorded.

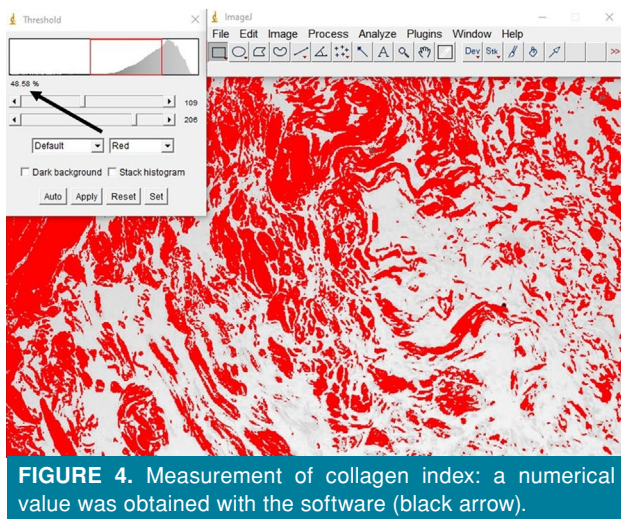
### Operative technique

All operations were performed under general anesthesia with a pneumatic tourniquet application to the thigh. Routine knee arthroscopy portals (anteromedial [AM] and anterolateral [AL]) were used for the diagnostic purposes. A detailed knee joint examination was performed arthroscopically and in addition to joint pathologies, presence or absence of the LM was also examined. In patients having LM, an additional accessory lateral portal was opened, and the LM was revealed with the help of arthroscopic shaver and excised by small arthroscopic punches and scissors at the proximal and distal attachments before the applications of other surgical procedures for the concomitant intraarticular pathologies (Figure 2). The excised LM was sutured at both ends with 2/0 non-absorbable, braided ethylene terephthalate suture (Ethibond™; Ethicon Inc., NJ, USA). The LM specimens were, then, kept hydrated using a saline solution (0.9% saline). If necessary, following surgical procedures were performed: anatomical ACL reconstruction with hamstring autografts, meniscal repair or debridement, and micro/nano fracture.



**FIGURE 3.** (a) Specimen was rigidly secured within testing machine and an initial load of 1 N was applied to get an enough strain at the ligament. (b) Ligament was loaded under tension to failure at a rate of 1 millimeter per second. The peak force just before the failure was calculated by the machine.

N: Newton.



**FIGURE 4.** Measurement of collagen index: a numerical value was obtained with the software (black arrow).

### Biomechanical testing

The specimens were kept in a saline solution before biomechanical testing and all the tests were performed immediately after the surgery. The specimens were rigidly secured within a single column material testing machine model BMT-ES, (BESMAK, Ankara Türkiye). An initial load of 1 N was applied to obtain adequate strain at the ligaments. Then, the ligaments were loaded under tension to failure at a rate of 1 mm/sec. The peak forces immediately before the failure of the ligaments were calculated by the machine and recorded (Figure 3).

### Histopathological examination

The specimens were kept in a 10% buffered formalin solution. After processing, 3  $\mu$ m sections

were obtained from samples embedded into paraffin. The sections were stained with routine hematoxylin-eosin and Masson's trichrome stain. The greatest concentration of collagen area was selected. Fibroblast counts were obtained in square millimeter. Then, the collagen index was quantitatively calculated by ImageJ (NIH, Bethesda, MD, USA) software program, as previously described (Figure 4).<sup>[10]</sup>

### Statistical analysis

Power analysis and sample size calculation were performed using the G\*Power version 3.1.9 software (Heinrich-Heine-Universität Düsseldorf, Düsseldorf, Germany). Considering the peak force value in the literature,<sup>[2]</sup> the minimum sample size required to detect the statistical significance of a difference of 10 newton (N) units (effect size=0.6316) between the groups was determined as 31 individuals under the conditions of 80% power and 5% type 1 error.

Statistical analysis was performed using the IBM SPSS for Windows version 22.0 software (IBM Corp., Armonk, NY, USA). Descriptive data were expressed in mean  $\pm$  standard deviation (SD), median (min-max) or number and frequency, where applicable. The distribution of continuous data was analyzed with the Shapiro-Wilk test. Group comparisons were done with an independent samples t-test for continuous variables. Categorical variables were analyzed with the Pearson chi-square test. A two-way analysis of variance (ANOVA), followed by the Fisher's least significant difference (LSD) post-hoc test, was used to compare the groups considering the sex. The Pearson correlation coefficient was calculated to examine the correlation

TABLE I							
Demographic characteristics, peak force values of LM, collagen index and fibroblast count of patients							
	Ruptured (n=36)			Intact (n=31)			p
	n	%	Mean $\pm$ SD	n	%	Mean $\pm$ SD	
Age (year)			31.7 $\pm$ 9.1			34.9 $\pm$ 5.8	0.099
Sex							<b>0.001</b>
Male	31	86.1		14	45.2		
Female	5	13.9		17	54.8		
BMI (kg/m <sup>2</sup> )			27.28 $\pm$ 5.20			28.63 $\pm$ 5.12	0.288
Peak force (N)			7.49 $\pm$ 3.80			5.64 $\pm$ 3.22	0.037
Collagen index			44.74 $\pm$ 3.27			43.42 $\pm$ 3.26	0.103
Fibroblast (/mm <sup>2</sup> )			143.67 $\pm$ 44.88			145.74 $\pm$ 25.71	0.821

LM: Ligamentum mucosum; SD: Standard deviation; BMI: Body mass index; N: Newton.

TABLE II				
Comparison of the peak force values of LM, collagen indices and fibroblast count of the groups considering the sex				
		Ruptured (n=36)	Intact (n=31)	<i>p</i>
		Mean±SD	Mean±SD	
Peak force (N)	Male	7.68±3.99	4.85±3.18	0.016
	Female	6.28±2.13	6.29±3.19	0.992
	<i>p</i>	0.411	0.263	
Collagen index	Male	44.70±3.16	44.80±2.94	0.923
	Female	44.99±4.29	42.28±3.14	<b>0.015</b>
	<i>p</i>	0.852	<b>0.033</b>	
Fibroblast (/mm <sup>2</sup> )	Male	143.55±47.51	149.00±24.48	0.656
	Female	144.40±26.40	143.06±27.12	0.945
	<i>p</i>	0.963	0.665	

LM: Ligamentum mucosum; SD: Standard deviation; N: Newton.

between numerical variables. A *p* value of <0.05 was considered statistically significant.

## RESULTS

The peak force (N) values of LM of the ACL ruptured group were higher than the ACL intact group (*p*=0.037). No significant difference was found between the groups in terms of collagen index (*p*=0.103) and fibroblast count (*p*=0.821). Although the age and BMI did not differ significantly (*p*=0.099, and *p*=0.288, respectively), sex distribution was significantly different between the groups (*p*=0.001); most of the ACL ruptured group consisted of males (Table I).

The mean operation time was 38.46±7.37 (range, 25 to 47) min for the ACL intact group and 81.45±16.10 (range, 68 to 92) min for the ACL ruptured group.

When the peak force values of LM of the groups were compared considering the sex, a significant

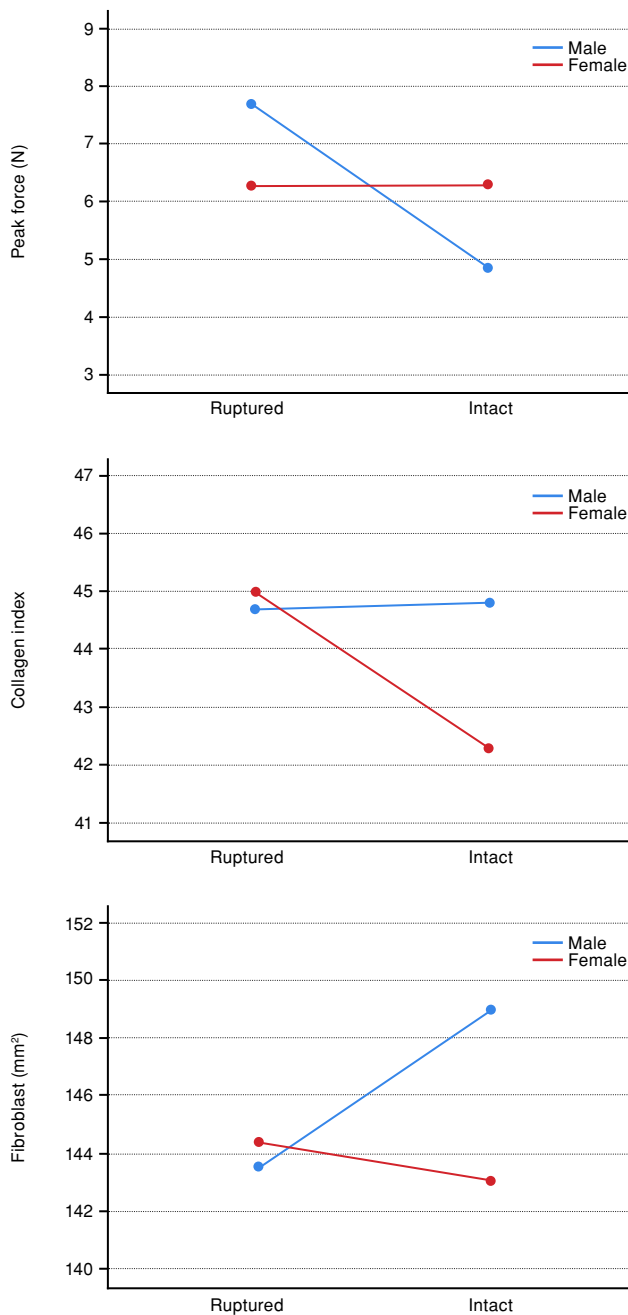
interaction was found. According to the post-hoc test results, while no significant difference was found between the ACL ruptured and ACL intact groups in females (*p*=0.992), males in the ACL ruptured group had a significantly higher peak force value than the males in the ACL intact group (*p*=0.016). On the other hand, although a lower peak force value was observed in males than the females in the ACL intact group, this difference was not statistically significant (*p*=0.263). Also, no statistically significant difference was observed between the male and female patients in the ACL ruptured group (*p*=0.411) (Table II, Figure 5a).

Comparison of the collagen indices of the groups according to the sex showed a significant interaction. According to the post-hoc test results, while no significant difference was found between the ACL ruptured and intact groups in males (*p*=0.923), females in the ACL ruptured group had a significantly higher collagen index than the females in the ACL intact

TABLE III				
Correlation of the peak force values (N) of LM with collagen index and fibroblast				
		Ruptured (n=36)	Intact (n=31)	Overall (n=67)
Collagen index	<i>r</i>	-0.429	-0.004	-0.185
	<i>p</i>	<b>0.009</b>	0.983	0.134
Fibroblast (/mm <sup>2</sup> )	<i>r</i>	0.037	0.103	0.046
	<i>p</i>	0.830	0.583	0.709

LM: Ligamentum mucosum; N: Newton.

group ( $p=0.015$ ). On the other hand, a statistically significantly lower collagen index was observed in females than the males in the ACL intact group ( $p=0.033$ ). No significant difference was observed between the male and female patients in the ACL ruptured group in terms of collagen index ( $p=0.852$ ) (Table II, Figure 5b).



**FIGURE 5.** (a) Comparison of the peak force values of LM, (b) collagen indices, and (c) fibroblast count of the groups considering the gender. LM: Ligamentum mucosum; N: Newton.

When the fibroblast count of the groups were compared considering the sex, no significant interaction was found. Namely, no significant difference was observed in the general comparison, when the groups were compared considering the sex separately (Table II, Figure 5c).

No significant correlation was found between the peak force values (N) of LM and either collagen index or fibroblast in the ACL intact group. A statistically significant, but weak negative correlation was observed between the peak force values (N) of LM and collagen index in the ACL ruptured group ( $r=-0.429$ ,  $p=0.009$ ) (Table III).

## DISCUSSION

Although there is an increased interest on the structure and function of the LM recently, limited data is available in the English literature. The main finding of this current study is the demonstration of increased peak force value of the LM in the patients with an ACL rupture; to the best of our knowledge, no previous study has investigated the biomechanical and histopathological changes of the LM in patients with ACL rupture.<sup>[11]</sup>

In a study by Brooker et al.,<sup>[12]</sup> the macroscopic anatomy of the IFP was investigated clinically and they found LM in 79% of the patients. Also, in some cadaveric studies the presence of the LM was found to be more than 85% of the examined specimens.<sup>[1,6]</sup> These studies mainly addressed older cadaveric specimens. On the other hand, in a recent study by Gonera et al.,<sup>[13]</sup> the presence of the LM was found to be 100% in the examined knees of the aborted and not yet born human fetuses. This may be explained by the theory that the knee ligaments including the LM injured during the degenerative processes in the elderly population.<sup>[14]</sup> Unfortunately, we were unable to identify the incidence of the LM presence, as we only included the patients having an intact LM structure in the study. The presence and importance of the LM was overlooked in most of the arthroscopic surgeries, and this is mostly due to the lack of enough knowledge about its structure and function.

The histological structure of the LM was studied by Norris et al.,<sup>[2]</sup> and they found that it mainly composed of a dense regular connective tissue, resembling the other ligamentous structures of the knee such as cruciate ligaments. The authors also reported the presence of neural tissue in the LM which suggests that it may play a role in the pathogenesis of anterior knee pain.

The vascular structure of the LM was also studied and a rich arterial blood supply to the IFP and LM was identified.<sup>[8]</sup> In a study by Arnoczky et al.,<sup>[7]</sup> the revascularization potential of the IFP was shown after the ACL replacement. The rich vascular network and presence of tiny neural structures of the LM was shown in a recent study and the authors showed that the LM might be used during the ACL reconstruction surgery to improve revascularization and reinnervation processes.<sup>[9]</sup> Although we were unable to find any significant difference between the groups in terms of the collagen indices and fibroblast counts in the histopathological examination, the structure of the specimens of LM was resembling to the true ligaments of the knee.

Furthermore, ACL is the main static stabilizer of the knee against anterior translation of the tibia. It is responsible for about the 86% of the total force resisting anterior draw of the knee. This important and strong ligament's maximum tensile strength is approximately 1,725 N.<sup>[15]</sup> The LM also provides some degree of stabilization against anterior subluxation of the IFP, patella, and knee joint.<sup>[9]</sup> In a study by Kambhampati and Chittoor,<sup>[16]</sup> the resection of the LM may alter the kinematics of the knee and patella. There is only one study in the literature reporting the tensile strength of the LM and this anatomical study investigated the five specimens taken from cadavers at a mean age of 77 years and the authors reported a mean peak force value of the LM as  $31.9 \pm 19.0$  N.<sup>[2]</sup> In this study, the peak force values of the LM varied between 9.1 N to 53.1 N. The results of our clinical study showed significant changes in the strength of the LM in ACL ruptured patients. According to our results, the mean peak force values of the LM specimens were higher in the ACL ruptured group ( $7.49 \pm 3.80$ ) than ACL intact patients ( $5.64 \pm 3.22$ ), indicating a statistically significant difference ( $p=0.037$ ). In line with these results, LM seems to be a potential contributor to the knee stabilization against anterior translation of the tibia. Considering the peak force values of the LM according to sex, a statistically significant difference was only seen between groups in male sex. The values did not significantly differ in female patients; however, this can be attributed to the non-homogeneous distribution of the patients according to sex in our study.

Although the contribution of the LM to the anterior knee pain has been investigated in previous studies, most of them are based on cadaveric specimens or small sample sized clinical trials.<sup>[2,17,18]</sup> Anatomical changes in the LM and IFP were studied

in the MRI of the ACL ruptured patients in retrospective studies.<sup>[3,19]</sup> These studies showed substantial changes in the LM and IFP in patients with ACL rupture as edema and impingement of the fat pad and hypertrophy and inflammation of the LM. In a recent cadaveric study by Martin et al.,<sup>[20]</sup> the association between knee osteoarthritis and presence of the LM was investigated. They evaluated 33 cadaveric knees with LM was present in 22 of them. The average age of the patients was 85.5 years in the aforementioned study and the authors found a significantly higher degree of osteoarthritis level in the LM absent knees, particularly in the trochlear groove region. They also reported that the type of the present LM might affect the extent of the knee osteoarthritis. On the contrary, our current study was designed as a prospective study and included only younger patients, this is why we encounter no sign of osteoarthritis.

Nonetheless, this study has some limitations. First, while the age and BMI of the patients were not significantly differed in between the groups, the overall distribution of the patients were not homogeneous in terms of sex. This prevents us from assessing the peak force values of the LM differences between the male and female patients. Second, classification of the LM structure could be done during the arthroscopy and the relation between the different types of LM could be evaluated. Third, a detailed immunohistochemical analysis of the specimens such as anti-NFP and anti-CD31 immunostaining could yield some valuable information about the nerves and vessels.

In conclusion, our study results showed that the peak force values of the LM were significantly increased in patients with an ACL rupture. This suggests that the LM is exposed to more force to maintain knee stability in patients with ACL rupture, thus its strength increases. Although the results of this study are promising, further well-designed, randomized-controlled studies using more advanced immunohistochemical analysis methods are needed to confirm these findings.

**Ethics Committee Approval:** The study protocol was approved by the Düzce University Faculty of Medicine Ethics Committee (date: 23.05.202, no: 2022/95). The study was conducted in accordance with the principles of the Declaration of Helsinki.

**Patient Consent for Publication:** A written informed consent was obtained from each patient.

**Data Sharing Statement:** The data that support the findings of this study are available from the corresponding author upon reasonable request.

**Author Contributions:** Idea/concept, literature review, critical review, references and fundings: Y.T.; Design, writing the article, materials: Y.T., M.A.; Control/supervision: Z.O.K., M.A.S., M.G.; Data collection: Y.T., M.A.; Processing: M.A.S., M.G.; Analysis and/or interpretation: Y.T., M.A., Z.O.K.

**Conflict of Interest:** The authors declared no conflicts of interest with respect to the authorship and/or publication of this article.

**Funding:** The authors received no financial support for the research and/or authorship of this article.

## REFERENCES

- Kim SJ, Min BH, Kim HK. Arthroscopic anatomy of the infrapatellar plica. *Arthroscopy* 1996;12:561-4. doi: 10.1016/s0749-8063(96)90195-4.
- Norris M, Corbo G, Banga K, Johnson M, Sandig M, Smallman T, et al. The biomechanical and morphological characteristics of the ligamentum mucosum and its potential role in anterior knee pain. *Knee* 2018;25:1134-41. doi: 10.1016/j.knee.2018.08.017.
- Abreu MR, Chung CB, Trudell D, Resnick D. Hoffa's fat pad injuries and their relationship with anterior cruciate ligament tears: New observations based on MR imaging in patients and MR imaging and anatomic correlation in cadavers. *Skeletal Radiol* 2008;37:301-6. doi: 10.1007/s00256-007-0427-y.
- Frank CB. Ligament structure, physiology and function. *J Musculoskelet Neuronal Interact* 2004;4:199-201.
- Bohnsack M, Wilharm A, Hurschler C, Rühmann O, Stukenborg-Colsman C, Wirth CJ. Biomechanical and kinematic influences of a total infrapatellar fat pad resection on the knee. *Am J Sports Med* 2004;32:1873-80. doi: 10.1177/0363546504263946.
- Vahlensieck M, Linneborn G, Schild H, Schmidt HM. Hoffa's recess: Incidence, morphology and differential diagnosis of the globular-shaped cleft in the infrapatellar fat pad of the knee on MRI and cadaver dissections. *Eur Radiol* 2002;12:90-3. doi: 10.1007/s003300100982.
- Arnoczky SP, Tarvin GB, Marshall JL. Anterior cruciate ligament replacement using patellar tendon. An evaluation of graft revascularization in the dog. *J Bone Joint Surg [Am]* 1982;64:217-24.
- Kohn D, Deiler S, Rudert M. Arterial blood supply of the infrapatellar fat pad. Anatomy and clinical consequences. *Arch Orthop Trauma Surg* 1995;114:72-5. doi: 10.1007/BF00422828.
- Gonera B, Wysocki G, Kurtys K, Brzeziński P, Borowski A, Olewnik Ł. Immunohistochemical analysis of the ligamentum mucosum is the key to understand its clinical usefulness. *Ann Anat* 2023;249:152106. doi: 10.1016/j.aanat.2023.152106.
- Çalışkan E, Gamsızkan M, Açıkgöz G, Durmuş M, Toklu S, Doğrul A, et al. Intralesional treatments for hypertrophic scars: Comparison among corticosteroid, 5-fluorouracil and botulinum toxin in rabbit ear hypertrophic scar model. *Eur Rev Med Pharmacol Sci* 2016;20:1603-8.
- Atik OŞ. Writing for Joint Diseases and Related Surgery (JDRS): There is something new and interesting in this article! *Jt Dis Relat Surg* 2023;34:533. doi: 10.52312/jdrs.2023.57916.
- Brooker B, Morris H, Brukner P, Mazen F, Bunn J. The macroscopic arthroscopic anatomy of the infrapatellar fat pad. *Arthroscopy* 2009;25:839-45. doi: 10.1016/j.arthro.2009.01.020.
- Gonera B, Borowski A, Zielinska N, Palac W, Paulsen F, Olewnik Ł. Embryological approach to the morphology of the ligamentum mucosum of the human knee joint. *Ann Anat* 2022;244:151983. doi: 10.1016/j.aanat.2022.151983.
- Ozcan M, Copuroğlu C, Ciftdemir M, Turan FN, Calpur OU. Does an abnormal infrapatellar plica increase the risk of chondral damage in the knee. *Knee Surg Sports Traumatol Arthrosc* 2011;19:218-21. doi: 10.1007/s00167-010-1273-3.
- Markatos K, Kaseta MK, Lallios SN, Korres DS, Efstathopoulos N. The anatomy of the ACL and its importance in ACL reconstruction. *Eur J Orthop Surg Traumatol* 2013;23:747-52. doi: 10.1007/s00590-012-1079-8.
- Kambhampati SB, Chittoor SP. Retraction of infrapatellar fat pad during arthroscopy of the knee. *J Arthrosc Surg Sport Med* 2021;2:81-3.
- Smallman TV, Portner OT, Race A, Shekitka K, Mann K. Arthroscopic untethering of the fat pad of the knee: Release or resection of the infrapatellar plica (ligamentum mucosum) and related structures for anterior knee pain. *Arthrosc Tech* 2018;7:e575-88. doi: 10.1016/j.eats.2018.02.002.
- Lee PYF, Nixion A, Chandratreya A, Murray JM. Synovial plica syndrome of the knee: A commonly overlooked cause of anterior knee pain. *Surg J (N Y)* 2017;3:e9-16. doi: 10.1055/s-0037-1598047.
- Goto K, Taketomi S, Shimizu N. Central patellar portal placement frequently provokes anterior knee compartment radiological abnormalities in anterior cruciate ligament reconstruction. *Knee Surg Sports Traumatol Arthrosc* 2020;28:2255-60. doi: 10.1007/s00167-019-05817-4.
- Martin A, Liu K, Alimohammadi M. The ligamentum mucosum's potential as a preventative structure in the development of knee osteoarthritis. *J Exp Orthop* 2023;10:109. doi: 10.1186/s40634-023-00681-1.