



Slipped capital femoral epiphysis after tumor prosthesis implantation in a patient receiving chemotherapy

Recep Öztürk, MD¹, Markus Nottrott, MD¹, Wiebke Guder, MD¹, Julian Röder, MD¹,
Christina Polan, MD², Lars Erik Podleska, MD¹, Arne Streitbürger, MD¹,
Jendrik Harges, MD¹, Nina Myline Engel, MD¹

¹Department of Orthopedic Oncology, University Hospital Essen, Essen, Germany

²Department of Trauma Surgery, University Hospital Essen, Essen, Germany

Slipped capital femoral epiphysis (SCFE) is the disruption of the relationship between the proximal femoral epiphysis and the femoral neck. A mechanical overload to the proximal femoral physis results in anterior translation and external rotation of the proximal femoral metaphysis relative to the epiphysis.^[1] The proximal femoral physis is an area of rapid cellular proliferation and is susceptible to imbalance. This sensitivity may increase in various conditions such as endocrine and metabolic disorders. Studies have been reported that chemotherapy (CT) can also affect the physis with a systemic effect.^[2]

Slipped capital femoral epiphysis develops gradually over several weeks or months, usually without any injury. However, it sometimes occurs suddenly after a minor fall or trauma.^[3]

Received: October 18, 2023

Accepted: November 10, 2023

Published online: February 13, 2024

Correspondence: Recep Öztürk, MD. Universitätsklinikum Essen, Die Klinik für Tumororthopädie und Sarkomchirurgie Hufelandstraße 55, 45147 Essen, Germany.

E-mail: Recep.Oeztuerk@ext.uk-essen.de

Doi: 10.52312/jdrs.2024.1493

Citation: Öztürk R, Nottrott M, Guder W, Röder J, Polan C, Podleska LE, et al. Slipped capital femoral epiphysis after tumor prosthesis implantation in a patient receiving chemotherapy. *Jt Dis Relat Surg* 2024;35(2):443-447. doi: 10.52312/jdrs.2024.1493.

©2024 All right reserved by the Turkish Joint Diseases Foundation

This is an open access article under the terms of the Creative Commons Attribution-NonCommercial License, which permits use, distribution and reproduction in any medium, provided the original work is properly cited and is not used for commercial purposes (<http://creativecommons.org/licenses/by-nc/4.0/>).

ABSTRACT

While the usual etiology of slipped capital femoral epiphysis (SCFE) is idiopathic, there are many other factors that increase the predisposition to slippage. Chemotherapy can be one of them. In this article, we report a rare case of acute SCFE after tumor prosthesis implantation in a patient who received chemotherapy. A 10-year-old girl with osteosarcoma of the right distal femur underwent (neo-) adjuvant chemotherapy, wide tumor resection, and reconstruction using a growing tumor prosthesis and a short non-cemented femoral stem. Half a year after implantation, she developed aseptic loosening. Revision surgery was performed using a hydroxyapatite (HA)-coated cementless femoral stem. Postoperative plain radiographs revealed SCFE that was treated by closed reduction and screw fixation. The patient recovered without complications, and unaffected hip showed no radiographic signs of slippage on follow-up. The forces of implanting a tumor prosthesis, particularly with a non-cemented stem, can increase the risk of an acute SCFE. The controversy over prophylactic pinning of the uninvolved hip in chemotherapy-associated SCFE is unresolved. Pinning can be considered only in the presence of abnormal prodromal radiological findings.

Keywords: Chemotherapy, hip disorders, slippage, slipped capital femoral epiphysis, tumor prosthesis.

In this article, we present a rare case of acute SCFE after tumor prosthesis implantation in a patient who received CT.

CASE REPORT

A 10-year-old girl with osteosarcoma of the right distal femur underwent (neo-) adjuvant CT, wide tumor resection, and reconstruction using a growing tumor prosthesis and a short, non-cemented femoral stem. Figure 1a, b show preoperative anteroposterior and lateral radiographs, respectively. Figure 2a, b show postoperative anteroposterior and lateral radiographs, respectively.

The patient had pain in the post-surgical follow-up. Early signs of loosening were present in the radiographs. Figures 3a, b are the anteroposterior and lateral radiographs showing the signs of loosening, respectively. Adjuvant CT continued with partial weight bearing. Half a year after implantation, she developed aseptic loosening. Figures 4a, b are the anteroposterior and lateral radiographs showing aseptic loosening, respectively.

Revision surgery was performed using an HA-coated cementless femoral stem. Postoperative plain radiographs revealed an acute SCFE. Figures 5a, b are the postoperative anteroposterior and lateral radiographs showing acute SCFE, respectively. Acute SCFE was treated by closed reduction and screw fixation. Figures 6a, b show postoperative anteroposterior and lateral radiographs after fixation, respectively.

Postoperatively, the patient recovered without complications. After six weeks of partial weight bearing, she started increasing load incrementally.

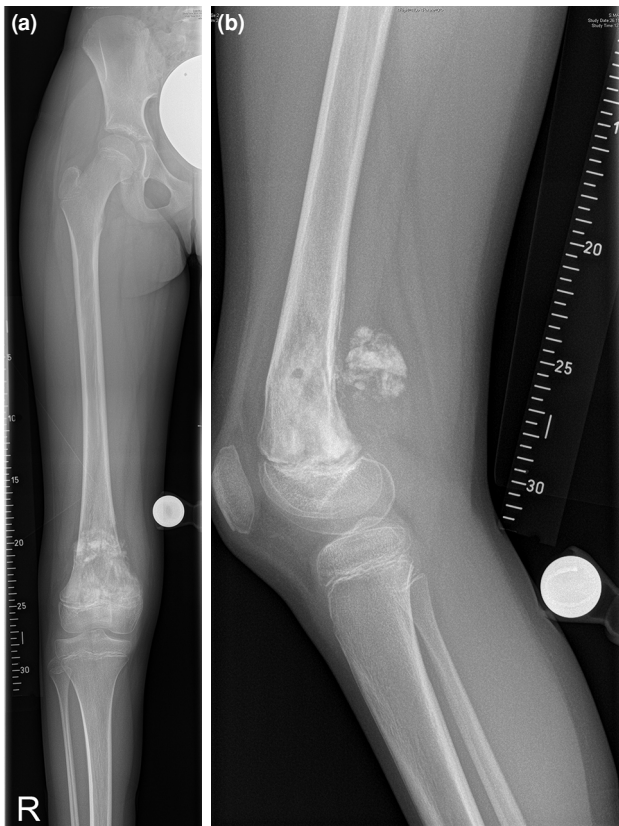

FIGURE 1. Ten-year-old girl with osteosarcoma of the right distal femur (a) preoperative anteroposterior radiograph (b) preoperative lateral radiograph.

The use of walking aids was terminated and she returned to school.

A year after the operation, she was pain-free, had full weight bearing, and the range of motion in the right hip was not limited. Avascular necrosis was not observed. Figures 7a, b show the anteroposterior and lateral radiographs in the first postoperative year, respectively. The left, unaffected hip showed no radiographic signs of slippage.

DISCUSSION

Slipped capital femoral epiphysis is one of the most common developmental conditions of the hip joint.

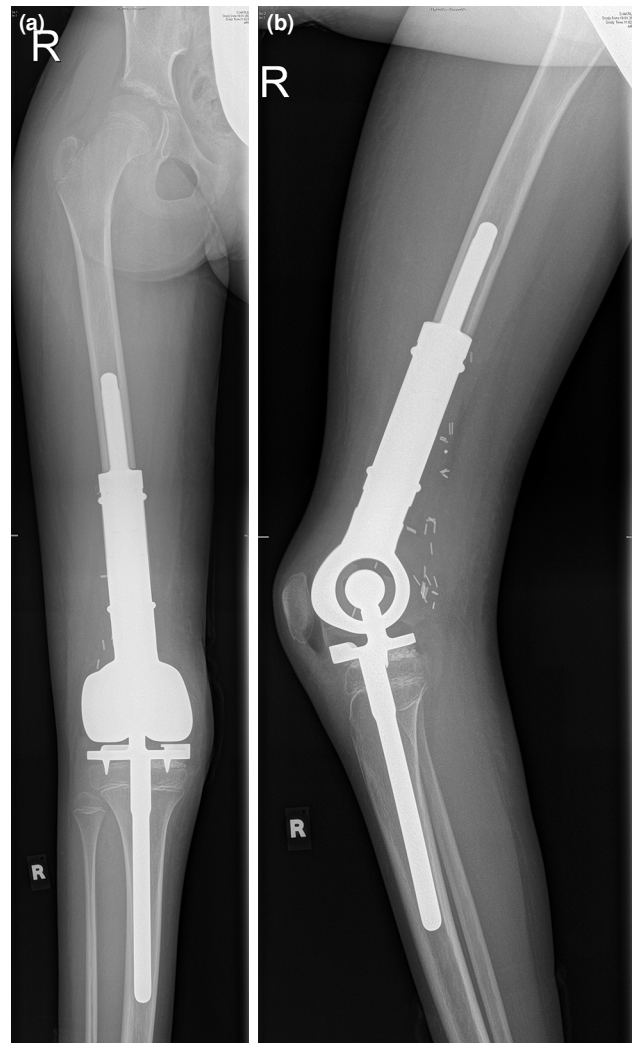


FIGURE 2. Wide tumor resection and reconstruction surgery performed using a tumor prosthesis with a custom-made, short, non-cemented femoral stem. (a) Postoperative anteroposterior radiograph (b) postoperative lateral radiograph.

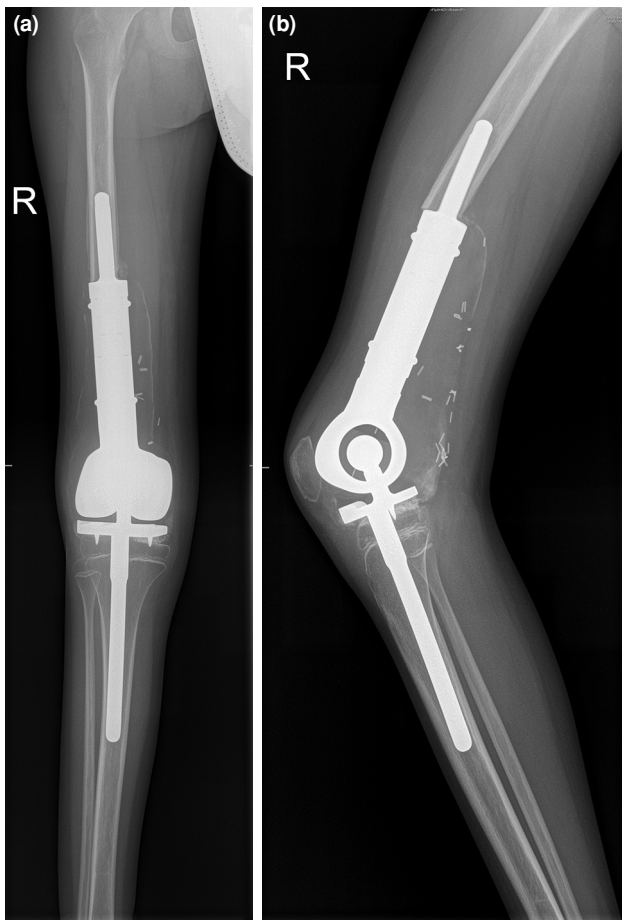


FIGURE 3. Direct radiographs show early signs of loosening. (a) Anteroposterior radiograph (b) lateral radiograph.

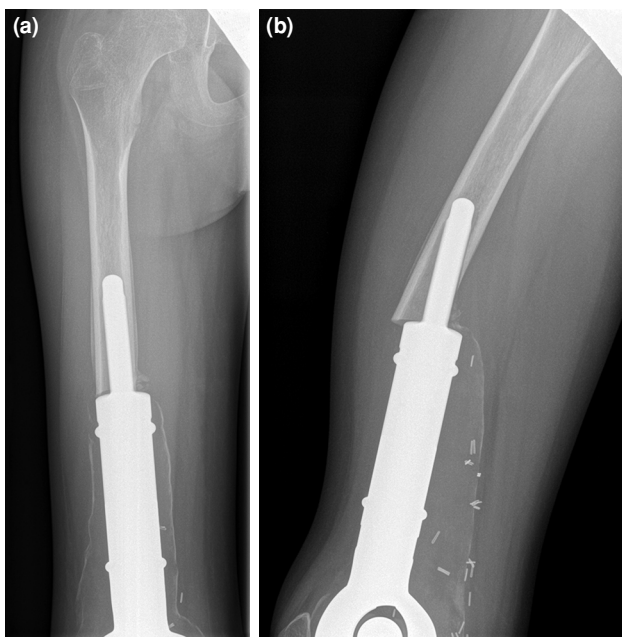


FIGURE 4. Aseptic loosening half a year after implantation. (a) Anteroposterior radiograph (b) lateral radiograph.

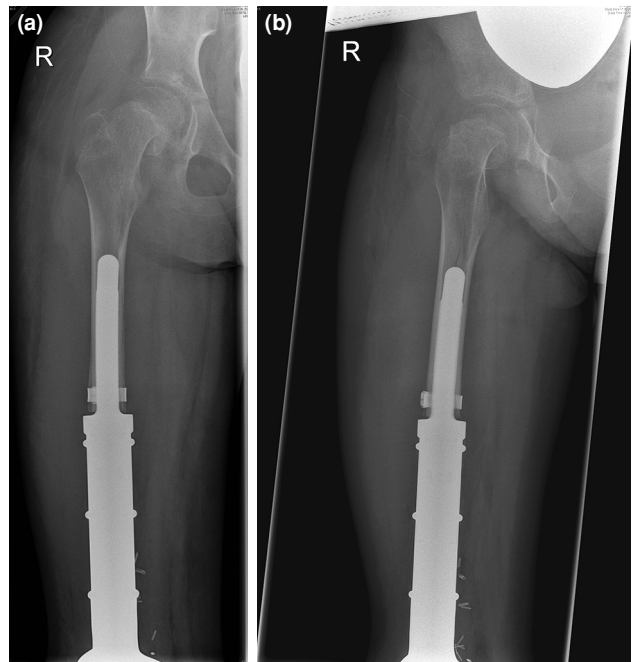


FIGURE 5. Revision surgery was performed using an HA-coated cementless femoral stem. Postoperative plain radiographs reveal an acute SCFE. (a) Anteroposterior radiograph (b) lateral radiograph. SCFE: Slipped capital femoral epiphysis.

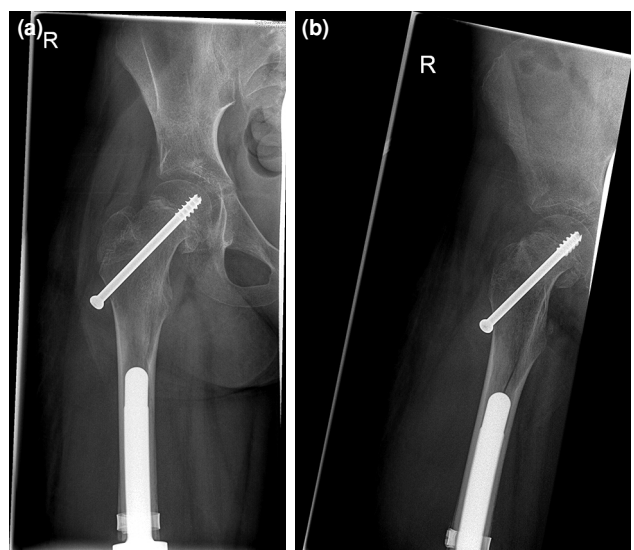


FIGURE 6. Acute SCFE that was treated by closed reduction and screw fixation. (a) Anteroposterior radiograph (b) lateral radiograph. SCFE: Slipped capital femoral epiphysis.

However, among the three different SCFEs (acute, chronic, and acute on chronic), acute traumatic slip is the rarest type.^[4] To the best of our knowledge, this study is the first case of acute SCFE after a femur-related surgery involving maneuvers that

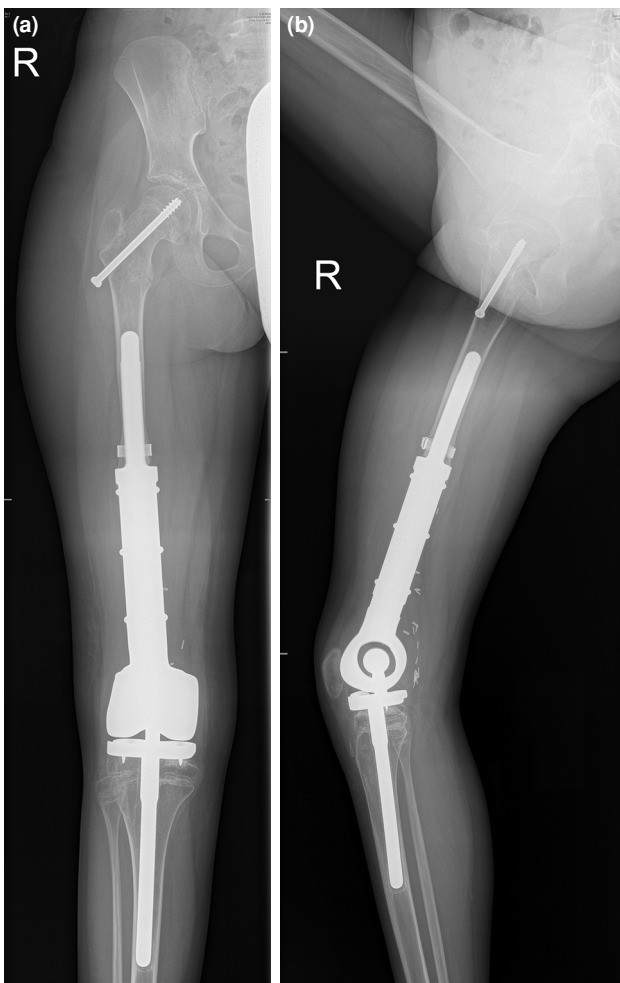


FIGURE 7. Follow-up images in the first year (a) anteroposterior radiograph (b) lateral radiograph.

place stress on the physis.^[5] As the pathogenesis of SCFE is characterized by the disproportion between the load-bearing capacity of the epiphysis and the acting forces on the proximal femur, the most likely cause for acute SCFE, in this case, was the force necessary to achieve press-fit femoral stem implantation.

Data on SCFE after CT are limited in the literature. In 1979, Ryan and Walters^[6] reported SCFE in two patients who received CT, and concurrent radiotherapy (RT), and they suggested that growth plate exposed to CT and radiation may have developed SCFE, either directly related to the damage or indirectly due to the inability to sustain the normal stress encountered. Liu et al.,^[7] in their literature review, reported 34 patients who received CT and RT to the pelvic region. They concluded that they could not understand which of the treatment

methods caused, or whether both of them caused it. To date, there seems to be no literature on a direct relationship between CT and SCFE. However, in the series of 53 patients published by Chung et al.,^[2] there were at least 10 SCFE patients who did not receive pelvic radiotherapy and received only CT. All these data suggest that CT may be an etiological agent due to the systemic effects of chemotherapeutic agents on the physis. The absence of RT history in the current case and the fact that the patient does not have other etiologies suggest that CT may also contribute to the development of SCFE.

A long period of partial weight bearing during adjuvant CT and aseptic stem loosening probably added to the reduction of the femoral epiphysis' load-bearing capacity in this case. A history of radiation and/or CT is known to increase the risk of epiphysiolysis of the affected epiphysis and/or other sites, respectively.^[7] The forces of implanting a tumor prosthesis, particularly with a non-cemented stem, act on the weakened bone and increase the risk of an acute SCFE even more. Therefore, to avoid missing an acute SCFE postoperatively, the adjacent joint should be visible on postoperative plain radiographs. Additionally, special attention should be given to hip pain, appearing over time, even if it is far from the implant site.

Another controversial issue in SCFE is whether the unaffected side should be pinned prophylactically. Ryan and Walters^[6] performed pin fixation in two cases with SCFE after CT and RT. In one of the cases, SCFE was seen on the other side at six months and was operated similarly. On the other side, Liu et al.^[7] reported two cases who received CT and RT, and both cases did not develop SCFE in the contralateral hip at four-year follow-up. In patients who received both CT and RT, the effects of CT and RT on the hip may differ, and we do not know which was responsible for how much. In the current study, the contralateral side was not pinned and no SCFE development was observed in the contralateral hip at 12-month follow-up. In patients receiving CT only and in the presence of SCFE after surgery, pinning can only be considered in the presence of abnormal prodromal radiological findings.

In conclusion, SCFE can be seen after adjacent joint surgeries in patients receiving CT. Therefore, plain radiographs can be seen to avoid missing an acute SCFE postoperatively. In addition, special attention should be paid to hip pain that occurs over time, even away from the implant site.

Patient Consent for Publication: A written informed consent was obtained from the parent of the patient.

Data Sharing Statement: The data that support the findings of this study are available from the corresponding author upon reasonable request.

Author Contributions: Idea/concept: A.S., J.H., M.N., N.M.E.; Control/supervision: L.E.P., W.G.; Data collection and/or processing: C.P., J.R.; Literature review, writing the article: R.Ö., M.N.; Critical review: A.S., J.H.

Conflict of Interest: The authors declared no conflicts of interest with respect to the authorship and/or publication of this article.

Funding: The authors received no financial support for the research and/or authorship of this article.

REFERENCES

1. Georgiadis AG, Zaltz I. Slipped capital femoral epiphysis: How to evaluate with a review and update of treatment. *Pediatr Clin North Am* 2014;61:1119-35. doi: 10.1016/j.pcl.2014.08.001.
2. Chung CH, Ko KR, Kim JH, Shim JS. Clinical and radiographic characteristics of atypical slipped capital femoral epiphysis. *J Pediatr Orthop* 2019;39:e742-9. doi: 10.1097/BPO.0000000000001339.
3. Millis MB. SCFE: Clinical aspects, diagnosis, and classification. *J Child Orthop* 2017;11:93-8. doi: 10.1302/1863-2548-11-170025.
4. van Gorkom M, Noordman BJ, Westerhuis RJ, van der Elst M, van Ginhoven TM. Slipped capital femoral epiphysis in children. *Ned Tijdschr Geneeskd* 2015;159:A8238.
5. Atik OŞ. Writing for Joint Diseases and Related Surgery (JDRS): There is something new and interesting in this article! *Jt Dis Relat Surg* 2023;34:533. doi: 10.52312/jdrs.2023.57916.
6. Ryan BR, Walters TR. Slipped capital femoral epiphysis following radiotherapy and chemotherapy. *Med Pediatr Oncol* 1979;6:279-83. doi: 10.1002/mpo.2950060402.
7. Liu SC, Tsai CC, Huang CH. Atypical slipped capital femoral epiphysis after radiotherapy and chemotherapy. *Clin Orthop Relat Res* 2004;426:212-8. doi: 10.1097/01.blo.0000136655.51838.84.