



Conservative treatment of congenital radial head subluxation and non-traumatic elbow locking: A case report

Shao-Guang Li, MD* , Shuai-Jie LV, MD* , Ding-Yi Zhang, MD , Bang-Jian He, MD 

Department of Orthopaedics, The First Affiliated Hospital of Zhejiang Chinese Medical University, Hangzhou, Zhejiang, China

Congenital radial head subluxation is relatively rare and typically causes abnormal joint movements or pain in children and adolescents.^[1] Early surgery results in favorable outcomes.^[2] Treatment options include arthroscopy, radial head resection, and ulnar osteotomy.^[3-5] Mildly symptomatic patients can be managed with careful observation or conservative treatment.^[6]

In this article, we present an adult case of congenital radial head subluxation and non-traumatic elbow locking which was successfully treated with conservative treatment.

CASE REPORT

A 30-year-old man presented to our orthopedic clinic with sudden onset of right elbow locking. The patient experienced right elbow discomfort after playing basketball, although he did not seek medical

ABSTRACT

Congenital radial head subluxation is relatively rare and may be overlooked due to mild symptoms. The diagnosis mainly relies on imaging and history. Observation is an option for those with insignificant symptoms, while surgical intervention, such as ulnar osteotomy or arthroscopy, is often required when dysfunction exists. A 30-year-old man was admitted with congenital radial head dislocation, which was treated with manipulative repositioning. During follow-up, the patient regained the original mobility of the elbow joint and had no recurrence of dislocation. In conclusion, in adults with congenital dislocation of the radial head, we recommend conservative treatment as a first step.

Keywords: Congenital radial head dislocation, deformed radial head, manual reduction.

attention. Subsequently, he developed sudden-onset severe pain and an inability to extend the right elbow joint after placing his flexed right elbow on a table, while his left hand was extended to hold a glass of water. Physical examination revealed no swelling of the right elbow joint, elbow flexion to 120°, and pain during attempts to rotate or straighten the elbow. The patient denied any history of right elbow trauma. However, he experienced mild limitation of flexion since childhood, substantial valgus, and a bulge in front of the right elbow socket. In his medical history, there was no known genetic diseases. X-ray revealed isolated radial head dislocation and abnormal radial head shape including loss of its concave appearance (Figure 1). Considering the patient's symptoms and abnormal radial head shape, computed tomography (CT) with three-dimensional reconstruction was performed which revealed anterior dislocation of the radial head to the intercondylar fossa and a dome-shaped radial head, similar to a sharpened pencil (Figure 2). The patient was diagnosed with isolated anterior dislocation of the radial head and recommended to

Received: January 28, 2024

Accepted: January 28, 2024

Published online: March 21, 2024

Correspondence: Bang-Jian He, MD. Department of Orthopaedics, The First Affiliated Hospital of Zhejiang Chinese Medical University, Hangzhou 310006, Zhejiang China.

E-mail: hebangjian@163.com

Doi: 10.52312/jdrs.2024.1608

* The two authors contributed equally to this study.

Citation: Li SG, LV SJ, Zhang DY, He BJ. Conservative treatment of congenital radial head subluxation and non-traumatic elbow locking: A case report. Jt Dis Relat Surg 2024;35(2):410-416. doi: 10.52312/jdrs.2024.1608.

©2024 All right reserved by the Turkish Joint Diseases Foundation

This is an open access article under the terms of the Creative Commons Attribution-NonCommercial License, which permits use, distribution and reproduction in any medium, provided the original work is properly cited and is not used for commercial purposes (<http://creativecommons.org/licenses/by-nc/4.0/>).

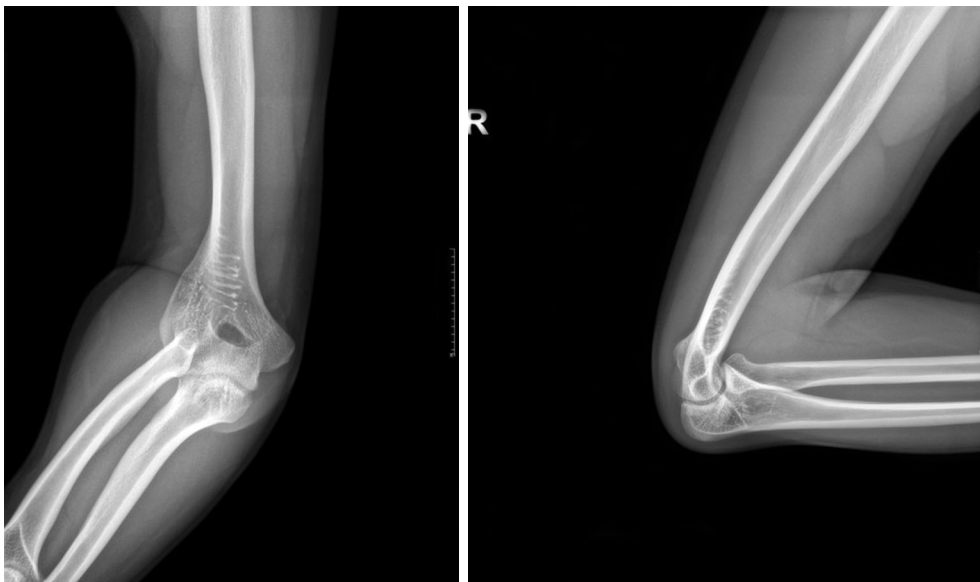

FIGURE 1. Anteroposterior and lateral X-rays showing anterior dislocation of the radial tuberosity and abnormal radial head morphology.

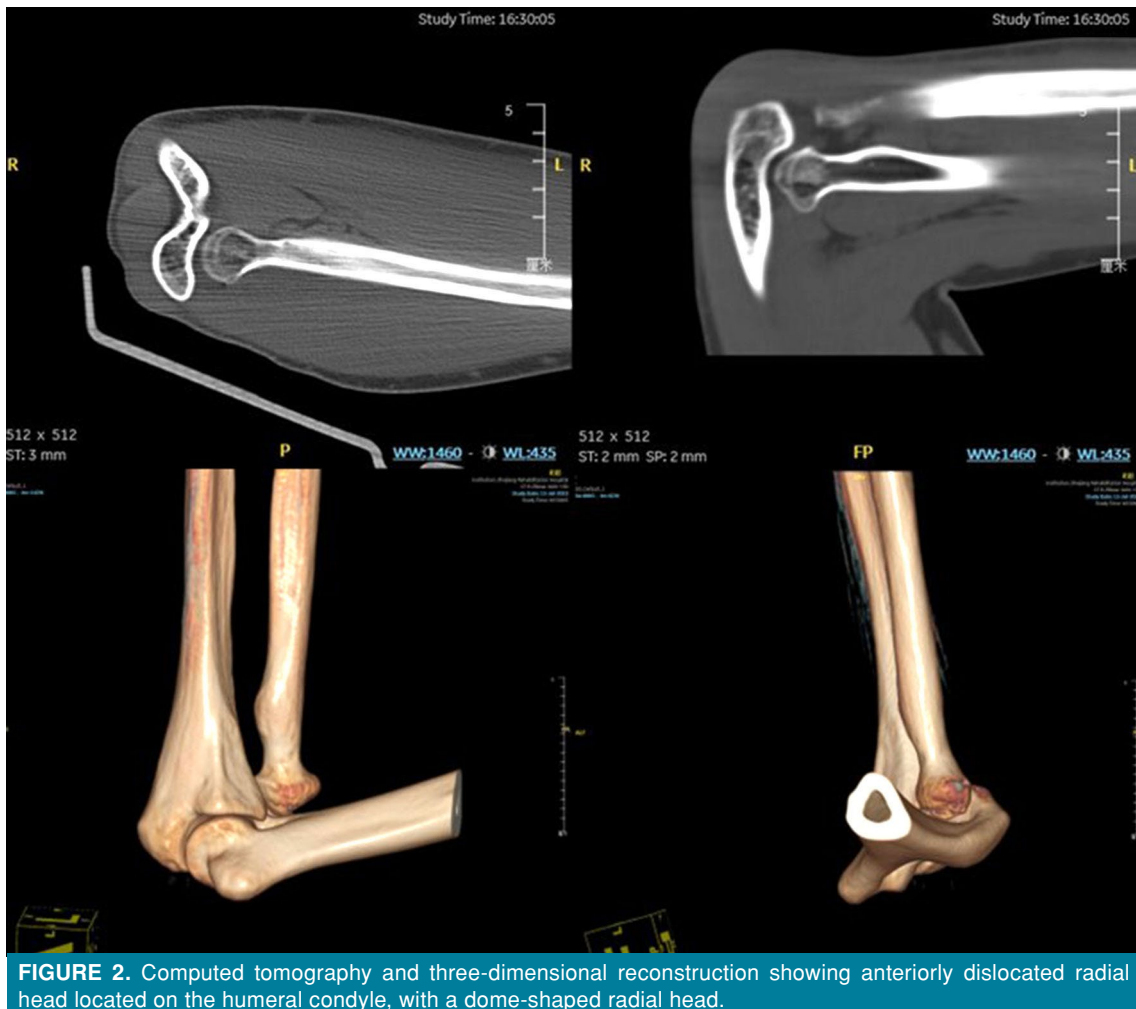


FIGURE 2. Computed tomography and three-dimensional reconstruction showing anteriorly dislocated radial head located on the humeral condyle, with a dome-shaped radial head.

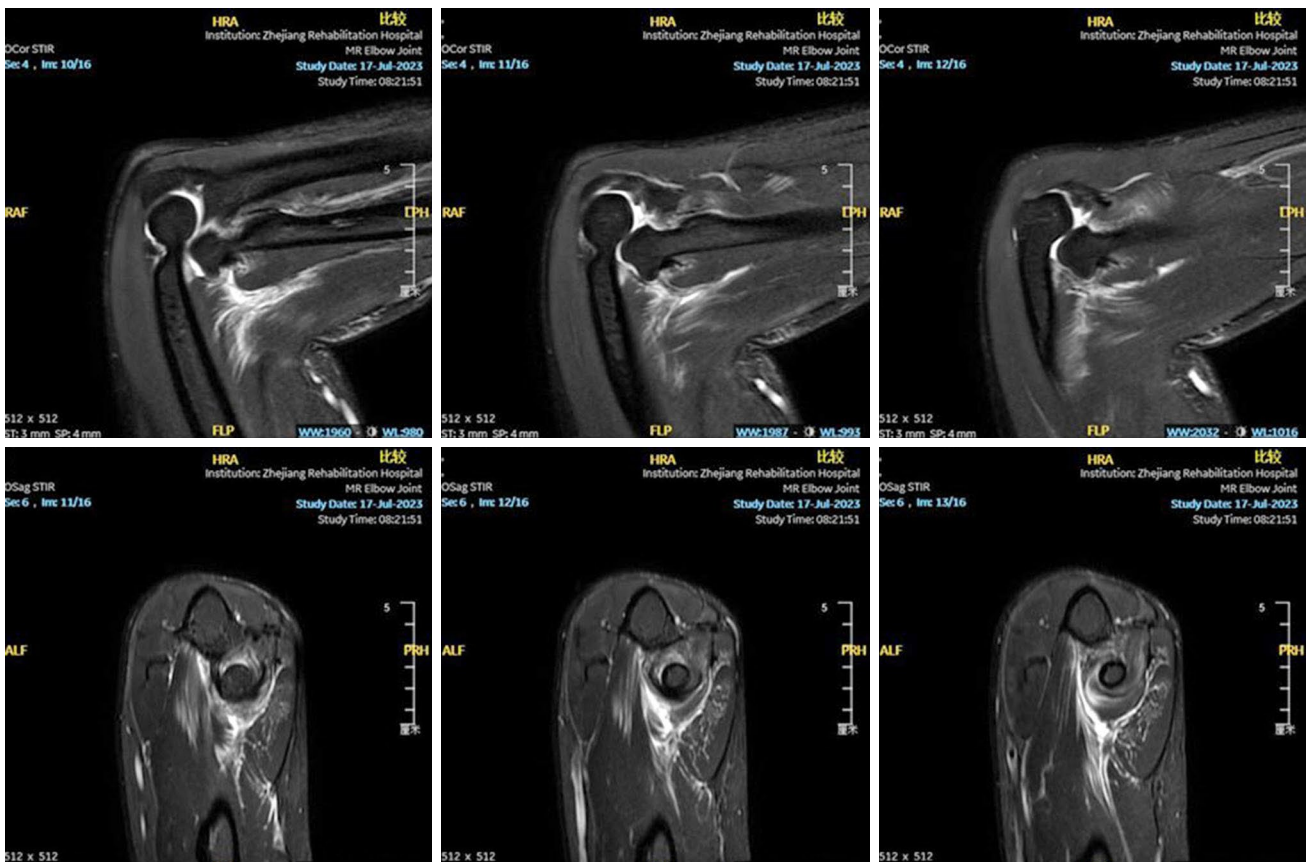


FIGURE 3. Magnetic resonance imaging showing soft tissue edema anterior to the elbow joint and partial tearing of the annular ligament.

undergo repositioning. Repositioning was attempted under brachial plexus anesthesia, which failed to relax the elbow joint. Subsequent attempts to achieve longitudinal traction and pull back the radial tuberosity were unsuccessful.

The following day, magnetic resonance imaging (MRI) revealed anterior soft tissue edema, an elongated annular ligament surrounding the radial head, a minor tear without discontinuity, and forward shift of the radial tuberosity after it was broken free from the annular ligament (Figure 3). The patient's history and imaging findings suggested that the radial head morphology did not match the morphology of the humeral tuberosity. He reported the presence of a right elbow abnormality since birth and denied any injury during birth or growth. In the light of this information, the patient was diagnosed with isolated anterior dislocation of the radial head and congenital subluxation of the radial tuberosity.

Despite receiving information about its risks, the patient selected conservative treatment. Under

anesthesia, the patient's elbow was flexed between 110° and 130° with 60° of pronation and 20° of supination. Therefore, repositioning was repeated in accordance with the concept of "to separate first" in Chinese orthopedics. First, the forearm was rotated forward with the elbow flexed to move the radial head away from the intercondylar fossa. The assistant immobilized the upper arm while the operator pressed on the radial head with their right thumb, pushing it distally. Slight longitudinal traction was applied during forearm supination to straighten the elbow joint. Unexpectedly, the procedure was successful during the initial attempt (Figure 4).

A long arm cast was used to immobilize the elbow joint in an extended position for six weeks. Subsequent evaluation revealed that the radial head was removed from the intercondylar fossa, but remained in a subluxated position anterior to the humeral tuberosity (Figure 5).

At three weeks, there was no right elbow swelling or pressure. However, right elbow valgus deformity, swelling anterior to the elbow fossa,

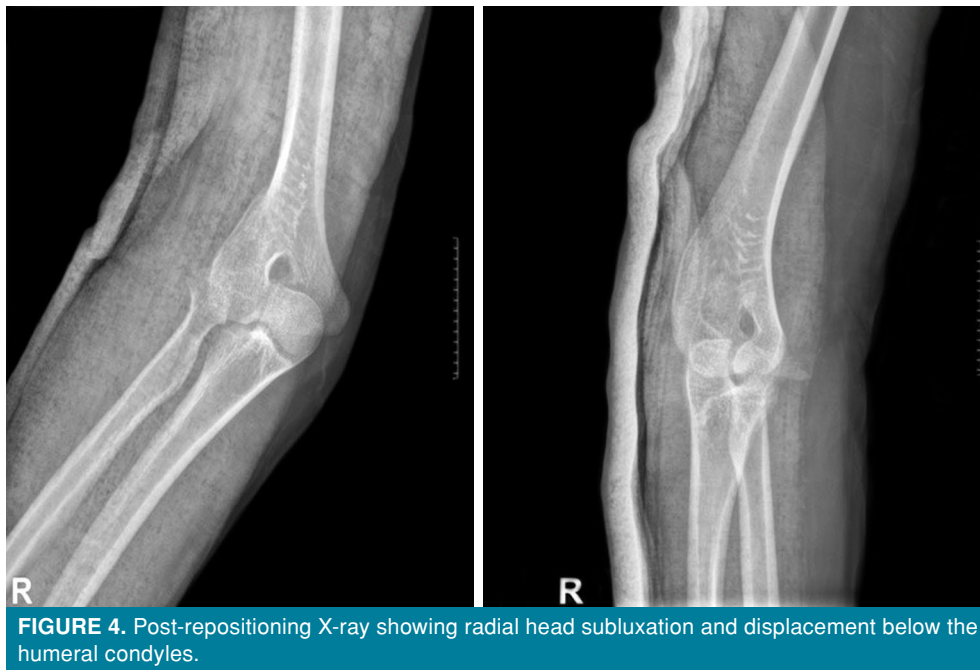

FIGURE 4. Post-repositioning X-ray showing radial head subluxation and displacement below the humeral condyles.

and limited range of right elbow motion (5 to 70°) were noted. Repeated X-ray did not reveal any changes in clinical findings (Figure 6). The patient was advised to exercise at home three times a day, including extreme flexion and extension for 5 to 10 sec after the hot application, and there were no obvious complaints of discomfort during this process. At six months of follow-up, the active range of right elbow motion included hyperextension of 5 to 115°, pronation of 80°, and supination of 45° relative to neutral (Figure 7). The patient revealed that the previous level of elbow joint function was

restored without significant impacts to personal or professional activities.

DISCUSSION

Radial head subluxation is the most common developmental anomaly of the elbow; it may occur unilaterally or bilaterally.^[1,6] Isolated radial head dislocation can occur during birth or postoperatively in patients with dislocated Monteggia fractures, ulnar varus, or other conditions.^[7] Most of these patients exhibit normal radial head morphology.^[8] However, patients with congenital

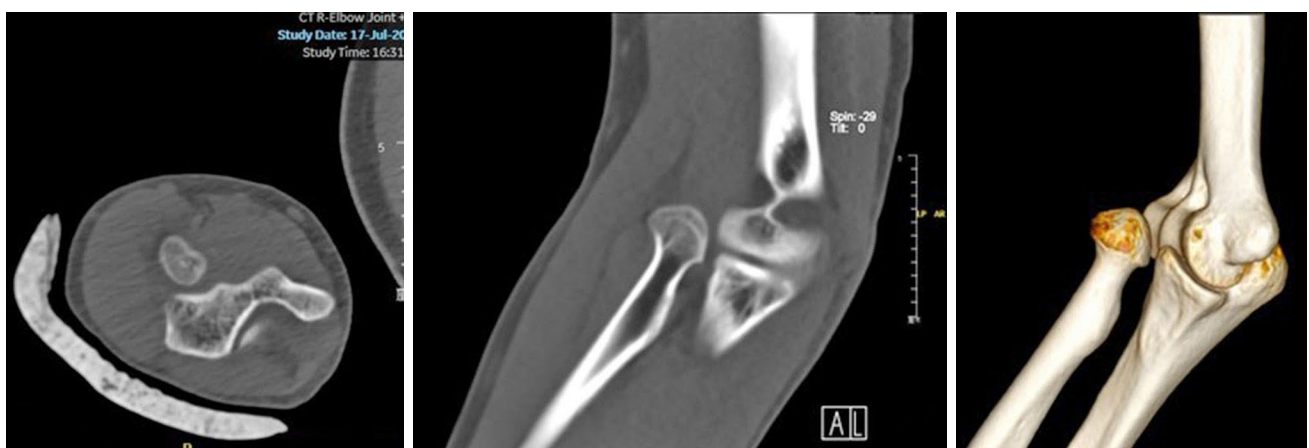

FIGURE 5. Post-repositioning computed tomography showing subluxation of the radial tuberosity, as well as a pencil-shaped radial head forming a pseudo-joint with the humeral tuberosity.

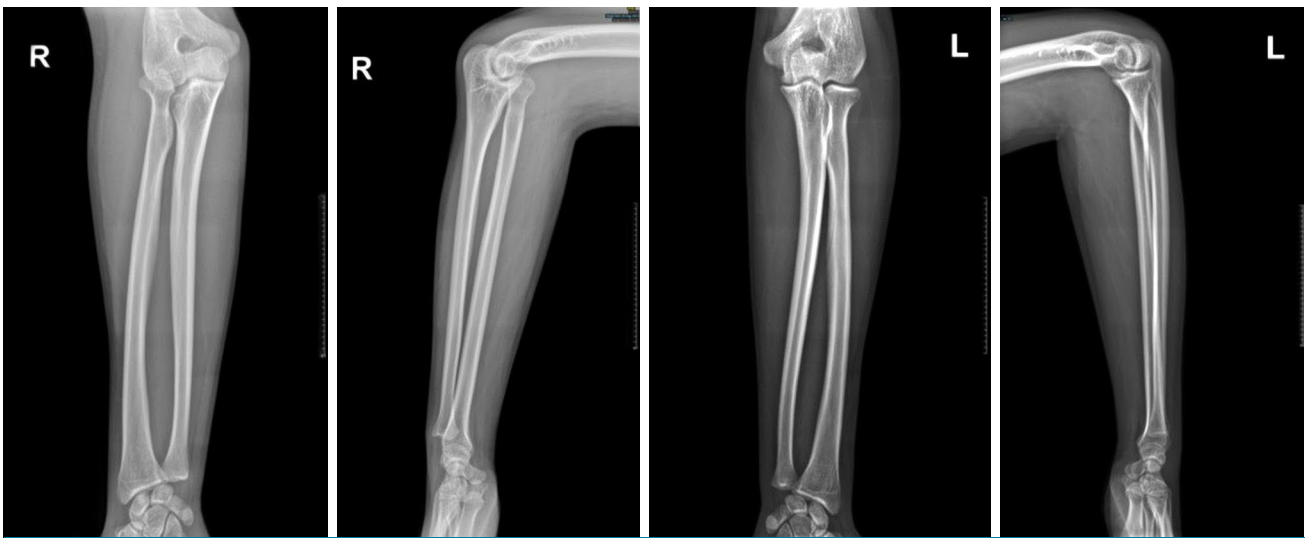

FIGURE 6. At 3 weeks after treatment, X-ray showed subluxation of the right radial tuberosity and normal morphology of the left radial tuberosity.

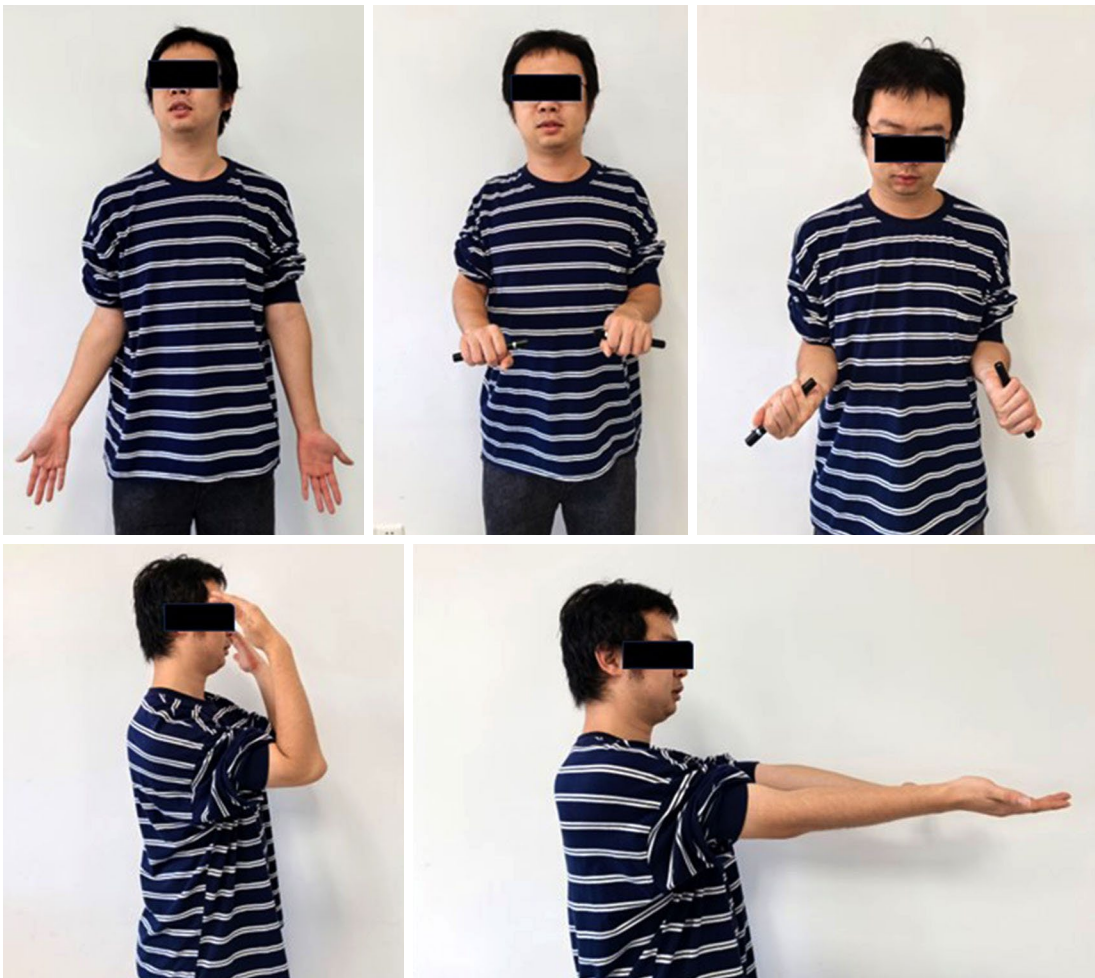

FIGURE 7. At 6 months after treatment, the patient had ranges of motion comprising 5 to 100° for flexion and extension and 80 to 50° for anterior and posterior rotation.

radial head dislocation often exhibit developmental deformities of the radial head, which typically appear as a dome-shape rather than a concavity.^[6,8] Infants with congenital radial head dislocation may be asymptomatic or have initially mild activity limitations, followed by elbow pain, snapping, valgus deformity, and decreased range of motion (ROM).^[9,10] Symptoms often do not become apparent until adulthood.

Congenital radial head subluxation is usually diagnosed on the basis of imaging features after exclusion of other diagnoses.^[6] Our patient was initially diagnosed with traumatic anterior dislocation of the right radial head during an outpatient clinic visit. However, subsequent imaging revealed abnormal radial head morphology, which prevented joint formation with the humeral head. Although he experienced right elbow joint pain and limited ROM, there was no definite history of trauma. Imaging revealed a typical dome-shaped radial head. Furthermore, there was no history of right elbow injury, and the patient experienced mild painless ROM limitation since childhood. Based on these findings, he was diagnosed with a congenital radial head abnormality. This case report highlights the potential progression of congenital radial head subluxation to complete dislocation, causing joint pain and constriction, even in the absence of trauma.

The variability of individual symptoms and wide age range of affected patients makes treatment selection challenging.^[2] The standard treatment for asymptomatic congenital radial head dislocation is careful observation.^[6] Although some patients demonstrate voluntary reducible recurrent anterior dislocation, the dislocation persists in most patients and does not decrease without open reduction.^[11-13] Operative interventions lead to positive outcomes in patients with traumatic dislocation; however, surgical treatment is rarely required and should be carefully administered in patients with congenital dislocation.^[2,6] Radial head resection leads to robust pain relief and satisfaction in patients with symptomatic, isolated, congenital radial head dislocation; it provides minimal improvement in forearm rotation and no improvement in elbow flexion or extension.^[6,11] However, radial head resection is only performed in patients with varus ulna or mild morphological abnormalities of the radial head, which prevent attachment of the humeral tuberosity convexity and radial head concavity. Additionally, more than 25% of treated limbs develop wrist pain and require

additional surgery.^[2] Arthroscopic release of the annular ligament is associated with less trauma and more rapid recovery in patients with refractory radial head dislocation.^[10] In our patient, the radial head was considerably enlarged, leading to bony entrapment due to the abnormal positions of the radial head and radial fossa after dislocation, and furthermore, MRI revealed that the radial head was located outside, rather than inside, of the annular ligament.^[14] Therefore, arthroscopy could not relieve the elbow impingement. Gao et al.^[15] performed open reduction and fixation of the radial head with annular ligament reconstruction and ulnar osteotomy in a 21-year-old man. Additionally, they trimmed the protruding dome-shaped articular surface of the radial head to fit within the intended anatomical joint space. However, the outcomes were not ideal; the patient experienced occasional pain and partial restriction of external rotation. Nevertheless, the instability during elbow flexion was resolved.

Consistent with our patient's desire to avoid surgery, manipulative repositioning was attempted, which was unsuccessful. Traumatic anterior dislocation of the radial head is typically restored by elbow flexion and rotation.^[7] However, in patients with abnormal radial head morphology and elbow socket entrapment, successful repositioning requires forearm rotation to release the entrapment while applying distal pressure on the radial head; subsequently, external rotation of the forearm must be performed while straightening the elbow joint. The acquisition of an accurate diagnosis based on imaging findings is essential for successful repositioning of congenital radial head dislocation.

The typical active range of elbow motion involves 0 to 140° of bending and straightening, along with 85° of turning the hand to face down or up and moving it toward or away from the body. For most daily activities, minimum functional ranges of motion are 30 to 130° for elbow bending and 50° for turning the hand palm-down and palm-up.^[16] Our patient did not experience any elbow pain or weakness, although he displayed elbow valgus and slight limitation of elbow flexion and additionally, he did not report a considerable impact on quality of life or learned elbow movements.^[14] However, the results of previous studies suggest that the throwing motion requires repetitive forearm rotation and elbow flexion and extension, which can lead to annular ligament laxity and spontaneous anterior dislocation of the radial head.^[11,15] Therefore, we

recommended our patient to avoid participation in such sports, yielding satisfactory outcomes.

In conclusion, congenital dislocation of the radial head without obvious symptoms can be usually observed, but if symptoms are obvious and it is difficult to reposition the radial head by manipulation, surgery may be indicated. In our case, the radial head deformity involved the radial fossa, causing elbow locking. Release of the bony entrapment facilitated successful manipulative repositioning.

Patient Consent for Publication: A written informed consent was obtained from the patient.

Data Sharing Statement: The data that support the findings of this study are available from the corresponding author upon reasonable request.

Author Contributions: Contributed to manuscript writing and editing: S.G.L.; Contributed to diagnosis and treatment: B.J.H.; Contributed to Treatment; all authors have read and approved the final manuscript: S.J.L.; Contributed to figure collection: D.Y.Z.

Conflict of Interest: The authors declared no conflicts of interest with respect to the authorship and/or publication of this article.

Funding: This work was supported by the Zhejiang Province Traditional Chinese Medicine Science and Technology Project (grant No. 2023ZF019).

REFERENCES

1. Agnew DK, Davis RJ. Congenital unilateral dislocation of the radial head. *J Pediatr Orthop* 1993;13:526-8. doi: 10.1097/01241398-199307000-00020.
2. Bengard MJ, Calfee RP, Steffen JA, Goldfarb CA. Intermediate-term to long-term outcome of surgically and nonsurgically treated congenital, isolated radial head dislocation. *J Hand Surg Am* 2012;37:2495-501. doi: 10.1016/j.jhssa.2012.08.032.
3. Błoński M, Podgórski A, Zakrzewski P, Pomianowski S. Surgical management of congenital radial head dislocation: A case report. *Ortop Traumatol Rehabil* 2012;14:385-91. doi: 10.5604/15093492.1005087.
4. Kim HJ, Kim PT, Lee HJ, Deslivia MF. Elbow locking in a patient with a congenital radial head dislocation: Case report. *Orthop Traumatol Surg Res* 2017;103:319-21. doi: 10.1016/j.otsr.2016.12.008.
5. Liu R, Miao W, Mu M, Wu G, Qu J, Wu Y. Ulnar rotation osteotomy for congenital radial head dislocation. *J Hand Surg Am* 2015;40:1769-75. doi: 10.1016/j.jhssa.2015.06.005.
6. Sachar K, Mih AD. Congenital radial head dislocations. *Hand Clin* 1998;14:39-47.
7. Jamieson RP, Ek ET. Isolated proximal radioulnar joint instability: Anatomy, clinical presentation, and current treatment options. *JBJS Rev* 2020;8:e0169. doi: 10.2106/JBJS.RVW.19.00169.
8. Kosay C, Akcali O, Manisali M, Ozaksoy D, Ozcan C. Congenital anterior dislocation of the radial head: A case with radiographic findings identical to traumatic dislocation. *Eur J Radiol* 2002;43:57-60. doi: 10.1016/s0720-048x(01)00424-7.
9. Kaas L, Struijs PA. Congenital radial head dislocation with a progressive cubitus valgus: A case report. *Strategies Trauma Limb Reconstr* 2012;7:39-44. doi: 10.1007/s11751-011-0126-z.
10. Maruyama M, Takahara M, Kikuchi N, Ito K, Watanabe T, Ogino T. Snapping elbow with congenital radial head dislocation: Case report. *J Hand Surg Am* 2010;35:981-5. doi: 10.1016/j.jhssa.2010.02.026.
11. Otoshi K, Kikuchi S, Igari T, Ejiri S, Konno S. Voluntary reducible recurrent anterior dislocation of radial head in juvenile baseball player. A case report and review of the literatures. *JSES Rev Rep Tech* 2023;3:436-42. doi: 10.1016/j.xrrt.2023.05.005.
12. Song KS, Ramnani K, Cho CH. Long term follow-up of open realignment procedure for congenital dislocation of the radial head. *J Hand Surg Eur Vol* 2011;36:161-2. doi: 10.1177/1753193410390131.
13. Yamazaki H, Kato H. Open reduction of the radial head with ulnar osteotomy and annular ligament reconstruction for bilateral congenital radial head dislocation: A case with long-term follow-up. *J Hand Surg Eur Vol* 2007;32:93-7. doi: 10.1016/j.jhsb.2006.09.003.
14. Atik OŞ. Writing for Joint Diseases and Related Surgery (JDRS): There is something new and interesting in this article! *Jt Dis Relat Surg* 2023;34:533. doi: 10.52312/jdrs.2023.57916.
15. Gao J, Tang J, Li M, Li H, Peng Y, Wang C, et al. Bilateral anterior congenital radial head dislocation in adults: A case report and literature review. *Front Surg* 2023;10:1155461. doi: 10.3389/fsurg.2023.1155461.
16. Oosterwijk AM, Nieuwenhuis MK, van der Schans CP, Mouton LJ. Shoulder and elbow range of motion for the performance of activities of daily living: A systematic review. *Physiother Theory Pract* 2018;34:505-28. doi: 10.1080/09593985.2017.1422206.