



# Histopathological and histomorphometric investigation of the effects of different irrigation solutions on Achilles tendon healing in rats

Yaşar Mahsut Dincel, MD<sup>1</sup>, Erdem Can, MD<sup>1</sup>, Sevil Karabag, MD<sup>2</sup>

<sup>1</sup>Department of Orthopedics and Traumatology, Medicine Faculty of Tekirdağ Namık Kemal University, Tekirdağ, Türkiye

<sup>2</sup>Department of Pathology, Medicine Faculty of Tekirdağ Namık Kemal University, Tekirdağ, Türkiye

Tendon injuries have emerged as a prevalent clinical issue, often linked to overuse or degenerative changes associated with aging. While the rotator cuff, forearm extensors, and Achilles tendon are generally recognized as areas prone to such injuries, the tibialis posterior tendon and patellar tendon are also highly susceptible.<sup>[1]</sup>

For full-thickness tears of the Achilles tendon, which is the most common injury site of the lower extremity, recent studies have reported comparable results of conservative treatment with accelerated rehabilitation in the early term with surgical treatment, while a debate on the subject continues.<sup>[2-5]</sup> By effectively minimizing complications, open surgical repair of Achilles tendon tears can yield positive functional results and low recurrence rates.<sup>[6]</sup> Nonetheless, wound

Received: July 24, 2023

Accepted: November 13, 2023

Published online: November 30, 2023

**Correspondence:** Erdem Can, MD. Tekirdağ Namık Kemal Üniversitesi Tıp Fakültesi, Ortopedi ve Travmatoloji Anabilim Dalı, 59030 Tekirdağ, Türkiye.

E-mail: erdemcan.md@gmail.com

Doi: 10.52312/jdrs.2023.1342

**Citation:** Dincel YM, Can E, Karabag S. Histopathological and histomorphometric investigation of the effects of different irrigation solutions on Achilles tendon healing in rats. Jt Dis Relat Surg 2024;35(1):186-193. doi: 10.52312/jdrs.2023.1342.

©2024 All right reserved by the Turkish Joint Diseases Foundation

This is an open access article under the terms of the Creative Commons Attribution-NonCommercial License, which permits use, distribution and reproduction in any medium, provided the original work is properly cited and is not used for commercial purposes (<http://creativecommons.org/licenses/by-nc/4.0/>).

## ABSTRACT

**Objectives:** This study aimed to examine the effect of irrigation fluids containing povidone-iodine (PVP-I), rifampicin (RF), and chlorhexidine gluconate (CHG) used during surgery on healing on a rat Achilles tendon model.

**Materials and methods:** Twenty-eight male Sprague-Dawley rats (range, 300 to 400 g) were used in the experiment carried out between November 2022 and December 2022. The rats were divided into PVP-I, RF, CHG, and control groups, with seven rats in each group. Following the tenotomy and repair of the right Achilles tendon, the surgical site was irrigated using PVP-I, RF, CHG, or normal saline (the control group) for 2 min. All rats were sacrificed on the 21<sup>st</sup> postoperative day. The samples were evaluated histomorphometrically using the scoring system modified by Svensson, Soslowsky, and Cook and histopathologically using the Bonar and Movin classifications.

**Results:** The RF group gave better results in all three scoring systems compared to the control, PVP-I, and CHG groups ( $p=0.008$ ,  $p=0.002$ , and  $p=0.006$ , respectively). Cellularity, rounding, and tenocyte morphology showed a significant difference in favor of the RF group ( $p=0.004$ ). While the distribution of ground substance glycosaminoglycans showed a significant difference in favor of the RF group, there was no significant difference among the other groups ( $p=0.22$ ).

**Conclusion:** Irrigation solutions containing PVP-I, RF, or CHG show no negative effect on Achilles tendon healing. Moreover, the findings suggest that RF irrigation can accelerate the healing process.

**Keywords:** Achilles, chlorhexidine, irrigation, povidone-iodine, rat, rifampicin, tendon healing.

necrosis poses a significant challenge to the rehabilitation process as it can hinder or alter the expected results and healing process. Moreover, the emergence of deep infections is a severe complication that often requires further surgical interventions and typically results in adverse outcomes.<sup>[7]</sup>

Tendons, similar to several other tissue types, are poorly vascularized, hypocellular, and heal slowly. In addition, healing often leads to the formation of fibrous tissue and scar tissue that lack flexibility and biomechanical properties.<sup>[8]</sup> The tendon healing process is complex, comprising three interlinked stages: inflammation, proliferation, and remodeling.<sup>[9]</sup> While the inflammatory phase is crucial for the healing process, elevated levels of proinflammatory cytokines can have adverse effects on tendon healing and potentially induce further damage.<sup>[10]</sup> It has been documented that maladaptive inflammation can also exert adverse effects on the regenerative phase.<sup>[11]</sup> In orthopedic surgery, antiseptics and antibiotics are commonly used as supplementary constituents in irrigation solutions, and extensive research has been conducted examining their effects on soft tissue toxicity. Another area of interest lies in assessing the efficacy of irrigation solutions in reducing bacterial load. However, there is no study in the literature investigating the effects of these solutions, particularly on tendon healing. The positive or negative effects of such irrigation solutions on the healing process of contaminated or aseptically repaired tendons are unknown.<sup>[12,13]</sup> Hence, the purpose of this study was to investigate the effects of irrigation solutions containing povidone-iodine (PVP-I), rifampicin (RF), and chlorhexidine gluconate (CHG), which may affect the early inflammation phase, on tendon healing with histopathological examinations.

## MATERIALS AND METHODS

The experimental study was conducted with 28 male Sprague-Dawley rats (range, 300 to 400 g) aged between three and four months between November 2022 and December 2022. Animals were subject to exclusion if they experienced any of the following conditions: death, infection at the incision site, or sample contamination. The current study included four groups: the control group (Group 1; normal saline irrigation), the PVP-I irrigation group (Group 2), the RF irrigation group (Group 3), and the CHG irrigation group (Group 4), each consisting of seven rats. Each group was housed separately in individual cages.

### Surgical procedure

All surgical procedures were conducted under inhaler anesthesia, utilizing a starting dose of 4% isoflurane (Isoflurane USP; Adeka Ilaç, İstanbul, Türkiye) for induction and maintenance at a dose of 2%. Preoperative antibiotic prophylaxis

was administered with 8 mg/kg gentamicin (Genthaver; Osel Ilaç, İstanbul, Türkiye), while pain control was ensured with 5 mg/kg carprofen (Rimadyl; Zoetis Inc., Parsippany, NJ, USA) for 48 h postoperatively. There were no movement restrictions imposed postoperatively, and the surgical procedures lasted approximately 20 min. All surgeries were performed on the right side of the rats, and no tourniquet was used.

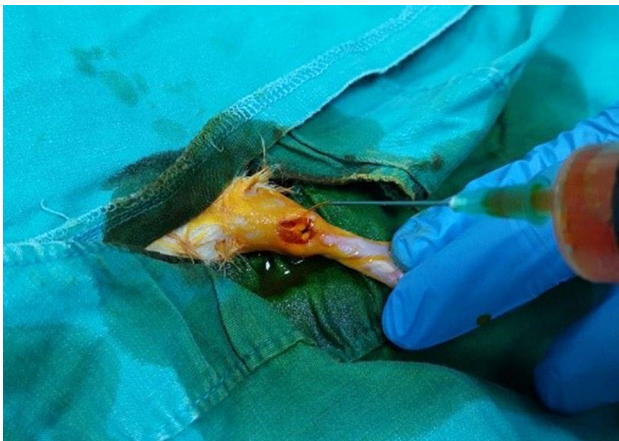This study employed a widely recognized rat tendon injury model.<sup>[14]</sup> After shaving the skin, the Achilles tendon in the right lower extremity was accessed using a posterior approach. The surrounding tissues were carefully stripped, and an incision was made with a scalpel approximately 5 mm proximal to the distal attachment site of the tendon. The tendon was then repaired via the modified Kessler method, using polypropylene 3/0 atraumatic sutures (Nevolene; Betatech Medical, İstanbul, Türkiye).

Following the repair, Group 1 received a 2-min irrigation with a 0.9% saline solution. Group 2 underwent a 2-min irrigation using a 1% PVP-I solution, Group 3 a 2-min irrigation using a 0.05% RF solution, and Group 4 a 2-min irrigation using a 0.05% CHG solution (Figure 1). Prior to skin closure, no additional washing procedures were performed.

The subcutaneous tissue and skin were closed using 2-0 propylene sutures (Nevolene; Betatech Medical, İstanbul, Türkiye) with an intermittent suture technique that conformed to the anatomical structure. On the 21<sup>st</sup> day, the rats were euthanized by cervical dislocation under inhaler anesthesia, and their right Achilles tendons were separated for histopathological examination in 20 mL of 10% formaldehyde solution to be delivered to the pathology clinic.

### Histopathological evaluation

Histopathological examinations were conducted by an impartial specialist pathologist who was unaware of the group assignments. Following 24 h of fixation in 10% formaldehyde and paraffin embedding, 4- $\mu$ m sections were obtained from each sample and stained with hematoxylin-eosin. The sections were then sealed using a fully automated sealing device. Microscopic evaluations were performed using a Olympus CX41 microscope (Olympus, Tokyo, Japan) (Figure 2). In addition to the scoring system modified by Svensson et al.,<sup>[15]</sup> Soslowsky et al.,<sup>[16]</sup> and Cook et al.,<sup>[17]</sup> the samples were also evaluated using the Bonar and Movin classification systems.<sup>[18]</sup>



**FIGURE 1.** Irrigation with 0.05% rifampicin solution following the repair of the Achilles tendon.

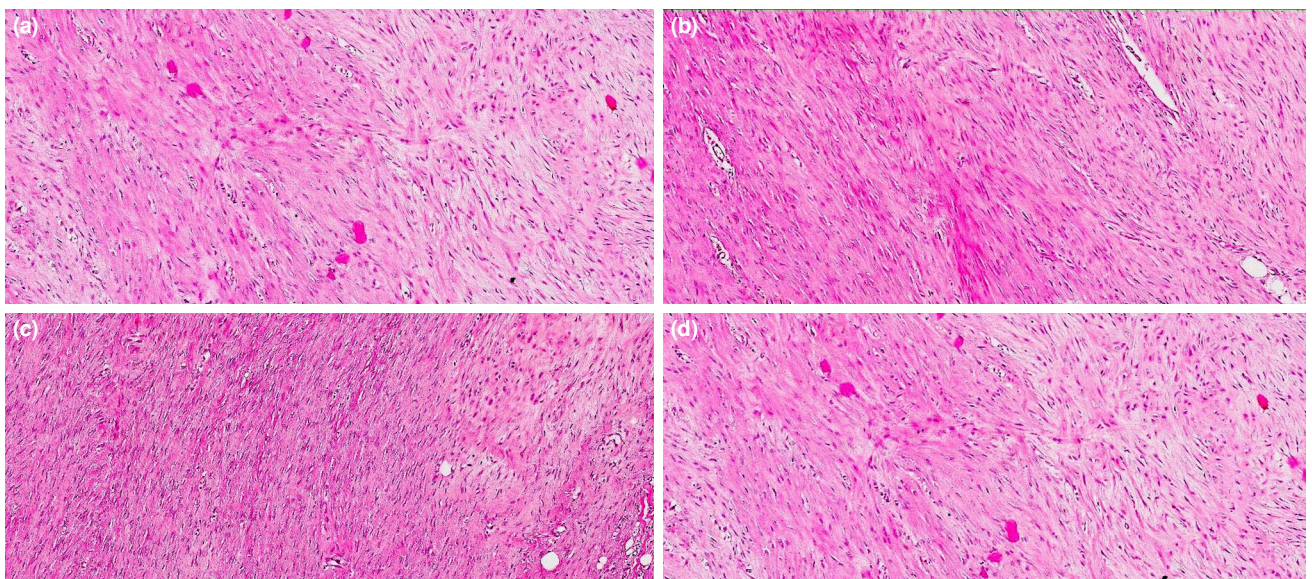
The modified scoring system developed by Svensson, Soslowsky, and Cook is notable for its comprehensive inclusion of cartilage formation as a key parameter alongside traditionally accepted factors, such as fiber structure, cellularity, and vascularity, among other existing classifications.

The Bonar scoring system provides a comprehensive evaluation of four specific parameters. First, the morphology and proliferation of tenocytes were evaluated by examining their structural integrity and cellular activity. Second, the presence or absence of ground substance is examined. In addition, the properties of collagen

bundles were analyzed, and the vascularity of the tissue was evaluated. On the other hand, the Movin scoring system includes a comprehensive analysis of eight parameters. First, fiber structure was thoroughly assessed, considering organization, alignment, and integrity. Second, fiber arrangement was examined to identify patterns and orientation. Cell rounding, regional cellularity variations, vascularity level, collagen staining, hyalinization presence, and glycosaminoglycan content were all evaluated. Each parameter was assessed using the Bonar and Movin scoring systems, with scores ranging from 0 to 3 representing optimal conditions. Higher scores on the Movin and Bonar scoring systems indicate insufficient healing, while lower scores indicate satisfactory improvement in the tissue properties examined.

#### Statistical analysis

Statistical analyses were performed using the IBM SPSS version 25.0 software (IBM Corp., Armonk, NY, USA). The assumption of normality of the variables was examined using both analytical methods, including the Kolmogorov-Smirnov and Shapiro-Wilk tests, and visual techniques, such as histograms and probability plots. Descriptive statistics, particularly measures of central tendency (mean and median) and variability (standard deviation), were calculated and reported for the normally distributed variables. In cases where the data did not comply with normal distribution, nonparametric tests were used in group



**FIGURE 2.** Sample stainings with hematoxylin & eosin ( $\times 100$ ). (a) Group 1 (control). (b) Group 2 (PVP-I treatment). (c) Group 3 (RF treatment). (d) Group 4 (CHG treatment).

comparisons. Specifically, the Mann-Whitney U test was utilized for two-group comparisons, while the Kruskal-Wallis test was employed for comparisons involving more than two groups. These tests were chosen due to their ability to analyze data conveniently without relying on the assumption of normality. A significance level of  $p < 0.05$  was employed to determine statistical significance.

## RESULTS

There were no fatalities among the animals in the study, and macroscopic and histopathological evaluations of the samples did not reveal any signs of infection. In the histopathological analysis, utilizing the modified Svensson, Soslowsky, and Cook classification system, no significant negative alterations were noted in the groups irrigated with PVP-I and CHG solutions compared to the control group. However, the RF irrigation group exhibited favorable results in terms of cellularity ( $p = 0.004$ ) and total score ( $p = 0.008$ , Table I).

According to the Bonar scoring system, a significant difference in favor of the RF irrigation group was observed regarding tenocytes ( $p = 0.004$ ), ground substance ( $p = 0.022$ ), and the total score ( $p = 0.002$ ) during the histopathological examination.

However, no significant differences were observed in the PVP-I and CHG groups compared to the control group (Table II).

According to the Movin scoring system, a significant positive difference was observed in the RF irrigation group regarding rounding ( $p = 0.004$ ), glycosaminoglycan distribution ( $p = 0.022$ ), and total score ( $p = 0.006$ ). Conversely, no significant changes were observed in the PVP-I and CHG groups compared to the control group (Table III).

## DISCUSSION

Irrigation solutions can be classified as normal saline, antiseptics, and those containing antibiotics.<sup>[19]</sup> Recent meta-analyses have reported that the administration of normal saline is not superior in preventing surgical site infections compared to no irrigation.<sup>[20,21]</sup> Moreover, the effectiveness of pressurized and pulsatile saline application is well known.<sup>[22]</sup> Commonly used antiseptics in wound irrigation include iodophors, CHG, hydrogen peroxide (HPO), and soap, with some studies exploring combinations of these agents in a one-to-one ratio.<sup>[19,23]</sup> Given the rise in antibiotic resistance and the potential cytotoxicity of antiseptic materials used in irrigation solutions,

**TABLE I**  
Statistical analysis among groups according to the modified Soslowsky, Svensson and Cook classification

	Control		Povidone-iodine		Rifampicin		Chlorhexidine		$p^*$
	Mean±SD	Median	Mean±SD	Median	Mean±SD	Median	Mean±SD	Median	
Fiber structure	1.86±0.38	2	1.86±0.38	2	1.29±0.49	1	1.57±0.54	2	0.086
Cellularity	2.00±0.00	2	1.71±0.49	2	1.14±0.38	1	1.86±0.38	2	<b>0.004</b>
Vascularity	2.71±0.49	3	2.71±0.49	3	2.43±0.54	2	2.86±0.38	3	0.392
Cartilage formation	2.43±0.54	1	1.29±0.49	1	0.71±0.49	1	1.43±0.54	1	0.072
Total	8.00±1.20	8	7.57±1.27	8	5.57±0.98	6	7.71±0.95	8	<b>0.008</b>

SD: Standard deviation; \* Kruskal-Wallis test (Mann-Whitney U test) ( $p < 0.05$ ). Significant  $p$  values are written in bold.

**TABLE II**  
Statistical analysis among groups according to the Bonar scoring system

	Control		Povidone-iodine		Rifampicin		Chlorhexidine		$p^*$
	Mean±SD	Median	Mean±SD	Median	Mean±SD	Median	Mean±SD	Median	
Tenocyte	2.00±0.00	2	1.71±0.49	2	1.14±0.38	1	1.86±0.38	2	<b>0.004</b>
Ground substance	1.42±0.53	1	1.71±0.49	2	0.71±0.49	1	1.43±0.53	1	<b>0.022</b>
Collagen	1.86±0.38	2	1.86±0.38	2	1.29±0.49	1	1.57±0.53	2	0.086
Vascularity	2.71±0.49	3	2.71±0.49	3	2.43±0.53	2	2.86±0.38	3	0.392
Total	8.00±0.58	8	8.00±1.41	8	5.57±0.98	6	7.71±0.49	8	<b>0.002</b>

SD: Standard deviation; \* Kruskal-Wallis test (Mann-Whitney U test) ( $p < 0.05$ ). Significant  $p$  values are written in bold.

**TABLE III**  
Statistical analysis among groups according to the Movin scoring system

	Control		Povidone-iodine		Rifampicin		Chlorhexidine		<i>p</i> *
	Mean±SD	Median	Mean±SD	Median	Mean±SD	Median	Mean±SD	Median	
Fiber structure	1.43±0.53	1	1.57±0.53	2	1.28±0.49	1	1.14±0.38	1	0.392
Fiber arrangement	1.43±0.53	1	1.86±0.38	2	1.57±0.53	2	1.71±0.49	2	0.392
Rounding	2.00±0.00	2	1.71±0.49	2	1.14±0.38	1	1.86±0.38	2	<b>0.004</b>
Regional cellularity variation	1.57±0.53	2	1.57±0.53	2	1.14±0.38	1	1.57±0.53	2	0.291
Increased vascularity	2.71±0.49	3	2.71±0.49	3	2.42±0.53	2	2.86±0.38	3	0.392
Decreased collagen stain	1.00±0.00	1	1.43±0.53	1	1.00±0.00	1	1.43±0.53	1	0.061
Hyalinization	1.00±0.00	1	1.00±0.00	1	1.00±0.00	1	1.00±0.00	1	1.000
GAG content	1.43±0.53	1	1.71±0.49	2	0.71±0.49	1	1.43±0.53	1	<b>0.022</b>
Total	12.57±1.13	13	13.57±2.07	13	10.28±1.25	10	13.00±1.15	13	<b>0.006</b>

SD: Standard deviation; \* Kruskal-Wallis test (Mann-Whitney U test) ( $p < 0.05$ ). Significant *p* values are written in bold.

it is crucial to exercise caution when selecting a solution. By making an appropriate choice, the potential complications, particularly infections, can be reduced.<sup>[24]</sup> Despite differences in surgical approaches among practitioners, there is a consensus on the implementation of standardized protocols covering a range of preoperative, intraoperative, and postoperative measures. These measures include antibiotic prophylaxis, surgical site depilation, and sterilization of barriers and instruments. However, the available evidence to support the use of surgical irrigation is limited, and there exist divergent preferences among surgeons. As a result, a consensus on this matter has not been reached.<sup>[24,25]</sup> In the current study, we investigated the effects of an antibiotic-containing irrigation solution (RF), which is commonly preferred in the clinic, on tendon healing, as well as antiseptic solutions (PVP-I and CHG), for which the evidence on the effects on tissue healing is limited.

Given their acute nature, the majority of the factors related to Achilles tendon injuries cannot be regulated at the time of surgery.<sup>[26]</sup> Therefore, irrigation becomes an essential component during surgery as it aids in the removal of dead tissue residues, reduces bacterial load, and eliminates foreign bodies. When properly applied, irrigation contributes to healing, as in ulcerated tissues and dirty wounds in standard surgical procedures.<sup>[24]</sup> However, although the surgery took 20 min on average in our animal experiment study, it has been reported that end-to-end open surgery time in clinical practice varies between 45 and 100 min in patients with Achilles tendon injury.<sup>[27]</sup> An animal study investigating the effects of irrigation

and dehydration with saline on Achilles tendon healing emphasized that prolonged exposure of the surgical site to air led to increased fibrosis and adversely affected tendon gliding and overall healing quality.<sup>[28]</sup>

In a joint study conducted by the orthopedics and microbiology departments,<sup>[28]</sup> the bactericidal and cytotoxic effects of antiseptics containing PVP-I, CHG, HPO, polyhexanide, and octenidine dihydrochloride on *Staphylococcus aureus* (*S. aureus*) and *Staphylococcus epidermidis*, which are frequently encountered in orthopedic surgery, and on human cells were investigated. The findings revealed that PVP-I, CHG, and octenidine dihydrochloride showed bactericidal effects in dilutions and preserved cell viability, while PVP-I yielded the most optimal results. In another study investigating the in vitro effects of PVP-I and HPO in various dilutions on chondrocytes and tenocytes,<sup>[29]</sup> it was determined that 0.3% PVP-I had the lowest toxicity and the tenocyte morphology and total histopathological scores of PVP-I and CHG-treated groups were consistent with the findings from in vitro studies. On the other hand, the current study, which included a group treated with an antibiotic (RF) solution, found no adverse effects on tendon healing. All these findings suggest the safe applicability of these solutions in orthopedic contexts.

Kaya et al.<sup>[30]</sup> examined the decontaminating effects of RF, gentamicin, fusidic acid, and saline-containing irrigation solutions on bone allografts contaminated with *S. aureus* and reported that the RF-containing solution exhibited the highest level of effectiveness. Apart from their beneficial

impact on decontamination, there are concerns regarding the potential effects of antibiotics on wound and bone healing in orthopedic surgeries. *In vitro* studies have demonstrated that RF, in combination with certain antibiotics, such as ciprofloxacin, minocycline, and penicillin, has a negative effect on osteoblasts.<sup>[31]</sup> In addition, in a clinical study, it was reported that topical RF allowed spontaneous bone healing in contaminated and decontaminated wounds without any negative effects.<sup>[32]</sup>

In a study investigating the effects of RF and PVP-I in patients with hand injuries requiring surgery, the superiority of RF in wound healing was demonstrated.<sup>[33]</sup> In another study on skin defect healing in rats, it was reported that the recovery rates did not differ at the end of the study (10 days), but RF had positive effects on collagen accumulation and shrinkage of the skin defect in the initial stage (third and seventh days).<sup>[34]</sup> A review of the literature indicates that various proinflammatory agents, such as interleukin-1 beta and tumor necrosis factor-alpha (TNF- $\alpha$ ), have been shown to impede the formation of type 1 collagen, leading fibroblasts to increase the synthesis of catabolic and inflammatory enzymes.<sup>[12,35]</sup> Notably, a study suggests that inhibiting TNF- $\alpha$  contributes to enhanced tendon strength following repair.<sup>[36]</sup> Additionally, De La Durantaye et al.<sup>[37]</sup> conducted research suggesting a positive correlation between a reduced macrophage population and increased strength during tendon healing. The hypothesis posits that early inflammation mitigation may positively influence tendon recovery, while an excessive presence of proinflammatory cytokines could potentially impede the healing process.<sup>[12]</sup> A study by Kim et al.<sup>[38]</sup> observed that RF exerts a suppressive effect on the secretion of inflammatory mediators, including cytokines, prostaglandin D<sub>2</sub>, and TNF- $\alpha$ , within human cell cultures. Moreover, their study elucidated that RF acts as an inhibitor of cyclooxygenase-2, which plays an integral role in inflammatory responses within human cellular systems.

In the current study, we found that PVP-I, RF, and CHG solutions did not have negative effects on tendon healing. However, upon histopathological examination, the RF group exhibited statistically significant positive effects on tendon healing. These findings align with the results reported in previous studies and could potentially be linked to the anti-inflammatory characteristics inherent in RF. Histopathologically, cellularity was better in the

RF group than in the control group in all three classifications, suggesting that recovery was faster. Additionally, all three scoring systems indicated a significant positive relationship between the RF group and parameters related to tenocyte structure, cell morphology, and total scores. This suggests that the current study supports the use of all three scoring systems for the assessment of tendon healing on the 21<sup>st</sup> day.

The current study had strengths and weaknesses. While existing literature has explored the effects of irrigation solutions on bacterial load and factors influencing tendon healing,<sup>[10]</sup> our study stands out as the first experimental investigation to assess the impact of irrigation solutions on tendon healing, providing valuable histopathological data. On the other hand, it should be noted that the study focused on a previously unexamined aspect and involved a limited number of experimental animals due to ethical considerations. Consequently, the absence of biomechanical correlation is a noteworthy limitation. Furthermore, the study did not assess type 1 and type 3 collagen levels using immunohistochemistry or polymerase chain reaction. The relatively short duration of surgery in our experimental animal model indicates a need for additional clinical studies. Nevertheless, this study can serve as a valuable reference for multidisciplinary evaluations involving a larger sample of animals or clinical investigations.

In conclusion, the irrigation solutions containing PVP-I, RF, or CHG demonstrated no adverse effects on Achilles tendon healing. These locally applied solutions can be safely employed during tendon surgery, as indicated by our findings. Furthermore, the results suggest that RF irrigation has the potential to expedite the healing process.

**Ethics Committee Approval:** The study protocol was approved by the Animal Experiments Local Ethics Committee of Tekirdağ Namık Kemal University (date: 26.09.2022, no: T2022-979). The study was conducted in accordance with the principles of the Declaration of Helsinki.

**Data Sharing Statement:** The data that support the findings of this study are available from the corresponding author upon reasonable request.

**Author Contributions:** Idea/concept, control/supervision, critical review, literature review: Y.M.D.; Design, data collection and processing, literature review, writing the article, references and fundings: E.C; Data collection and processing, analysis and interpretation, literature review, critical review, materials: S.K.

**Conflict of Interest:** The authors declared no conflicts of interest with respect to the authorship and/or publication of this article.

**Funding:** The authors received no financial support for the research and/or authorship of this article.

## REFERENCES

1. Wu F, Nerlich M, Docheva D. Tendon injuries: Basic science and new repair proposals. *EFORT Open Rev* 2017;2:332-42. doi: 10.1302/2058-5241.2.160075.
2. Kuşcu B, Bilal Ö, Doğar F, Topak D, Gürbüz K, Dere Kİ, et al. Effects of L-carnitine on healing of Achilles tendon in rats. *Jt Dis Relat Surg* 2023;34:84-91. doi: 10.52312/jdrs.2023.853.
3. Soroceanu A, Sidhwa F, Aarabi S, Kaufman A, Glazebrook M. Surgical versus nonsurgical treatment of acute Achilles tendon rupture: A meta-analysis of randomized trials. *J Bone Joint Surg [Am]* 2012;94:2136-43. doi: 10.2106/JBJS.K.00917.
4. Atik OS, Bölükbaşı S, Kanatlı U. Does surgical repair of acute Achilles tendon rupture cause structural changes on 15-year follow-up? *Eklemler Hastalıkları Cerrahisi* 2011;22:54-5.
5. Atik OŞ. Wear pattern on the bottom of tennis shoe after surgical repair of acute Achilles tendon rupture: 22-year follow-up. *Eklemler Hastalıkları Cerrahisi* 2019;30:65-7. doi: 10.5606/ehc.2019.002.
6. Bhandari M, Guyatt GH, Siddiqui F, Morrow F, Busse J, Leighton RK, et al. Treatment of acute Achilles tendon ruptures: A systematic overview and metaanalysis. *Clin Orthop Relat Res* 2002;400:190-200. doi: 10.1097/00003086-200207000-00024.
7. Pajala A, Kangas J, Ohtonen P, Leppilähti J. Rupture and deep infection following treatment of total Achilles tendon rupture. *J Bone Joint Surg [Am]* 2002;84:2016-21. doi: 10.2106/00004623-200211000-00017.
8. Gross G, Hoffmann A. Therapeutic strategies for tendon healing based on novel biomaterials, factors and cells. *Pathobiology* 2013;80:203-10. doi: 10.1159/000347059.
9. Sharma P, Maffulli N. Biology of tendon injury: Healing, modeling and remodeling. *J Musculoskelet Neuronal Interact* 2006;6:181-90.
10. Manning CN, Havlioglu N, Knutsen E, Sakiyama-Elbert SE, Silva MJ, Thomopoulos S, et al. The early inflammatory response after flexor tendon healing: A gene expression and histological analysis. *J Orthop Res* 2014;32:645-52. doi: 10.1002/jor.22575.
11. Arvind V, Huang AH. Reparative and maladaptive inflammation in tendon healing. *Front Bioeng Biotechnol* 2021;9:719047. doi: 10.3389/fbioe.2021.719047.
12. Wade RG, Burr NE, McCauley G, Bourke G, Efthimiou O. The comparative efficacy of chlorhexidine gluconate and povidone-iodine antiseptics for the prevention of infection in clean surgery: A systematic review and network meta-analysis. *Ann Surg* 2021;274:e481-8. doi: 10.1097/SLA.0000000000004076.
13. Hirsch T, Seipp HM, Jacobsen F, Goertz O, Steinau HU, Steintraesser L. Antiseptics in surgery. *Eplasty* 2010;10:e39.
14. Murrell GA, Lilly EG 3rd, Collins A, Seaber AV, Goldner RD, Best TM. Achilles tendon injuries: A comparison of surgical repair versus no repair in a rat model. *Foot Ankle* 1993;14:400-6. doi: 10.1177/107110079301400706.
15. Svensson M, Kartus J, Christensen LR, Movin T, Papadogiannakis N, Karlsson J. A long-term serial histological evaluation of the patellar tendon in humans after harvesting its central third. *Knee Surg Sports Traumatol Arthrosc* 2005;13:398-404. doi: 10.1007/s00167-004-0590-9.
16. Soslosky LJ, Carpenter JE, DeBano CM, Banerji I, Moalli MR. Development and use of an animal model for investigations on rotator cuff disease. *J Shoulder Elbow Surg* 1996;5:383-92. doi: 10.1016/s1058-2746(96)80070-x.
17. Cook JL, Feller JA, Bonar SE, Khan KM. Abnormal tenocyte morphology is more prevalent than collagen disruption in asymptomatic athletes' patellar tendons. *J Orthop Res* 2004;22:334-8. doi: 10.1016/j.orthres.2003.08.005.
18. Maffulli N, Longo UG, Franceschi F, Rabitti C, Denaro V, Movin and Bonar scores assess the same characteristics of tendon histology. *Clin Orthop Relat Res* 2008;466:1605-11. doi: 10.1007/s11999-008-0261-0.
19. Papadakis M. Wound irrigation for preventing surgical site infections. *World J Methodol* 2021;11:222-7. doi: 10.5662/wjm.v11.i4.222.
20. Ambe PC, Rombey T, Rembe JD, Dörner J, Zirngibl H, Pieper D. The role of saline irrigation prior to wound closure in the reduction of surgical site infection: A systematic review and meta-analysis. *Patient Saf Surg* 2020;14:47. doi: 10.1186/s13037-020-00274-2.
21. Mueller TC, Loos M, Haller B, Mihaljevic AL, Nitsche U, Wilhelm D, et al. Intra-operative wound irrigation to reduce surgical site infections after abdominal surgery: A systematic review and meta-analysis. *Langenbecks Arch Surg* 2015;400:167-81. doi: 10.1007/s00423-015-1279-x.
22. Nikfarjam M, Weinberg L, Fink MA, Muralidharan V, Starkey G, Jones R, et al. Pressurized pulse irrigation with saline reduces surgical-site infections following major hepatobiliary and pancreatic surgery: Randomized controlled trial. *World J Surg* 2014;38:447-55. doi: 10.1007/s00268-013-2309-x.
23. Ulivieri S, Toninelli S, Petrini C, Giorgio A, Oliveri G. Prevention of post-operative infections in spine surgery by wound irrigation with a solution of povidone-iodine and hydrogen peroxide. *Arch Orthop Trauma Surg* 2011;131:1203-6. doi: 10.1007/s00402-011-1262-0.
24. Barnes S, Spencer M, Graham D, Johnson HB. Surgical wound irrigation: A call for evidence-based standardization of practice. *Am J Infect Control* 2014;42:525-9. doi: 10.1016/j.ajic.2014.01.012.
25. van Meurs SJ, Gawlitta D, Heemstra KA, Poolman RW, Vogely HC, Kruyt MC. Selection of an optimal antiseptic solution for intraoperative irrigation: An in vitro study. *J Bone Joint Surg [Am]* 2014;96:285-91. doi: 10.2106/JBJS.M.00313.
26. O'Neill S, Watson PJ, Barry S. A delphi study of risk factors for achilles tendinopathy- opinions of world tendon experts. *Int J Sports Phys Ther* 2016;11:684-97.
27. Soldatis JJ, Goodfellow DB, Wilber JH. End-to-end operative repair of Achilles tendon rupture. *Am J Sports Med* 1997;25:90-5. doi: 10.1177/036354659702500118.
28. Saygi B, Yildirim Y, Cabukoğlu C, Kara H, Ramadan SS, Esemeli T. The effect of dehydration and irrigation on the healing of Achilles tendon: An experimental study. *Ulus Travma Acil Cerrahi Derg* 2008;14:103-9.

29. Romano V, Di Gennaro D, Sacco AM, Festa E, Roschetto E, Basso MA, et al. Cell toxicity study of antiseptic solutions containing povidone-iodine and hydrogen peroxide. *Diagnostics (Basel)* 2022;12:2021. doi: 10.3390/diagnostics12082021.
30. Kaya I, Sungur I, Yılmaz M, Pehlivanoğlu F, Kartyaşar K, Sengöz G. Comparison of the efficiency of different antibiotic irrigation solutions in decontamination of allografts contaminated with *Staphylococcus aureus*. *Acta Orthop Traumatol Turc* 2013;47:281-5. doi: 10.3944/aott.2013.3114.
31. Rathbone CR, Cross JD, Brown KV, Murray CK, Wenke JC. Effect of various concentrations of antibiotics on osteogenic cell viability and activity. *J Orthop Res* 2011;29:1070-4. doi: 10.1002/jor.21343.
32. Shiels SM, Tennent DJ, Lofgren AL, Wenke JC. Topical rifampin powder for orthopaedic trauma part II: Topical rifampin allows for spontaneous bone healing in sterile and contaminated wounds. *J Orthop Res* 2018;36:3142-50. doi: 10.1002/jor.24155.
33. Iselin F, Audren JL, Gouet O, Hautefort E, Peze W, Pradet G. Comparative study of the effects of a local antibiotic and a local antiseptic in emergency hand surgery. *Ann Chir Main Memb Super* 1990;9:65-71. French. doi: 10.1016/s0753-9053(05)80441-7.
34. Karapolat B, Karapolat S, Buran A, Kemal Okatan B. The effects of rifampicin on wound healing. *Annals of Medical Research* 2020;27:588-95. doi: 10.5455/annalsmedres.2019.10.662.
35. Tsuzaki M, Guyton G, Garrett W, Archambault JM, Herzog W, Almekinders L, et al. IL-1 beta induces COX2, MMP-1, -3 and -13, ADAMTS-4, IL-1 beta and IL-6 in human tendon cells. *J Orthop Res* 2003;21:256-64. doi: 10.1016/S0736-0266(02)00141-9.
36. Gulotta LV, Kovacevic D, Cordasco F, Rodeo SA. Evaluation of tumor necrosis factor  $\alpha$  blockade on early tendon-to-bone healing in a rat rotator cuff repair model. *Arthroscopy* 2011;27:1351-7. doi: 10.1016/j.arthro.2011.03.076.
37. de la Durantaye M, Piette AB, van Rooijen N, Frenette J. Macrophage depletion reduces cell proliferation and extracellular matrix accumulation but increases the ultimate tensile strength of injured Achilles tendons. *J Orthop Res* 2014;32:279-85. doi: 10.1002/jor.22504.
38. Kim SH, Lee KM, Lee GS, Seong JW, Kang TJ. Rifampicin alleviates atopic dermatitis-like response in vivo and in vitro. *Biomol Ther (Seoul)* 2017;25:634-40. doi: 10.4062/biomolther.2017.147.