









Comparing the outcomes of tripod technique and locked plate fixation for the treatment of Mason type 3 radial head fractures

İbrahim Faruk Adıgüzel, MD¹, Osman Orman, MD², Ethem Ayhan Ünkar, MD²,
Mehmet Baydar, MD², Mehmet Eren, MD², Kahraman Öztürk, MD³

¹Department of Hand Surgery, Etlik City Hospital, Ankara, Türkiye

²Department of Hand Surgery, University of Health Sciences, Baltalimanı Bone Diseases Training and Research Hospital, Istanbul, Türkiye

³Department of Hand Surgery, Acıbadem Fulya Hospital, Dikilitaş, Istanbul, Türkiye

The radial head plays an essential role in elbow joint biomechanics. The radiocapitellar joint stabilizes the elbow against the axial and valgus loads. The radial head is the major contributor to longitudinal stabilization of the forearm and prevents proximal migration of the radius. Approximately 60% of the elbow mechanical load is transmitted through the radial column and, following the excision of the radial head, axial load would be transmitted through the ulnar column.^[1,2]

Fractures of the radial head account for 17 to 19% of all cases of elbow traumas and 33% of all fractures involving the elbow.^[1] Treatment is initiated according to the type of fracture and accompanying

ABSTRACT

Objectives: In this study, we aimed to compare functional outcomes and complication rates of tripod technique and locked plate fixation used in Mason type 3 radial head fractures.

Patients and methods: Between January 2012 and December 2019, a total of 27 patients (16 males, 11 females; median age: 43.2 years; range, 20 to 68 years) with Mason type 3 radial head fractures were retrospectively analyzed. The patients were divided into two groups according to fixation method used. Group 1 consisted of 12 patients who were treated with tripod technique, and Group 2 consisted of 15 patients who were treated with locked plate fixation. Operation time, follow-up period, length of hospital stay, union time, Disabilities of Arm, Shoulder and Hand (DASH) scores, range of motions and complications were recorded.

Results: The median time to bone union was 46.7 days in Group 1, which was significantly shorter than Group 2 ($p < 0.001$). The median forearm pronation-supination arc was 123.75° (range, 30° to 180°) in Group 1 and was 94° (range, 45° to 180°) in Group 2. There was no significant difference in the forearm rotation between the groups. The median elbow flexion-extension arc was 99.17° (range, 65° to 130°) in Group 1 and was 80.33° (range, 30° to 130°) in Group 2. No statistically significant difference was found in the flexion-extension and pronation-supination arc degrees. There was no significant difference in the postoperative DASH scores between the groups ($p = 0.464$).

Conclusion: Our study results demonstrate that comparable results can be achieved in both techniques regarding functional outcome and range of motion. With a shorter union time and less complication rates, the tripod technique should be considered as the primary treatment method for the comminuted radial head fractures without a metaphyseal defect.

Keywords: Fracture fixation, Mason type 3 fracture, plate-screw fixation, radial head fracture, tripod technique.

Received: April 17, 2023

Accepted: July 11, 2023

Published online: September 20, 2023

Correspondence: İbrahim Faruk Adıgüzel, MD, Etlik Şehir Hastanesi, El Cerrahisi Kliniği, 06170 Yenimahalle, Ankara, Türkiye.

E-mail: ifarukadgzl@gmail.com

Doi: 10.52312/jdrs.2023.1161

Citation: Adıgüzel İF, Orman O, Ünkar EA, Baydar M, Eren M, Öztürk K. Comparing the outcomes of tripod technique and locked plate fixation for the treatment of Mason type 3 radial head fractures. *Jt Dis Relat Surg* 2023;34(3):716-723. doi: 10.52312/jdrs.2023.1161.

©2023 All right reserved by the Turkish Joint Diseases Foundation

This is an open access article under the terms of the Creative Commons Attribution-NonCommercial License, which permits use, distribution and reproduction in any medium, provided the original work is properly cited and is not used for commercial purposes (<http://creativecommons.org/licenses/by-nc/4.0/>).

injuries. Radial head fractures were first classified according to Mason classification.^[3] Non-displaced or minimally displaced (<2 mm) fractures were classified as type 1, displaced (>2 mm) fractures were classified as type 2, and displaced and multifragmentary fractures were classified as type 3. Medial collateral ligament (MCL) injury accompanies 54% of Mason type 3 fractures, and lateral ulnar collateral ligament (LUCL) injury is associated with 80% of the injuries. It has been shown via magnetic resonance imaging (MRI) that these injuries are accompanied by capitellar chondral defects and intraosseous membrane injuries.^[4,5]

Although radial head excision (RHE) has traditionally been used for Mason type 3 fractures, it has been largely discredited due to elbow joint instability, proximal migration of the radius, and posterolateral rotatory instability.^[6] Currently, metal prostheses stand out as the most successful treatment option for multifragmentary radial head fractures.^[6] Although there are many radial head prosthesis (RHP) designs, due to the complexity of the radial head anatomy and its highly variable structure, continued efforts have been carried out to improve existing designs.^[7] The risk of revision surgery is relatively high in young patients, due to early loosening, impingement and heterotopic ossification.^[8]

Internal fixation of Mason type 3 radial head fractures is quite difficult and challenging. Hotchkiss^[9] modified the Mason classification and described type 3 fractures as non-reconstructable fractures based on radiological and intraoperative configuration that often require resection. However, with the improvement of internal fixation methods, clinical and radiological results are reported as effective as RHP.^[10,11] Two methods evolved for internal fixation: fixation with locked plates and cross cannulated screwing (tripod technique) method. Despite the biomechanical studies showing that fixation with locked plates is superior in stabilization, some authors have reported that the tripod technique provides comparable stability.^[12,13] In addition, it has been suggested that the tripod technique yields earlier union and lower complication rates.^[14] To the best of our knowledge, there is no study comparing these two methods in the literature.^[15]

In the present study, we aimed to compare clinical and radiological results of two prominent methods, locked plate fixation and tripod technique which are alternatives to RHP in Mason type 3 fractures.

PATIENTS AND METHODS

This single-center, retrospective cohort study was conducted at University of Health Sciences, Baltalimanı Bone Diseases Training and Research Hospital, Department of Hand Surgery between January 2012 and December 2019. A total of 43 patients treated for Mason type 3 isolated radial head fracture by two different surgical teams were screened. While the first of these teams used locked plate fixation in Mason type 3 radial head fractures, the second team used the tripod technique with cross cannulated screws. The experience levels of members of both surgical teams consisting of hand and upper extremity surgeons were similar.^[16]

Inclusion criteria were as follows: age >18 years and having open reduction and internal fixation (ORIF) for the Mason type 3 radial head fractures. Sixteen patients who were under 18 years of age at the time of surgery (n=2), who had open fracture (n=1), who had fractures fixed with combined techniques (n=4), who had concomitant fractures of the elbow needed fixation (n=9), who had concomitant fractures of the ipsilateral upper extremity (n=3), who had a follow-up of <12 months (n=2) were excluded from the study. Finally, a total of 27 patients were included. The patients were divided into two groups according to fixation method used. Group 1 consisted of 12 patients who were treated with tripod technique, and Group 2 consisted of 15 patients who were treated with locked plate fixation.

Demographic data of the patients, injuries accompanying radial head fracture, elbow joint range of motion (ROM), union time, Disabilities of Arm, Shoulder and Hand (DASH) scores, complications and additional surgical interventions were collected from the patients' medical files. Clinical and radiographic evaluations were made at two, four, six weeks and at three, six, and 18 months.

Surgical technique

In both groups, the Kocher approach was used for exposure and the anconeus and the extensor carpi ulnaris muscle interval was dissected to reach the fracture. The annular ligament was incised and extended distally enough to allow for adequate exposure of the fracture fragments. The fracture fragments of the radial head were temporarily reduced with reduction clamps or Kirschner wires (K-wires), by preserving periosteal attachment as much as possible. Fracture fixations were made without completely removing the radial head.

In the tripod technique, a K-wire was inserted through fracture fragments before drilling. As the K-wires could easily break during drilling, special care was paid. The wires were placed in such a way that they did not collide with each other. The radial head fragments were fixed with 2.5-mm headless cannulated screws. Then, trials of pronation-supination were performed, and two more obliquely oriented headless cannulated screws were placed from the proximal radial head into proximal neck. In this technique, at least two headless compression screws placed orthogonally were used to achieve the fixation of the fracture fragments proximally and secured the fragments into the distal radial neck and, thus, rotational stability was

achieved. The screws were countersunk beneath the articular surface to prevent impingement (Figure 1).

In the locked plate technique, the dissection was extended toward the radius neck to place the plate accurately. The fragments of the radial head were fixed with a headless cannulated screw when necessary. Afterwards, the fixation was achieved with a proximal anatomical radius plate applied in the non-articular safe zone of the radial head (Figure 2).

In both techniques, the rotation arc must be checked after fracture fixation. The presence of impingement with forearm movements after fixation was checked in both groups. Annular ligament was

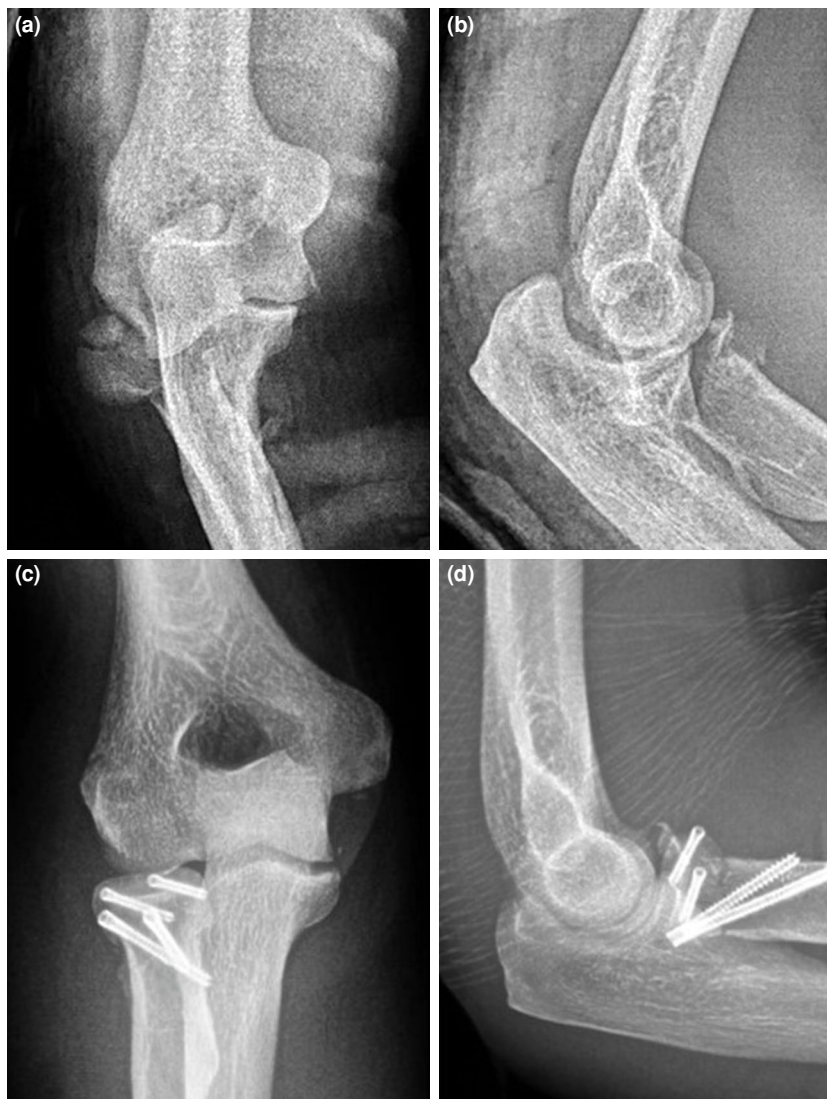
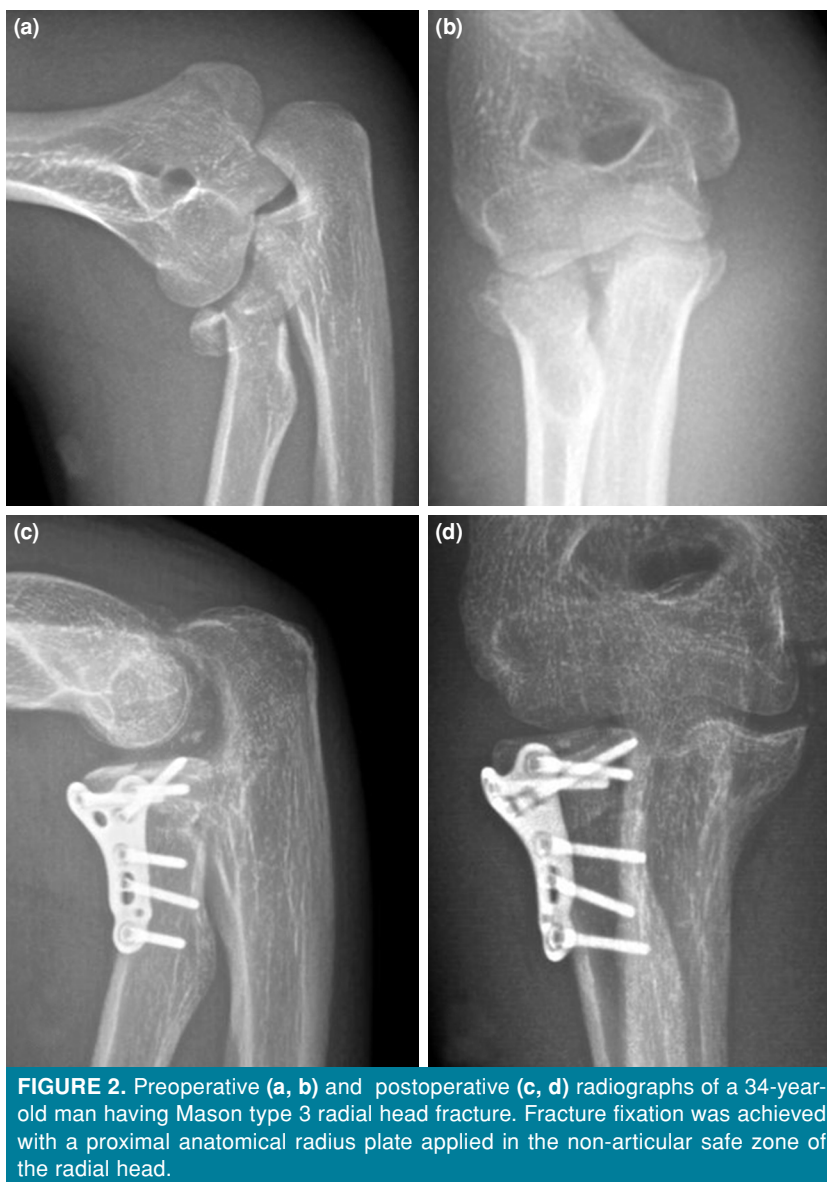
FIGURE 1. Anteroposterior (a) and lateral (b) radiographs of a 42-year-old man having Mason type 3 radial head fracture. (c) and (d) demonstrate postoperative radiographs of the healed radial head treated with tripod technique.



repaired in all cases. If there was damage to the lateral collateral ligament, it was fixed through the same incision. If there was a MCL injury, it was repaired with a medial approach.

An angle-adjustable hinged elbow brace was applied in the neutral position postoperatively and patients immobilized in the brace for the first 10 to 14 days after surgery. Elbow flexion and extension, rotation movements were allowed with an angle-adjustable elbow brace after 10 to 14 days and active motions were allowed after four weeks postoperatively. If the ligament repair was performed, active movement onset time was able to be delayed until six weeks postoperatively.

Statistical analysis

Statistical analysis was performed using the SPSS version 23.0 software (IBM Corp., Armonk, NY, USA). Continuous data were expressed in median (min-max), while categorical data were expressed in number and frequency. The distribution of the data was examined with histogram graphs. The chi-square test was used for categorical data and the Mann-Whitney U test was used for numerical independent groups. A p value of <0.05 was considered statistically significant.

RESULTS

Median follow-up period was 73.2 (range, 25 to 97) months in Group 1 and 84.8 (range, 26 to 109) months

TABLE I
Patient demographics according to surgical technique

	Group 1 (n=12)				Group 2 (n=15)				p
	n	%	Median	Min-Max	n	%	Median	Min-Max	
Age (year)			44.2	28-60			44.5	22-68	0.883
Sex									0.930
Male	8	67			8	53			
Female	4	33			7	47			
Mean follow-up (month)			73.2	25-97			84.8	26-109	0.744
Surgical side									0.722
Right	7	58			9	60			
Left	5	42			6	40			
Number of fracture fragments									0.756
Three	9	75			12	80			
Four	3	25			3	20			
Patients having accompanying injuries	6	50			9	60			0.603

in Group 2. During follow-up, complete clinical and radiographic data of the patients were obtained. Patient demographics according to the surgical technique are shown in Table I.

The rate of concomitant injuries was higher in Group 2. In Group 1, coronoid fractures were detected in three patients, LUCL rupture in two patients, and MCL rupture in one patient. In Group 2, radial head fracture was accompanied by coronoid fracture in four patients, LUCL rupture in three patients, and MCL rupture in two patients.

The union of the fracture was defined as bony bridging across the fracture site. Absence of pain with axial loading was accepted as a clinical examination

finding compatible with union. Bone union was achieved in a shorter time in Group 1 (median: 46.7 days) ($p < 0.001$). In the postoperative period, in Group 1, surgical release was performed in one patient due to heterotopic ossification, due to stiff elbow in another patient, and radial head resection and prosthesis was performed in one patient due to material failure. In Group 2, surgical release was performed in two patients due to stiff elbow, radial head resection due to material failure in one patient, radial head resection and prosthesis in one patient due to material failure, and tendon transfer after posterior interosseous nerve injury in one patient and debridement surgery was performed in one patient due to infection.

TABLE II
Intraoperative and postoperative data of the patients

	Group 1 (n=12)			Group 2 (n=15)			p
	n	Median	Min-Max	n	Median	Min-Max	
Duration of the surgery (min)		114.9	65-184		121.2	83-204	0.270
Hospital stay (day)		1.6	1-4		2.6	1-11	0.744
Union time (day)		45.7	38-68		71.7	52-104	<0.001
DASH Score		28.4	17.2-39.2		30.6	17.5-44.2	0.464
Flexion-Extension arc (deg)		99.2	60-130		80.3	30-130	0.162
Supination-Pronation arc (deg)		123.8	30-180		94	30-180	0.121
Complications							0.635
Minor	2			3			
Major	1			3			

DASH: Disabilities of arm, shoulder and hand.

The median forearm pronation-supination arc was 123.75° (range, 30° to 180°) in Group 1 and was 94° (range, 45° to 180°) in Group 2. There was no significant difference between the groups. The median elbow flexion-extension arc was 99.17° (range, 65° to 130°) in Group 1 and was 80.33° (range, 30° to 130°) in Group 2. No statistically significant difference was found regarding the flexion-extension and pronation-supination arc degrees. There was no significant difference in the postoperative DASH scores between the groups ($p=0.464$) (Table II).

DISCUSSION

In the present study, we evaluated the results of two different treatments applied in our clinic for the treatment of Mason type 3 fractures. In appropriate fractures with the use of tripod technique, favorable results were obtained in terms of union times, DASH scores, complications, and joint ROM.

Elbow biomechanics and the role of the radial head in load transfer and elbow stabilization have been well established recently. Currently, resection procedures carried out in multifragmentary fractures have been replaced by prosthesis or internal fixation methods to maintain radial length. Experimental studies have shown that laxity increases, and kinematics is impaired with radial head resection.^[17] Radial head resection can only be performed in stable elbows, since the entire axial load is carried by the ulnar column in case of radial head resection; however, the vast majority of Mason type 3 fractures are accompanied by injuries that impair elbow joint stability, such as collateral ligament injuries and interosseous membrane injuries. Therefore, radial head resection may be applied in very limited circumstances.^[6] Ikeda et al.^[11] retrospectively analyzed the outcomes of multifragmentary radial head fractures and concluded that cases treated with ORIF had better results than cases who had acute radial head resection. We also do not perform radial head resection as the acute treatment of the radial head fractures in our clinical practice, due to the serious elbow and wrist joint problems occurred in patients after acute radial head resection.

Radial head prostheses are used for non-reconstructable comminuted fractures. Radial head anatomy, however, is complex and highly diverse. Implants used for arthroplasty cannot fully replicate the anatomy of the radial head. Even under the most favorable conditions, it may not be possible to insert an anatomical RHP.^[18] In addition, the risk of heterotopic ossification is increased due to excessive

soft tissue dissection, which may result in decreased forearm and elbow joint ROM.^[19] That is why an attempt to achieve biological healing on the fracture line as much as possible remains the most correct method currently.

With the development of new techniques and implants for surgical treatment of multifragmentary radial head fractures, the interest in biological preservation of the radial head with internal fixation methods has increased. Plates, screws, and K-wires can be used for internal fixation; however, it is controversial that with which method better outcome can be obtained. Fixation strengths of plate-screw or headless cannulated screw fixation in radial head and neck fractures have been compared in biomechanical studies. It has been shown that plate-screw fixation and screw fixation alone provide fixation with similar strength and stiffness with comparable failure forces, stresses, and strains.^[13] However, locked plate has been thought to be more appropriate in axially unstable and comminuted neck fractures.^[20]

To obtain full forearm rotation and not to cause impingement at the proximal radioulnar joint, proper placement of the plate must be ensured at the safe zone of the radial head.^[21] In general, good to excellent results have been reported with plate fixation; however, severe limitation in pronation-supination arc may be observed in the postoperative period.^[22] Although acquired degrees of both flexion-extension and supination-pronation were lower in patients who had fixation with plate-screw, there was no statistically significant difference between the groups. More soft tissue dissection and profile thickness of the plate used may be the reason for the relative limitation of movement. Soft tissue dissection should be performed in the neck region to place the plate in the safe zone, which increases the risk of heterotopic ossification and devascularization of the radial head. The plates may irritate the surrounding tissues and cause adhesions in soft tissues, restriction in forearm rotation, loss of fixation, and painful crepitation.^[23] Although it was not expected in patients who were treated with tripod technique, release surgery was required in one of our patients due to heterotopic ossification after screw fixation. In addition, further soft tissue dissection required during plate application may also endanger the radial nerve. In Group 2, we encountered one patient who had a posterior interior nerve injury.

Complications related to locked plates can occur due to incompatibility of the plates due to the

anatomical variations of the radial head and neck. Burkhart et al.^[24] reported that that there was not necessarily a single plate design compatible with the complex anatomy of the radial head. Giannicola et al.^[25] reported that this incompatibility might cause implant failure, displacement of the fracture, non-union or elbow stiffness.

Metaphyseal defects can lead to valgus impaction, and plate fixation should be performed for these fractures. The cross cannulated screw technique is a good choice for fractures without a metaphyseal defect. Fixation using headless compression screws is a less invasive approach. Unlike the plate, the screws can be also placed outside the safe zone, on the fragments within the joint; therefore, less stiffness and over stuffing can be observed.^[26] In addition, the screws increase compression at the fracture line, stabilize the fracture and allow faster union with the effect of less periosteal stripping.^[27] In our study, the union time of the screw-fixed group was found to be significantly shorter.

Nonetheless, there are some limitations to this study such as single-center, retrospective design and a relatively small sample size. In addition, surgical procedures were performed by two different surgical teams. Although their experience levels were similar, there was no randomization, and the fractures were not fully standardized. Finally, longer-term follow-up data might have allowed us to evaluate arthrosis and heterotopic ossification more accurately.

In conclusion, similar ROM and satisfactory results were obtained in both groups in our study. Of note, the median union time was shorter with the tripod technique. Based on these findings, we recommend that the tripod technique should be the primary treatment method for the comminuted radial head fractures without metaphyseal defect. However, further multi-center, large-scale, long-term studies are needed to establish more reliable conclusions on this subject.

Ethics Committee Approval: The study protocol was approved by the University of Health Sciences Baltalimani Bone Diseases Training and Research Hospital Ethics Committee (date: 05.08.2022, no: 82-585). The study was conducted in accordance with the principles of the Declaration of Helsinki.

Patient Consent for Publication: A written informed consent was obtained from each patient.

Data Sharing Statement: The data that support the findings of this study are available from the corresponding author upon reasonable request.

Author Contributions: Idea/concept, materials, writing the article, critical review, analysis and/or interpretation, literature review: İ.F.A.; Design, writing the article, critical review, analysis and/or interpretation, literature review: O.O.; Analysis and/or interpretation, critical review: M.E.; Materials, data collection and/or processing: E.A.Ü; Control/ supervision, analysis and/or interpretation: M.B.; Control/ supervision, Design, critical review: K.Ö.

Conflict of Interest: The authors declared no conflicts of interest with respect to the authorship and/or publication of this article.

Funding: The authors received no financial support for the research and/or authorship of this article.

REFERENCES

- Zhang R, Wang X, Liu S, Ruan H, Xu J, Kang Q. Hinge positioning method of Ilizarov apparatus in correcting radial head luxation caused by multiple hereditary exostoses. *Jt Dis Relat Surg* 2022;33:40-50. doi: 10.52312/jdrs.2022.502.
- Hassan SE, Parks BG, Douguhui WA, Osbahr DC. Effect of distal ulnar collateral ligament tear pattern on contact forces and valgus stability in the posteromedial compartment of the elbow. *Am J Sports Med* 2015;43:447-52. doi: 10.1177/0363546514557239.
- MASON ML. Some observations on fractures of the head of the radius with a review of one hundred cases. *Br J Surg* 1954;42:123-32. doi: 10.1002/bjs.18004217203.
- Kaas L, Turkenburg JL, van Riet RP, Vroemen JP, Eygendaal D. Magnetic resonance imaging findings in 46 elbows with a radial head fracture. *Acta Orthop* 2010;81:373-6. doi: 10.3109/17453674.2010.483988.
- McGinley JC, Gold G, Cheung E, Yao J. MRI detection of forearm soft tissue injuries with radial head fractures. *Hand (N Y)* 2014;9:87-92. doi: 10.1007/s11552-013-9561-2.
- Hall JA, McKee MD. Posterolateral rotatory instability of the elbow following radial head resection. *J Bone Joint Surg [Am]* 2005;87:1571-9. doi: 10.2106/JBJS.D.02829.
- Hartzler RU, Morrey BF, Steinmann SP, Llusa-Perez M, Sanchez-Sotelo J. Radial head reconstruction in elbow fracture-dislocation: Monopolar or bipolar prosthesis? *Clin Orthop Relat Res* 2014;472:2144-50. doi: 10.1007/s11999-014-3672-0.
- Flinkkilä T, Kaisto T, Sirniö K, Hyvönen P, Leppilahti J. Short- to mid-term results of metallic press-fit radial head arthroplasty in unstable injuries of the elbow. *J Bone Joint Surg [Br]* 2012;94:805-10. doi: 10.1302/0301-620X.94B6.28176.
- Hotchkiss RN. Displaced fractures of the radial head: Internal fixation or excision? *J Am Acad Orthop Surg* 1997;5:1-10. doi: 10.5435/00124635-199701000-00001.
- Lindhovius AL, Felsch Q, Ring D, Kloen P. The long-term outcome of open reduction and internal fixation of stable displaced isolated partial articular fractures of the radial head. *J Trauma* 2009;67:143-6. doi: 10.1097/TA.0b013e31818234d6.
- Ikeda M, Sugiyama K, Kang C, Takagaki T, Oka Y. Comminuted fractures of the radial head. Comparison of resection and internal fixation. *J Bone Joint Surg [Am]* 2005;87:76-84. doi: 10.2106/JBJS.C.01323.

12. Burkhart KJ, Mueller LP, Krezdorn D, Appelman P, Prommersberger KJ, Sternstein W, et al. Stability of radial head and neck fractures: A biomechanical study of six fixation constructs with consideration of three locking plates. *J Hand Surg Am* 2007;32:1569-75. doi: 10.1016/j.jhsa.2007.08.023.
13. Rebgetz PR, Daniele L, Underhill ID, Öchsner A, Taylor FJ. A biomechanical study of headless compression screws versus a locking plate in radial head fracture fixation. *J Shoulder Elbow Surg* 2019;28:e111-6. doi: 10.1016/j.jse.2018.10.008.
14. Wu PH, Shen L, Chee YH. Screw fixation versus arthroplasty versus plate fixation for 3-part radial head fractures. *J Orthop Surg (Hong Kong)* 2016;24:57-61. doi: 10.1177/230949901602400114.
15. Atik OŞ. Which articles do the editors prefer to publish? *Jt Dis Relat Surg* 2022;33:1-2. doi: 10.52312/jdrs.2022.57903.
16. Tang JB, Giddins G. Why and how to report surgeons' levels of expertise. *J Hand Surg Eur Vol* 2016;41:365-6. doi: 10.1177/1753193416641590.
17. Beingessner DM, Dunning CE, Gordon KD, Johnson JA, King GJ. The effect of radial head excision and arthroplasty on elbow kinematics and stability. *J Bone Joint Surg [Am]* 2004;86:1730-9. doi: 10.2106/00004623-200408000-00018.
18. Frank SG, Grewal R, Johnson J, Faber KJ, King GJ, Athwal GS. Determination of correct implant size in radial head arthroplasty to avoid overlengthening. *J Bone Joint Surg [Am]* 2009;91:1738-46. doi: 10.2106/JBJS.H.01161.
19. Chen X, Wang SC, Cao LH, Yang GQ, Li M, Su JC. Comparison between radial head replacement and open reduction and internal fixation in clinical treatment of unstable, multi-fragmented radial head fractures. *Int Orthop* 2011;35:1071-6. doi: 10.1007/s00264-010-1107-4.
20. Gutowski CJ, Darvish K, Ilyas AM, Jones CM. Comparison of crossed screw versus plate fixation for radial neck fractures. *Clin Biomech (Bristol, Avon)* 2015;30:966-70. doi: 10.1016/j.clinbiomech.2015.07.001.
21. Smith GR, Hotchkiss RN. Radial head and neck fractures: Anatomic guidelines for proper placement of internal fixation. *J Shoulder Elbow Surg* 1996;5:113-7. doi: 10.1016/s1058-2746(96)80005-x.
22. Smith AM, Morrey BF, Steinmann SP. Low profile fixation of radial head and neck fractures: Surgical technique and clinical experience. *J Orthop Trauma* 2007;21:718-24. doi: 10.1097/BOT.0b013e31812e5168.
23. Neumann M, Nyffeler R, Beck M. Comminuted fractures of the radial head and neck: Is fixation to the shaft necessary? *J Bone Joint Surg [Br]* 2011;93:223-8. doi: 10.1302/0301-620X.93B2.24760.
24. Burkhart KJ, Nowak TE, Kim YJ, Rommens PM, Müller LP. Anatomic fit of six different radial head plates: Comparison of precontoured low-profile radial head plates. *J Hand Surg [Am]* 2011;36:617-24. doi: 10.1016/j.jhsa.2010.12.028.
25. Giannicola G, Manauzzi E, Sacchetti FM, Greco A, Bullitta G, Vestri A, et al. Anatomical variations of the proximal radius and their effects on osteosynthesis. *J Hand Surg Am* 2012;37:1015-23. doi: 10.1016/j.jhsa.2012.02.005.
26. Duckworth DG, Avakian Z, Chien C. Newly defined fracture pattern specific to Mason III radial head fractures: Fracture description, management and outcomes using screw fixation. *ANZ J Surg* 2012;82:434-8. doi: 10.1111/j.1445-2197.2012.06094.x.
27. Zwingmann J, Welzel M, Dovi-Akue D, Schmal H, Südkamp NP, Strohm PC. Clinical results after different operative treatment methods of radial head and neck fractures: A systematic review and meta-analysis of clinical outcome. *Injury* 2013;44:1540-50. doi: 10.1016/j.injury.2013.04.003.