



Comparison of plaster cast and open reduction internal fixation in delayed fourth and fifth carpometacarpal fracture-dislocations

Uğur Bezirgan, MD¹, Erdiñç Acar, MD², Nuri Ülgen, MD², Merve Dursun Savran, MD¹, Mehmet Armangil, MD¹

¹Department of Orthopedics and Traumatology, Hand and Upper Extremity Surgery Division, Ankara University Faculty of Medicine, Ankara, Türkiye

²Department of Orthopedics and Traumatology, Hand and Upper Extremity Surgery Division, Ankara City Hospital, Ankara, Türkiye

The fourth and fifth carpometacarpal (CMC) fracture-dislocations of the hand are rare injuries and are usually reported as case series in the literature. Dislocation of the CMC joint is associated with less than 1% of all hand trauma cases.^[1] Carpometacarpal fracture-dislocations can occur due to direct trauma, such as punching in a fight, or indirect trauma, such as falling on the hand.^[2] Ulnar CMC joints are prone to dislocation due to their shallower, more mobile saddle anatomic structure and loose ligamentous connections.^[3] In a typical injury, the fourth and fifth CMC joints usually present with dislocation, as they are less stable than the first three metacarpals. Of note, CMC fracture-dislocations are more common in the fifth CMC than in the fourth one.^[4] The addition

Received: December 16, 2022

Accepted: December 27, 2022

Published online: April 26, 2023

Correspondence: Erdiñç Acar, MD, Ankara Şehir Hastanesi, Ortopedi ve Travmatoloji Kliniđi, El ve Üst Ekstremitte Cerrahisi Bölümü, 06800 Çankaya, Ankara, Türkiye.

E-mail: erdal240@gmail.com

Doi: 10.52312/jdrs.2023.851

Citation: Bezirgan U, Acar E, Ülgen N, Dursun Savran M, Armangil M. Comparison of plaster cast and open reduction internal fixation in delayed fourth and fifth carpometacarpal fracture-dislocations. Jt Dis Relat Surg 2023;34(2):315-324. doi: 10.52312/jdrs.2023.851.

©2023 All right reserved by the Turkish Joint Diseases Foundation

This is an open access article under the terms of the Creative Commons Attribution-NonCommercial License, which permits use, distribution and reproduction in any medium, provided the original work is properly cited and is not used for commercial purposes (<http://creativecommons.org/licenses/by-nc/4.0/>).

ABSTRACT

Objectives: This study aims to compare the clinical, radiological, and functional outcomes of the late-presenting ulnar carpometacarpal (CMC) joint injuries treated conservatively with plaster cast versus treated surgically with open reduction internal fixation (ORIF).

Patients and methods: Between May 2019 - October 2021, a total of 28 patients (26 males, 2 females; mean age: 32.2±10.3 years; range, 20 to 59 years) who were treated conservatively or surgically were retrospectively analyzed. Fourteen patients operated with ORIF were included in the first group (surgery group), and 14 patients followed conservatively with a plaster cast were included in the second group (conservative group). The patients were classified according to Cain's classification and the AO Foundation and Orthopedic Trauma Association (AO/OTA) classification. The patients were evaluated in terms of pulp palm distance (PPD), Visual Analog Scale (VAS), Disabilities of the Arm, Shoulder and Hand (DASH) score, grip strength, time to return to work, follow-up time, and presence of complications.

Results: No significant difference was found in terms of the pain and functional scores. In the conservative group, the grip strength of the injured side was significantly lower than the healthy side ($p=0.0093$). The patients with and without metacarpal fracture subluxation/dislocation were evaluated separately, and the grip strength of the fractured side in the subluxation/dislocation group was found to be significantly higher in the surgery group than the conservative group ($p=0.0237$). In the group with subluxation/dislocation, the recovery time increased, as the time to treatment increased. In three patients in the conservative group, the PPD values were 2, 3, and 4 mm, respectively while it was 0 mm for all in the surgery group.

Conclusion: The non-bridging dorsal buttress plate technique with or without a Kirschner wire is effective in patients with delayed ulnar CMC fracture-dislocations. Although surgery is associated with longer time to return to work, long-term results obtained with anatomical reduction of the joint are satisfactory for manual workers.

Keywords: Carpometacarpal, cast, dislocation, open reduction internal fixation.

of the fourth CMC joint to the injury pattern is due to the involvement of the hamate bone in both the fourth and fifth CMC joints.

As these injuries are usually overlooked in the first examination due to edema in the hand and misinterpretation of X-rays, pain, decreased grip strength, and degenerative arthritis are seen in the late period.^[5] Misdiagnosis leads to inadequate treatment, resulting in malunion and residual subluxation. Salvage surgery in painful fifth CMC joint arthritis unresponsive to conservative treatment is the fifth CMC joint arthroplasty.^[6] In our daily practice, we often encounter missed ulnar CMC injuries as impending malunions.

In the literature, there is no consensus regarding the treatment method for missed CMC injuries in the late period.^[7] In the present study, we, therefore, aimed to compare the clinical, radiological, and functional outcomes of late-presenting ulnar CMC joint injuries with conservative treatment with plaster cast versus open reduction internal fixation (ORIF).

PATIENTS AND METHODS

This single-center, retrospective cohort study was conducted at Ankara Bilkent City Hospital Orthopedics and Traumatology Department, Hand Surgery Subunit between May 2019 - October 2021. Neglected or missed ulnar CMC joint injuries admitted to our hand surgery outpatient clinic were reviewed. To diagnose a CMC fracture-dislocation on the posteroanterior (PA) hand radiograph, metacarpal cascade lines were drawn along the central longitudinal axis of each metacarpal.^[8] The intersection of all lines proximal to the distal radius articular surface was considered normal. Deterioration of the parallelism of the lines drawn along the axis of the metacarpals on the hand radiograph suggested a fractured dislocation (Figure 1). Oblique radiographic images taken with the hand at 30° pronation are mandatory.^[9] Computed tomography (CT) images were also helpful in patients in whom the definitive diagnosis could not be made based on X-ray images.

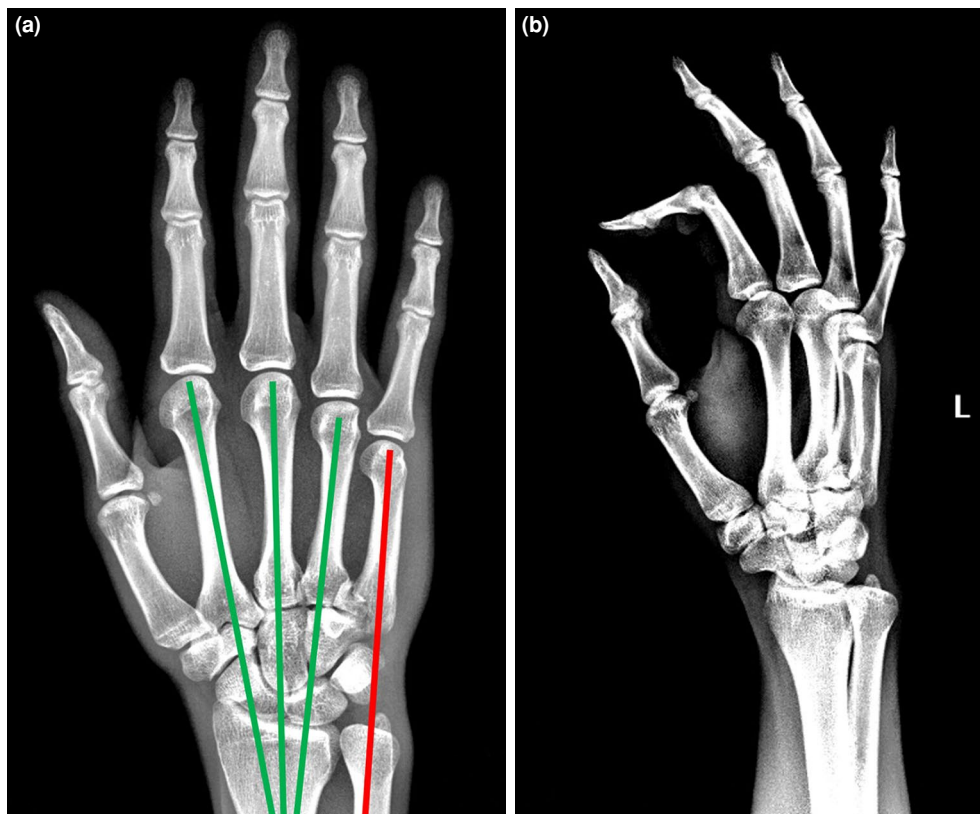


FIGURE 1. Pre- and postoperative X-ray images of a patient treated surgically. (a) AP X-ray with metacarpal cascade lines. Lines are drawn along the axis of the metacarpals; green indicates anatomic, and red indicates dislocation, as it does not intersect with the others. (b) Preoperative oblique X-ray.

A total of 28 patients (26 males, 2 females; mean age: 32.2±10.3 years; range, 20 to 59 years) who were treated conservatively or surgically were included. Fourteen patients operated with ORIF were included in the first group (surgery group), and 14 patients followed conservatively with a plaster cast were included in the second group (conservative group). In the surgery group, the time elapsed since the trauma, the presence of subluxation or dislocation with the fracture, classification of the injury, fixation materials used in surgery, and the osteotomy application were recorded in detail. In the conservative group, subluxation or dislocation with the fracture, injury classification, time elapsed since trauma, and plaster application time were recorded. Both groups were evaluated in terms of pulp palm distance (PPD), Visual Analog Scale (VAS), Disabilities of the Arm, Shoulder and Hand (DASH) score, grip strength, time to return to work, patient follow-up time, and presence of complications. In the surgery group, the patients treated with a dorsal buttress plate were immobilized for two weeks, and patients treated with an additional Kirschner wire (K-wire) to a dorsal buttress plate were immobilized in a short arm splint for four weeks. Considering the fracture classification, the cast group was immobilized for three to eight weeks. Bone healing was defined as the disappearance of the fracture line and cortical callus bridge on X-rays.

Surgical technique

The procedure was performed under regional or general anesthesia using tourniquet control. The dorsal ulnar incision was used to visualize the fourth and fifth CMC joints. Care was taken to preserve the dorsal sensory branch of the ulnar nerve. The extensor digitorum communis tendon to the little finger was retracted radially, and the extensor digiti minimi was retracted ulnarly. The dorsal cortex of the hamate and the base of the metacarpals (fourth and/or fifth) were, then, exposed. The bone callus was gently debrided, and osteotomy was performed following the fracture lines. The joint was irrigated, the articular surface was reduced, and temporary fixation was achieved with multiple temporary K-wires. The non-bridging dorsal buttress plate was fixed to the metacarpal base and, then, the stability of the fixation was checked. Typically, a 1.5 to 2.0-mm locking plate system was used. Once residual instability due to dorsal ligament insufficiency was suspected, fixation with a K-wire crossing the joint was added.

Statistical analysis

Statistical analysis was performed using the StataMP13 (StataCorp LLC., College Station, TX, USA).

Descriptive data were expressed in mean ± standard deviation (SD), median (min-max) or number and frequency, where applicable. The Shapiro-Wilk test was used for normality analysis. The chi-square and Fisher exact tests were applied for categorical variables. The t-test was used for parametric data, and the Mann-Whitney U test was used for non-parametric data in pairwise group comparisons. In multi-group comparisons, the analysis of variance (ANOVA) test was used for parametric data, while the Kruskal-Wallis test was used for non-parametric data. The Wilcoxon test was used to analyze differences between the groups, while the Friedman test was used for multiple comparisons. In the correlation analysis, the Pearson correlation test was used if both variables were parametric, and the Spearman correlation test was used if any variable was non-parametric. For Spearman rho values, 0.01-0.09 was unrelated, 0.1-0.29 weakly correlated, 0.3-0.59 partially correlated, 0.60-0.79 moderately correlated, and >0.8 strongly correlated, according to Chan YH.^[10] A *p* value of <0.05 was considered statistically significant.

RESULTS

The fourth metacarpal base fracture was seen in 12 (42.86%) patients, and the fifth metacarpal base fracture was seen in 26 (92.86%) patients. Ten patients had fractures of both the fourth and fifth metacarpal base. In 12 (42.86%) patients, the fracture was accompanied by subluxation or dislocation. The patients with accompanying subluxation/dislocation were classified according to Cain et al.^[11] and those who did not were classified according to AO Foundation and Orthopedic Trauma Association (AO/OTA).^[12]

The mean time to treatment after trauma was 17.9±12.3 (range, 5 to 61) days. This period was 17.9±9.7 (range, 8 to 46) days in the surgery group and 17.8±14.9 (range, 5 to 61) days in the conservative group, indicating no significant difference between the two groups (*p*=0.5336).

In the surgery group, except for one patient, 1.5 plates were used in eight patients, and 2.0 plates were used in six patients. Figure 2 is an example of fixation with plates. In seven (50%) patients in the surgery group, an additional joint bridging K-wire was used, as the structure of the joint ligaments was impaired. Figure 3 is an example of fixation with K-wires in addition to plates. No ligament reconstruction was performed in patients with K-wire fixation. The K-wires were removed in an average of 62.7±35.6 (range, 35 to 140) days. Since bone callus was already formed in 10 (71.43%) patients, an osteotomy was performed following the fracture lines.

In the conservative group, traction and the closed reduction (CR) maneuver were performed. The patients were immobilized in a short arm ulnar gutter cast for a mean of 4.3 ± 1.4 (range, 3 to 8) weeks.

The mean follow-up was 13.0 ± 5.8 (range, 6 to 25) months. While this duration was 16.6 ± 5.8 (range, 6 to 25) months in the surgery group, it was 9.4 ± 3.1 (range, 6 to 12) months in the conservative group, indicating a significantly shorter follow-up time in the conservative group ($p=0.0004$). All patients had radiological bone healing on follow-up X-rays.

The pain, functional score, grip strength, recovery time, and complication status of the patients are given in Table I. While there was no significant difference between the groups in terms of pain and

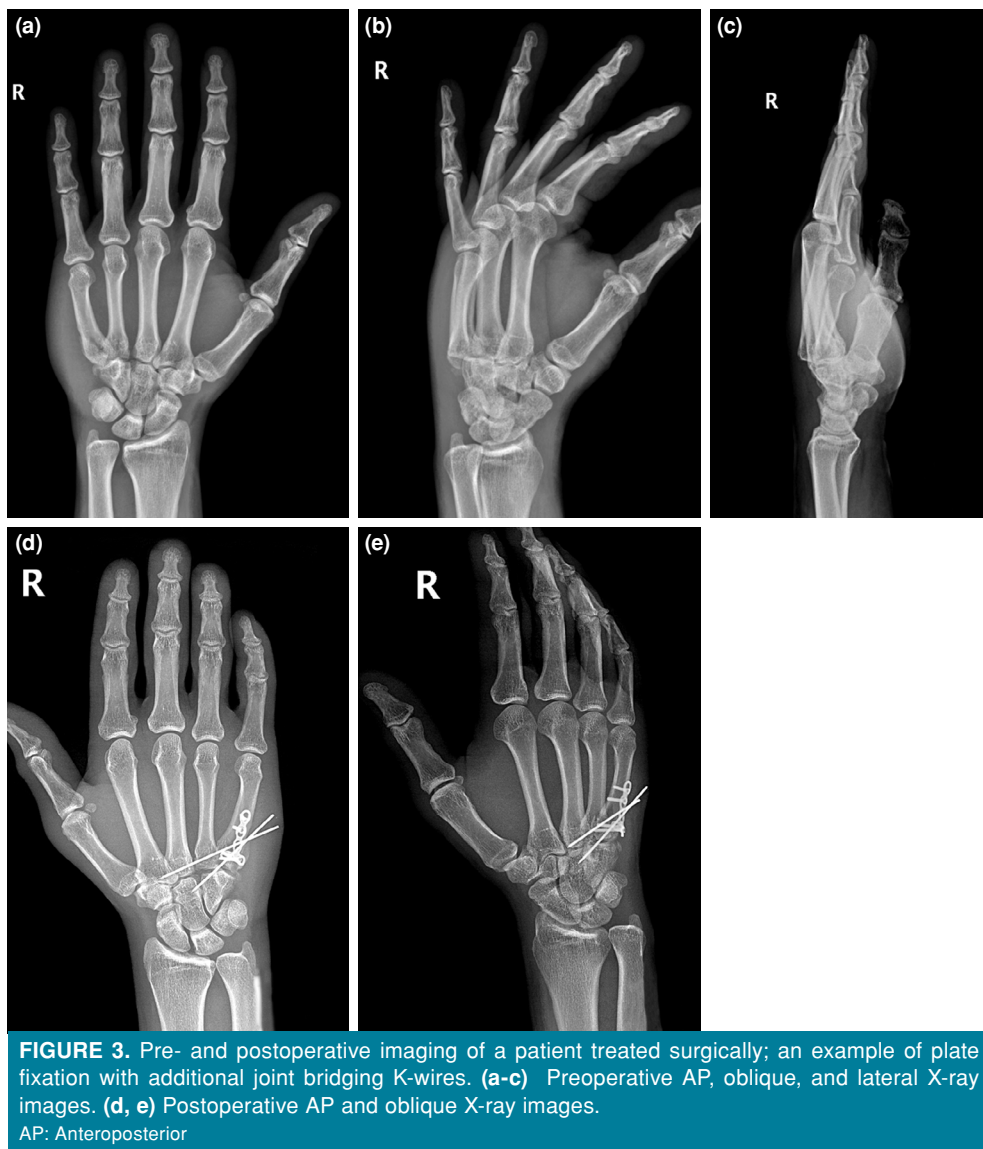
functional scores, the grip strength compared to the non-injured side was significantly lower in the conservative group ($p=0.008$). Also, the grip strength difference between the fractured and healthy sides was significantly higher in the conservative group ($p=0.0093$). The mean time to return to work after fracture was 2.0 ± 0.87 (range, 1 to 4) months. While this period was 2.3 ± 0.7 (range, 1.5 to 5) months in the surgery group, it was 1.8 ± 1.0 (range, 1 to 4) months in the conservative group, indicating a significantly shorter time to return to work in the conservative group ($p=0.0063$).

The patients with and without subluxation/dislocation of metacarpal fracture were evaluated separately, and the results are given in Table II. No significant difference was found in the pain and

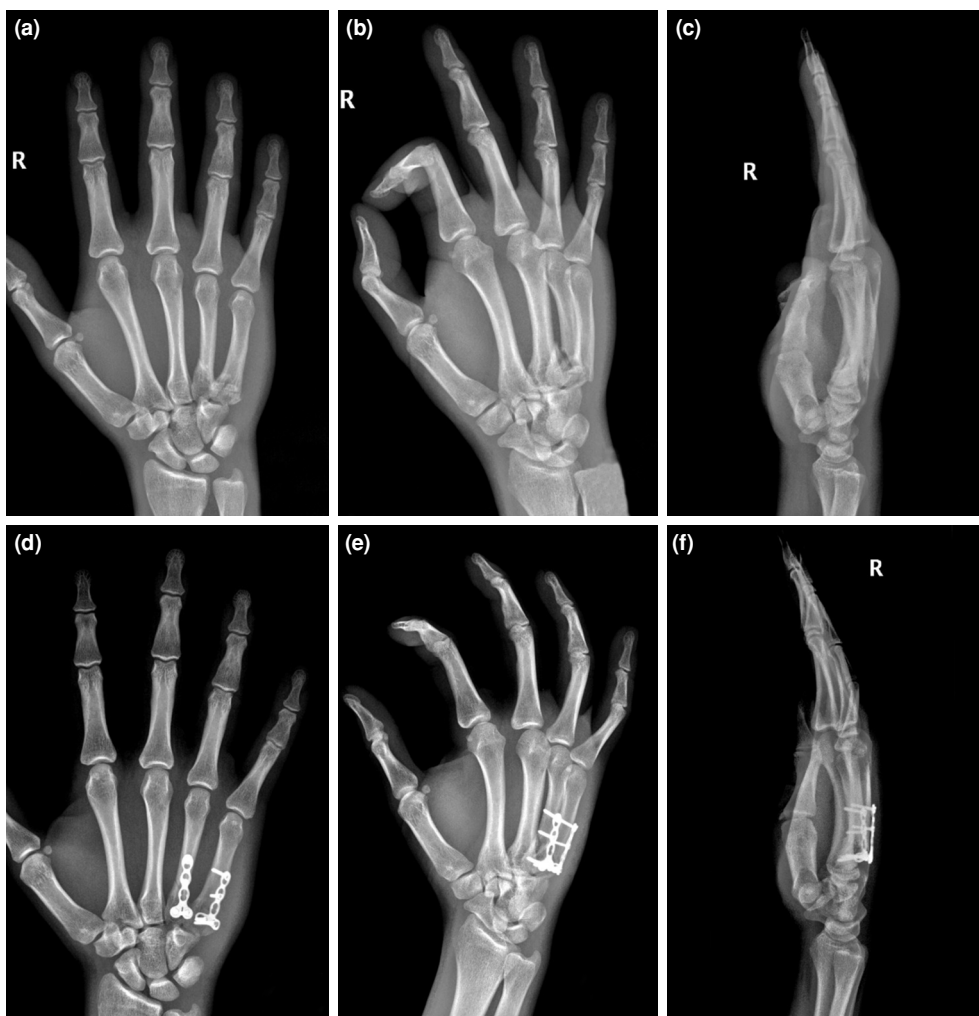

FIGURE 2. Pre- and postoperative imaging of a patient treated surgically; an example of plate fixation. (a-c) Preoperative AP, oblique, and lateral X-ray images. (d-f) Postoperative AP, oblique, and lateral X-ray images.

AP: Anteroposterior.



functional scores. In the dislocation group, unlike the isolated fracture group, there was a loss of anatomic congruence of bones at the ulnar CMC joints. In this group, the grip strength of the fractured side was significantly higher in the surgery group compared to the conservative group ($p=0.0237$).

The effect of time to treatment after the fracture on pain, functional score, grip strength, and recovery time was evaluated in the correlation analysis in the entire study group, in the surgical and conservative groups, and separately in the groups with and without dislocation. Table III summarizes the correlation analysis results. The time to treatment did not significantly affect the VAS, DASH scores, grip strength difference, and recovery time in general and in the isolated fracture group. However, when the

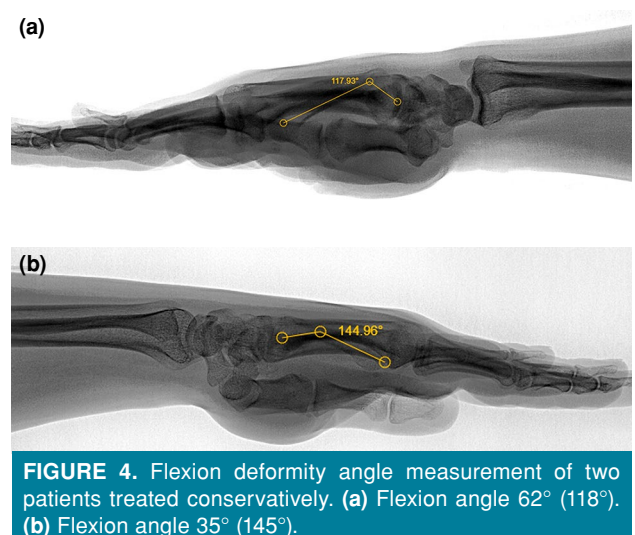


TABLE I
Post-treatment pain and functional scores, grip strength, return to work, and complication data of the patients

	Total (n=28)				Surgery (n=14)				Conservative (n=14)						
	n	%	Mean±SD	Min-Max	p1	n	%	Mean±SD	Min-Max	p1	n	%	Mean±SD	Min-Max	p2
VAS			1.6±1.9	0-6				1.6±1.7	0-5				1.6±2.3	0-6	0.6630
DASH			16.6±15.6	0-50				18.6±14.5	5-50				14.6±16.8	0-50	0.2770
JAMAR					0.0138					0.9237					0.008
Fractured side			86.9±17.4	44-120				90.9±19.4	44-120				82.9±14.9	55-105	0.2317
Healthy side			93.6±14.6	35-115				91.9±19.9	35-115				95.4±6.6	90-110	0.5715
Difference			6.8±12.1	-10-35				1.1±11.5	-10-25				12.5±9.9	5-35	0.0093
Return to work			2.0±0.87	1-4				2.3±0.69	1.5-5				1.8±0.97	1-4	0.0063
Complication	9	32.14				1	7.14				8	57.14			0.005

SD: Standard deviation; VAS: Visual Analog Scale; DASH: Disabilities of the Arm, Shoulder and Hand; p1: Fractured vs. healthy side; p2: Surgery vs. conservative group; P<0.05 is accepted as significant, and the significant ones are written in bold.

dislocation group was evaluated separately, the grip strength difference with the healthy side increased, as the treatment was delayed in the surgery group.

Except for three patients in the conservative group, PPD was 0, and the values of three patients were 2, 3, and 4 mm, respectively.

Minor complications developed in nine of all patients. Flexion deformity (maximum angle being 350 and 620) of the fifth metacarpal in four (Figure 4), shortness in the fifth metacarpal in one, unknown pain in three, mild rotational deformity in the fifth finger in one, and 2-mm step-off in the fifth CMC joint on X-ray in one were detected. While eight (57.1% in the group and 88.89% of all complications) minor complications are in the conservative group, only 1 (7.1% in the group and 11.1% of all complications) developed in the surgical group, which is statistically significant (p=0.005). Details of the patients treated surgically and conservatively are given in Tables IV and V, respectively.

DISCUSSION

In the present study, we compared the outcome measures and complications of cast and ORIF of ulnar CMC joint injuries in delayed presentation. The main finding of this study is that favorable results can be obtained with ORIF without arthrodesis in delayed presentations.

There are ongoing debates regarding the optimal treatment for ulnar CMC joint injuries, as conservative and operative approaches can achieve full functional grip. However, an immediate reduction is necessary to perform a proper function.^[13] Surgical decision-making may affect patients' return to work and hand function in delayed ulnar CMC fracture-dislocations. As the fifth CMC fracture-dislocations are inherently unstable, CR and plaster cast can be risky. The study of Qi et al.^[14] showed that malunion caused by insufficient reduction or loss of reduction resulted in weakness of the grip. Lyons et al.^[15] also reported that 19 of 50 patients (38%) had certain symptoms at a median follow-up of 4.3 years, regardless of the treatment modality (i.e., closed, percutaneous, or open).

In the literature, several operative and non-operative techniques have been described for ulnar CMC injuries. These techniques are CR, CR percutaneous pinning (CRPP), open reduction percutaneous pinning (ORPP), and ORIF with either bridging the CMC or metacarpal dorsal buttress of the base.^[4,16,17] The senior author frequently uses

TABLE II
Post-treatment pain and functional scores, grip strength, and return to work data

	Dislocation + (CAIN)				Dislocation – (AO)				
	Total (n=12)	Surgery (n=7)	Conservative (n=5)	p_2	Total (n=16)	Surgery (n=7)	Conservative (n=9)	p_3	p_4
	Mean±SD	Mean±SD	Mean±SD		Mean±SD	Mean±SD	Mean±SD		
VAS	1.9±2.0	1.9±2.3	2.0±1.7	0.5563	1.38±2.0	1.3±1.0	1.4±2.6	0.1961	0.3551
DASH	18.5±15.3	17.8±16.8	19.4±14.7	0.2455	15.3±16.1	19.5±13.2	11.9±18.2	0.1057	0.3496
JAMAR									
Fractured side	88.8±12.5	97.9±16.3	76.0±9.6	0.0237	85.4±17.9	83.9±20.8	86.7±16.4	0.7666	0.5031
Healthy side	95.8±9.7	99.3±11.7	91.0±2.2	0.1539	92.0±17.6	84.6±24.3	97.8±7.1	0.1412	0.9208
p_1	0.0908	1.0000	0.0269		0.0676	0.8641	0.0097		
Difference	7.1±13.2	1.4±13.1	15.0±9.4	0.0773	6.6±11.5	0.7±10.7	11.1±10.5	0.0719	0.9124
Return to work	2.1±1.0	2.3±0.9	1.9±1.2	0.1738	2.0±0.8	2.3±0.5	1.7±0.9	0.0150	0.9036

SD: Standard deviation; VAS: Visual Analog Scale; DASH: Disabilities of the Arm, Shoulder and Hand; p_1 : Fractured vs. healthy side; p_2 : Surgery vs. conservative group, in the dislocation group; p_3 : Surgery vs. conservative group, in the isolated fracture group; p_4 : Dislocation group vs. isolated fracture group; $p < 0.05$ is accepted as significant, and the significant ones are written in bold.

TABLE III
Correlation data for time to treatment after fracture

	Total			Dislocation + (CAIN)			Dislocation – (AO)		
	Total (n=28)	Surgery (n=14)	Conservative (n=14)	Total (n=12)	Surgery (n=7)	Conservative (n=5)	Total (n=16)	Surgery (n=7)	Conservative (n=9)
VAS	0.2095	0.3115	0.1742	-0.0109	0.4117	-0.8944	0.3314	0.5316	0.1550
DASH	0.1166	0.1285	0.1184	-0.1954	0.1123	-0.6669	0.3339	0.5385	0.1650
JAMAR difference	0.1580	0.5029	0.1017	0.1457	0.8524	-0.6156	0.1609	0.5049	0.1740
Return to life	0.1453	-0.1166	0.1191	0.3049	0.0561	0.2236	0.1162	-0.1641	0.0783

VAS: Visual Analog Scale; DASH: Disabilities of the Arm, Shoulder and Hand; Rho >0.6 is accepted as correlated, and the significant ones are written in bold.

TABLE IV
Details of patients treated with surgery

Patient no	Age/sex	Side	Fracture	Cain's/AO classification	Time till treatment (d)	Kirschner removal time (d)	Plate osteotomy	VAS DASH	Return (m)	Follow-up (m)	JAMAR OP NOP	Complication
1	28/M	Right	MC4-5	1A	31	5-4 140	1.5 +	5 32.5	4	6	90 115	5 th metacarp base, 2 mm displacement at joint
2	42/M	Right	MC5	1A	16	5-H 62	1.5 +	0 9	3	9	90 90	
3	41/M	Right	MC5	C1.3	13		1.5 -	1 18	2	13	83 92	
4	26/M	Right	MC4-5, hamate	2	20	4-H 45	1.5 +	1 7.5	1.5	10	85 90	
5	29/M	Right	MC5	C1	15		2.0 +	1 5	2	15	100 115	
6	24/M	Right	MC5	1A	15	5-4 64	1.5 +	5 50	2	18	120 110	
7	26/M	Right	MC4-5	C1.3	15		2.0 +	1 18	2	16	90 90	
8	38/M	Right	MC5	1A	18	5-4 49	1.5 +	0 9	1.5	18	120 110	
9	59/M	Right	MC5	C1	15		1.5 +	1 25	3	18	70 80	
10	44/M	Right	MC4-5, hamate	2	12	5-4, 5-H 35	2.0 -	0 7.5	2	25	100 90	
11	50/F	Right	MC5	C1	16		2.0 +	3 45	2	24	44 35	
12	31/M	Right	MC4-5	C1.3	8		2.0, 2.0 -	0 7.5	2	25	100 90	
13	20/M	Right	MC4-5	C1.3	11		1.5, 2.0 -	2 18	3	19	100 90	
14	24/M	Right	MC4-5	1B	46	5-4, 5-H 44	+	2 9	2	16	80 90	

VAS: Visual Analog Scale; DASH: Disabilities of the Arm, Shoulder and Hand; MC: Metacarp; CMC: Carpometacarpal.

TABLE V
Details of patients treated conservatively

Patient no	Age/sex	Side	Fracture	Cain's/AO classification	Time till treatment (d)	Cast duration (w)	VAS DASH	Return (m)	Follow-up (m)	JAMAR OP NOP	Complication
1	22/M	Right	MC5	C1	6	4	0 0	1.5	6	95 100	
2	22/M	Left	MC5	C1.3	7	4	0 0	1.5	6	95 100	
3	42/F	Left	MC4	C1	22	6	0 0	2	6	100 105	
4	44/M	Right	MC4-5	1B	31	6	1 12.5	4	12	80 90	5 th metacarp flexion
5	35/M	Right	MC5	1A	18	3	1 9	1.5	6	95 90	
6	20/M	Right	MC5	C1	14	8	0 7.5	4	6	90 95	
7	28/M	Right	MC5	1A	22	4	1 12.5	1	12	80 95	5 th CMC joint displacement
8	20/M	Right	MC5	C1	5	4	1 17.5	1.5	12	75 90	5 th metacarp flexion
9	21/M	Right	MC5	C1	25	4	6 50	1.5	12	55 90	5 th finger rotation, weak grip
10	41/M	Right	MC4-5	C1.3	15	3	6 32.5	1.5	12	70 90	4 th finger shortening, 5 th CMC joint pain
11	29/M	Right	MC4, hamate	3	8	4	5 45	1.5	12	70 90	4 th and 5 th CMC joint pain
12	40/M	Left	MC5	3	10	3	2 18	1.5	12	75 90	5 th CMC joint pain with grip
13	30/M	Left	MC5	C1.3	61	3	0 0	1	12	105 110	5 th metacarp flexion
14	26/M	Right	MC4-5	C1	5	4	0 0	1	6	95 100	5 th metacarp flexion

VAS: Visual Analog Scale; DASH: Disabilities of the Arm, Shoulder and Hand; MC: Metacarp; CMC: Carpometacarpal.

ORIF with the non-bridging dorsal buttress plate technique in his daily practice for these injuries. In this technique, when solid dorsal ligaments of the CMC joint are attenuated, the joint is fixed with an additional K-wire. However, it is still unclear whether performing such an operation in the late period has an advantage over plaster treatment, despite the technical difficulties.

In the current study, the recovery period of treatment with plaster was earlier than surgery. The patients who chose the cast recovered with an impending malunion and joint subluxation were the ones who preferred returning to work early. The patients who decided on surgery, ignoring the time spent with the healing bone, and risking effort for an anatomical fixation from the beginning were the ones who were willing to achieve favorable results in the long term. This study is critical, due to the effort and risks the patient and surgeon put into the treatment process. The patients who chose cast treatment returned to work more quickly. Still, a mild malunion at the fracture site and joint subluxation affected hand function, thereby resulting in a significant decrease in the hand grip strength. The weakness of the firm grip in the cast group is mainly due to the reduced range

of motion of the fifth metacarpal.^[18] Stapczynski^[19] suggested that the rotation of fragments at the base of metacarpals might be an additional factor. In addition, ORIF is required for delayed cases, if the CMC intra-articular fragments are large enough and CR is impossible.^[20] In these late-presenting injuries, dense fibrous scar tissue around the joint prevents reduction.^[21] Inadequate reduction of this joint can be a severe problem for manual workers at work.

In this study, the effect of treatment delay on the results was also examined. Recovery and return to work were significantly delayed in the subluxation/dislocation group. As a result, residual joint irregularities may reduce the grip strength and delay return to work, regardless of the treatment method. Therefore, the surgeon should ensure that the joint contours are fully congruent, irrespective of the time the patient is seen.

Major complications after surgery of ulnar CMC fracture-dislocations are complex pain, uncomfortable pinch, infection, posttraumatic arthrosis, ulnar nerve sensory lesion, and painful, sensitive scar formation.^[22] Although no serious complication was encountered in this study, minor complications

related to malunion were predominantly detected in the cast group. Thus, it should be noted that minor complications seen in our study group are critical details that most surgeons ignore, but may affect the patient's outcome.

In our study, only one patient in the surgery group had mild reduction loss (2 mm displacement), and nine patients in the conservative group recovered with malunion. Therefore, restoration of the articular surface should be the primary goal of treatment. If symptomatic arthritis develops, some authors perform a second arthrodesis surgery.^[23]

There is also no consensus regarding the definition of late presentation for CMC injuries in the literature. In the study of Bao et al.,^[1] acute fourth and fifth CMC fracture-dislocations were defined for ≤ 3 days after injury. Chaves and Dubert's^[24] study defined chronic lesions as those treated after > 2 weeks. Compared to previous studies, the vast majority of our patients had chronic injuries. According to the information obtained from outpatient records, one patient in the surgery group and five in the conservative group were in the subacute period. However, the bone callus was visible on X-rays, raising the suspicion that there was much more time passed from the trauma before applying to our clinic.

When the clinical results of the plate and K-wire fixation were compared in the fourth and fifth CMC fracture-dislocations in the study of Bao et al.,^[1] the clinical results of the K-wire could improve, particularly, work-related hand functions compared to the plate. In this study, AO bridge plate technique made a rigid fixation, resulting in stiffness. On the contrary, the functional results were as desired, since the K-wire provided relative stability. In our study, for the first time, stiffness was prevented by using hybrid (K-wire & non-bridging plate) fixation.^[25] This is why our work is valuable.

Nonetheless, this study has several limitations. The main limitation of this study is its single-center, retrospective design. Another limitation is that a regular physical therapy program was unable to be applied to every patient in the conservative treatment group. In addition, many patients were willing to return to work as soon as possible. The desire to return to work quickly was the reason for the refusal of surgery in these patients. Also, post-traumatic arthritis may develop in the long term, when osteotomy is performed for an intra-articular fracture. Still, we only reported the early results of an osteotomy.

The main strength of this study is the promising results of patients in whom a surgeon adhering to AO principles - never accepting intra-articular malunion - courageously performed an osteotomy for a healed bone (fourth and fifth metacarpal base) for the first time in the literature.

In conclusion, the non-bridging dorsal buttress plate technique with or without a K-wire is effective in patients with delayed ulnar CMC fracture-dislocations. Although surgery is associated with longer time to return to work, mid-term results obtained with anatomical reduction of the joint are satisfactory for manual workers.

Ethics Committee Approval: The study protocol was approved by the Ankara City Hospital Ethics Committee (date: 07.09.2022, no: 22-2863). The study was conducted in accordance with the principles of the Declaration of Helsinki.

Patient Consent for Publication: A written informed consent was obtained from each patient.

Data Sharing Statement: The data that support the findings of this study are available from the corresponding author upon reasonable request.

Author Contributions: Idea/concept, design, literature review, references and fundings: U.B.; Control/supervision: U.B., M.A.; Data collection and/or processing: N.Ü., M.D.S.; Analysis and/or interpretation: M.D.S.; Writing the article: U.B., M.D.S.; Critical review: M.A.; Materials: U.B., E.A.

Conflict of Interest: The authors declared no conflicts of interest with respect to the authorship and/or publication of this article.

Funding: The authors received no financial support for the research and/or authorship of this article.

REFERENCES

1. Bao B, Zhu H, Zheng X. Plate versus Kirschner wire fixation in treatment of fourth and fifth carpometacarpal fracture-dislocations: A retrospective cohort study. *Int J Surg* 2018;52:293-6. doi: 10.1016/j.ijssu.2018.01.052.
2. Storcken G, Bogie R, Jansen EJ. Acute ulnar carpometacarpal dislocations. Can it be treated conservatively? A review of four cases. *Hand (N Y)* 2011;6:420-3. doi: 10.1007/s11552-011-9347-3.
3. Yoshida R, Shah MA, Patterson RM, Buford WL Jr, Knighten J, Viegas SF. Anatomy and pathomechanics of ring and small finger carpometacarpal joint injuries. *J Hand Surg Am* 2003;28:1035-43. doi: 10.1016/s0363-5023(03)00373-3.
4. Fuller JB, Piscocoy AS, Clark DM, Markose K, Dunn JC. Surgical management of ulnar metacarpal base fracture-dislocations: A systematic review. *Hand (N Y)* 2022;17:405-11. doi: 10.1177/1558944720948241.
5. Pundkare GT, Patil AM. Carpometacarpal joint fracture dislocation of second to fifth finger. *Clin Orthop Surg* 2015;7:430-5. doi: 10.4055/cios.2015.7.4.430.
6. Yang Y, Schecker LR, Kumar KK. Arthroplasty for fifth carpometacarpal joint arthritis. *J Wrist Surg* 2015;4:110-4. doi: 10.1055/s-0035-1549291.

7. Jumeau H, Lechien P, Dupriez F. Conservative treatment of carpometacarpal dislocation of the three last fingers. *Case Rep Emerg Med* 2016;2016:4962021. doi: 10.1155/2016/4962021.
8. Hodgson PD, Shewring DJ. The 'metacarpal cascade lines'; use in the diagnosis of dislocations of the carpometacarpal joints. *J Hand Surg Eur Vol* 2007;32:277-81. doi: 10.1016/J.JHSB.2006.09.020.
9. Gillespy T 3rd, Stork JJ, Dell PC. Dorsal fracture of the hamate: Distinctive radiographic appearance. *AJR Am J Roentgenol* 1988;151:351-3. doi: 10.2214/ajr.151.2.351.
10. Chan YH. *Biostatistics 104: Correlational analysis*. Singapore Med J 2003;44:614-9.
11. Cain JE Jr, Shepler TR, Wilson MR. Hamatometacarpal fracture-dislocation: Classification and treatment. *J Hand Surg Am* 1987;12:762-7. doi: 10.1016/s0363-5023(87)80064-3.
12. Jupiter FB, DC R. *AO-Manual of Fracture Management - Hand and Wrist*. Verlag, New York: Georg Thieme; 2005.
13. de Beer JD, Maloon S, Anderson P, Jones G, Singer M. Multiple carpo-metacarpal dislocations. *J Hand Surg Br* 1989;14:105-8. doi: 10.1016/0266-7681(89)90028-4.
14. Qi Y, Liu C, Wu L, Yang L, Zhao L, Jiang C, et al. The measurement of the inclination angle of the hamate and analysis of the inclination angle for the rotation deformity of the little finger in the fixation of the carpometacarpal joint. *Orthop Surg* 2021;13:1596-601. doi: 10.1111/os.13028.
15. Lyons M, Fashandi A, Freilich AM. Malunions of the Hand and Wrist. In: Agarwal A, editor. *Malunions. Diagnosis, evaluation and management*. New York: Springer; 2021. p. 145-75.
16. Gehrmann SV, Kaufmann RA, Grassmann JP, Lögters T, Schädel-Höpfner M, Hakimi M, et al. Fracture-dislocations of the carpometacarpal joints of the ring and little finger. *J Hand Surg Eur Vol* 2015;40:84-7. doi: 10.1177/1753193414562706.
17. Tay SC, Leow MQH, Tan ES. Use of dorsal buttress plate fixation for ulnar carpometacarpal joint fracture dislocations for early mobilization: Outcomes of 11 cases. *Musculoskelet Surg* 2019;103:77-82. doi: 10.1007/s12306-018-0571-7.
18. Dommissie IG, Lloyd GJ. Injuries to the fifth carpometacarpal region. *Can J Surg* 1979;22:240-4.
19. Stapczynski JS. Fracture of the base of the little finger metacarpal: Importance of the "ball-catcher" radiographic view. *J Emerg Med* 1991;9:145-9. doi: 10.1016/0736-4679(91)90321-6.
20. Eichhorn-Sens J, Katzer A, Meenen NM, Rueger JM. Carpometacarpal dislocation injuries. *Handchir Mikrochir Plast Chir* 2001;33:189. German. doi: 10.1055/s-2001-15130.
21. Zhang C, Wang H, Liang C, Yu W, Li Y, Shang R, et al. The effect of timing on the treatment and outcome of combined fourth and fifth carpometacarpal fracture dislocations. *J Hand Surg Am* 2015;40:2169-75.e1. doi: 10.1016/j.jhssa.2015.07.017.
22. Hatipoğlu MY, Yapar A, Ergişi Y, Tokgöz MA, Yapar D, Öztürk AM. What is the clinical and functional effect of performing suspension arthroplasty with abductor pollicis longus tendon slip to carpometacarpal joint osteoarthritis of the thumb? *Jt Dis Relat Surg* 2022;33:149-55. doi: 10.52312/jdrs.2022.485.
23. Wang F, Zhang R, Liu S, Ruan H, Xu J, Kang Q. Severe spaghetti wrist injury: Should we expand the terminology from wrist to proximal forearm? *Jt Dis Relat Surg* 2022;33:273-84. doi: 10.52312/jdrs.2022.652.
24. Chaves C, Dubert T. Ulnar-sided carpometacarpal fractures and fractures-dislocations. A systematic review and publication guidelines. *Orthop Traumatol Surg Res* 2020;106:1637-43. doi: 10.1016/j.otsr.2020.03.039.
25. Atik OŞ. Which articles do the editors prefer to publish? *Jt Dis Relat Surg* 2022;33:1-2. doi: 10.52312/jdrs.2022.57903.