



# Are cross finger and thenar flaps effective in the treatment of distal finger amputations with the reposition-flap method?

Necmi Cam, MD<sup>ORCID</sup>, Muharrem Kanar, MD<sup>ORCID</sup>

Department of Orthopedics and Traumatology, Şişli Hamidiye Etfal Training and Research Hospital, Istanbul, Türkiye

Finger distal tip amputation due to upper extremity injuries is frequently encountered in the emergency setting. Methods such as wound care, replantation, flap or composite graft applications and stump closure are frequently used in treatment. The method to be chosen depends on the type of injury, the level of amputation, factors related to the patient, the surgeon, and the center where treatment is applied.<sup>[1]</sup>

The main goal of treatment should be to restore the length, appearance, sensation and function of the finger. Although protecting the nail bed and providing length can provide a good aesthetic appearance, it is also of utmost importance to provide the patient with a painless and functional finger.<sup>[2,3]</sup> Replantation is an important treatment option which can meet all these expectations.<sup>[3-10]</sup> Unfortunately, replantation cannot be applied to every patient for many reasons.<sup>[1,3]</sup>

Received: August 29, 2022

Accepted: October 11, 2022

Published online: October 27, 2022

**Correspondence:** Necmi Cam, MD, Şişli Hamidiye Etfal Eğitim ve Araştırma Hastanesi, Ortopedi ve Travmatoloji Kliniği, 34371 Şişli, İstanbul, Türkiye.

E-mail: drnecmicam@gmail.com

Doi: 10.52312/jdrs.2022.834

**Citation:** Cam N, Kanar M. Are cross finger and thenar flaps effective in the treatment of distal finger amputations with the reposition-flap method?. Jt Dis Relat Surg 2022;33(3):631-638.

©2022 All right reserved by the Turkish Joint Diseases Foundation

This is an open access article under the terms of the Creative Commons Attribution-NonCommercial License, which permits use, distribution and reproduction in any medium, provided the original work is properly cited and is not used for commercial purposes (<http://creativecommons.org/licenses/by-nc/4.0/>).

## ABSTRACT

**Objectives:** The aim of this study was to evaluate the effectiveness of using cross finger and thenar flaps in treatment of distal fingers amputations with reposition-flap method.

**Patients and methods:** Between September 2017 and January 2020, a total of 20 fingers of 19 patients (15 males, 4 females; mean age: 31.6±10.4 years; range, 19 to 52 years) who were treated with repositioning using a cross finger or thenar flap were retrospectively analyzed. Finger length, flap status, pain, cold intolerance, two-point discrimination, bone healing and appearance of the nail were recorded. Functional evaluation was performed using the Quick Disabilities of the Arm, Shoulder and Hand (Quick-DASH) score and range of motion.

**Results:** The mean follow-up was 19.5±5.2 months. A poor result was seen in one patient with the development of necrosis in the flap. With the exception of one finger with necrosis in the flap, no major complications were observed. Union was achieved in all other bones. The mean shortness was 3.7±1.9 mm. The mean Quick-DASH score was 4.5±5.0 and the mean two-point discrimination test was measured as 6.8±0.9.

**Conclusion:** In fingertip amputations repositioning with a cross finger or thenar flap can achieve a near-normal fingertip appearance with the advantages for the surgeon of a short learning curve and no requirement for microsurgery experience. If replantation cannot be applied in fingertip amputations, this method should be considered among the treatment options, particularly for patients with high aesthetic expectations.

**Keywords:** Amputation, fingertip, nail bed, reposition-flap.

In 1975, Mantero<sup>[11]</sup> first published a technique in which the amputate was used as a graft to provide finger length in distal tip amputations which were not suitable for replantation. In this technique, after the amputated part was first fixed in place, the necrotic soft tissues that developed during follow-up were debrided and covered with a cross finger flap in the second stage. This technique was modified by Foucher<sup>[12]</sup> in 1992 as a reposition-flap method. In

this method, the fingertip pulp soft tissue is removed initially, then the nail complex and bone are fixed to the stump with a Kirschner (K-wire) and covered with a homodigital neurovascular island flap.

The reposition-flap method is a treatment that can provide near normal anatomy and finger length in patients with distal tip amputations that cannot be replanted.<sup>[5]</sup> Various flaps have been used in the literature for reposition-flap method. Cross finger or thenar flaps are more easily applicable and do not require microsurgery experience.<sup>[13]</sup>

In the present study, we aimed to evaluate the effectiveness of using cross finger and thenar flaps in the treatment of distal fingers amputations with reposition-flap method.

**PATIENTS AND METHODS**

This single-center, retrospective study was conducted at Şişli Hamidiye Etfal Training and Research Hospital, Department of Orthopedics and Traumatology between September 2017 and January 2020. Patients admitted with repositioning using a cross finger or thenar flap were included. Repositioning and cross finger or thenar flap placement was applied to 20 fingers of 19 patients (15 males, 4 females; mean age: 31.6±10.4 years; range, 19 to 52 years) with distal tip amputation, for which replantation was not possible. Only patients who had unfavorable volar tissue loss for V-Y flap with bone loss and who were unwilling to lose the finger length aesthetically and had type III and IV fingertip amputation according to the Allen classification, and underwent reposition-flap procedure were included.<sup>[14]</sup>

Data including type of injury, affected finger and hand, the time of return to work, finger length, flap status, pain, cold intolerance, two-point discrimination, bone healing and appearance of the nail were evaluated. Functional assessment was performed using the Quick Disabilities of the Arm, Shoulder and Hand (Quick-DASH) score and range of motion (ROM). Finger length was evaluated radiologically by comparing with healthy side X-ray taken at the final follow-up visit. In addition to the

macroscopic evaluation of the nail appearance, the Numerical Rating Scale (NRS) was prepared for patients, where '0' indicates aesthetically exactly the same as the other nails and '10' indicates aesthetically unacceptable (Figure 1). The patients were asked to evaluate their satisfaction on the NRS, considering the aesthetic appearance of the nail.

**Surgical technique**

Depending on the patient's condition, the anesthesia method was decided by the anesthesiologist. The amputated part was first examined whether it was suitable for replantation or not. In patients who were not suitable for replantation, the surgical procedure was continued in accordance with the reposition-flap technique.

The soft tissues of the pulp in the amputate were excised so that the bone and nail bed complex remained in the amputated part. Except for the cortex

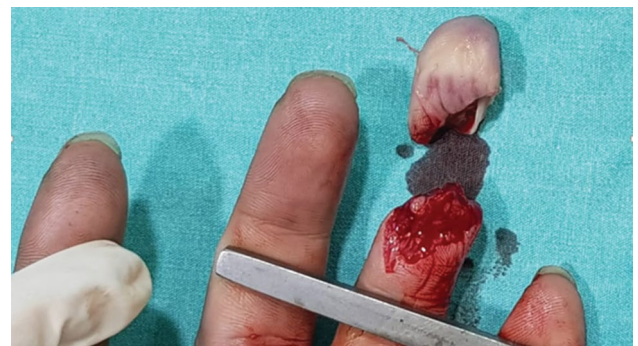

FIGURE 2. Allen type IV finger amputation.

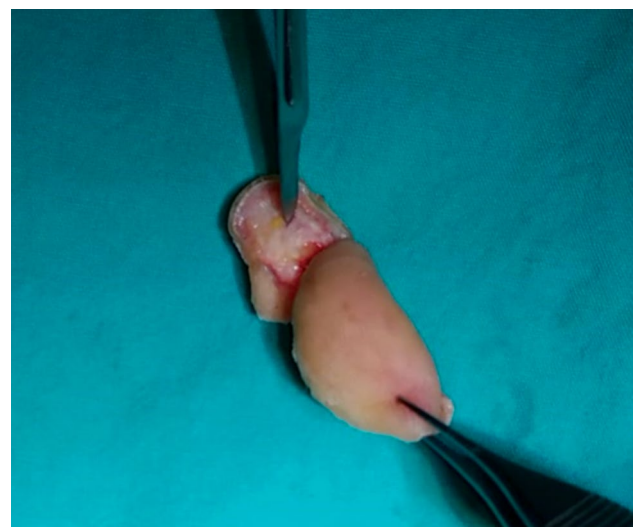
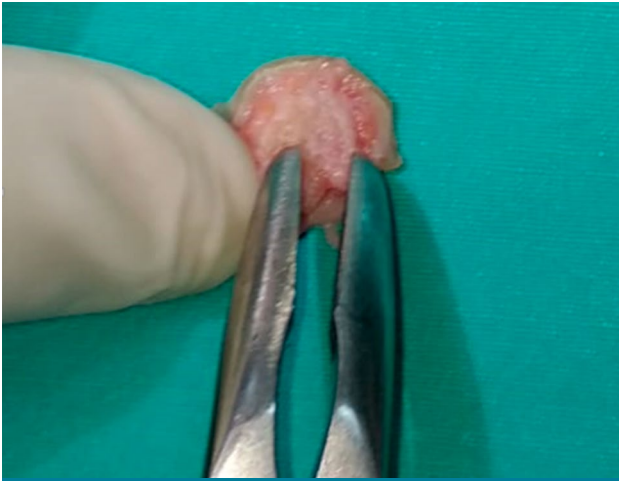

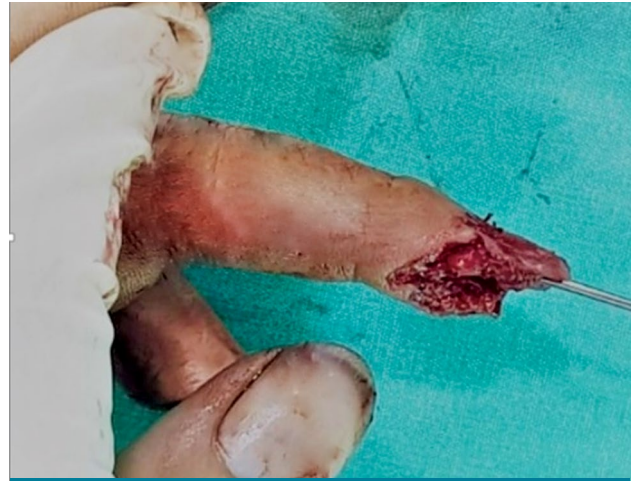FIGURE 3. Excision of volar soft tissue.

0	1	2	3	4	5	6	7	8	9	10
Aesthetically exactly the same as my other nails										Aesthetically unacceptable

FIGURE 1. Numerical Rating Scale.



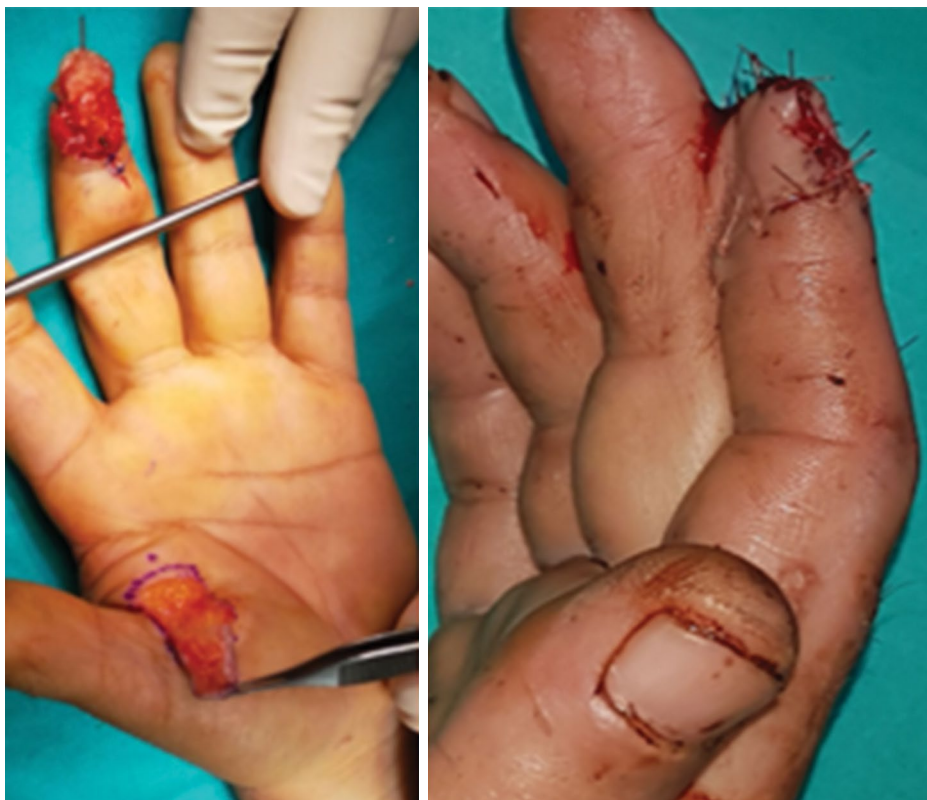**FIGURE 4.** Decortication of volar face of the amputated bone.



**FIGURE 5.** Fixation of the amputated bone and nail bed to the stump.

under the nail bed surface, all other bone surfaces were decorticated thinly with the aim of better adhesion of the flap to the bone (Figures 2-4). Bone ends in the amputate and stump were shortened nearly 1 to 2 mm in a controlled manner to clean the fracture surfaces. After the soft tissues were excised,

the amputated part consisting of the nail bed and bone, which would be used as a graft, was fixed to the stump with one or two K-wires or injector nail, without passing through the distal interphalangeal (DIP) joint (Figure 5). After nail bed repair, the coverage was provided with a cross finger or thenar



**FIGURE 6.** After fixation and nail bed repair, coverage with thenar or cross finger flap.

**TABLE I**  
Characteristics of the patients

	n	%
Sex		
Male	15	79
Female	4	21
Injury type		
Industrial machinery	9	47
Compression	8	42
Chain entanglement	2	11
Injured hand		
Right	12	63
Left	7	37
Injured finger		
Index	8	40
Middle	7	35
Ring	5	25
Allen classification		
Type III	12	60
Type IV	8	40

flaps, taking into account the patient's preferences (Figure 6). Skin graft taken from the volar face of the wrist was applied to the donor area. A dorsal splint was applied to all patients for protection. Division of the flaps were completed within 10 days at the earliest and within 12 days at the latest.

Protection after flap division was provided by an aluminum finger splint that allows proximal interphalangeal (PIP) joint movement. In the rehabilitation program, the splint was removed for 2 h, and passive and active DIP joint movements were applied. The patients were invited for weekly follow-up examinations for four weeks. The pins were removed after the signs of union were observed radiographically. The aluminum finger splint

continued to be used at night for two weeks after pin removal.

### Statistical analysis

Statistical analysis was performed using the GraphPad Prism version 5.0 software (GraphPad Software, San Diego, California USA). Descriptive data were presented in mean  $\pm$  standard deviation (SD), median (min-max) or number and frequency. Pairwise comparisons were performed using the Student t-test. The non-parametric Mann-Whitney U test was used, when the assumptions of the Student t-test were unable to be met. A *p* value of  $<0.05$  was considered statistically significant.

## RESULTS

The mean follow-up was  $19.5 \pm 5.2$  (range, 10 to 24) months. According to the Allen classification, eight of the amputated fingers were Allen type IV and 12 were Allen type III. Thenar flap was applied to five of 20 amputated fingers and cross finger flap to 15. The injuries of the patients were caused by industrial machinery in nine cases, compression with a heavy object in eight cases, and chain entanglement in two cases. The most injured finger was the second finger ( $n=8$ , 40%) (Table I).

There was no statistically significant difference in the ROM of the DIP joints between the operated fingers and the opposite fingers ( $p>0.05$ ). Contracture was not observed in any finger. Although there was a statistically significant difference in the two-point discrimination values in the opposite fingers, the values obtained in the operated fingers were quite satisfactory (Table II).

The mean shortness was  $3.7 \pm 1.9$  (range, 2 to 11) mm. The mean Quick-DASH score was  $4.37 \pm 5.1$  (range, 0 to 15.90). The mean NRS score was  $2.4 \pm 1.7$  (range, 0 to 7). The mean duration of return to work was  $9.8 \pm 1.5$  (range, 8 to 13) weeks.

**TABLE II**  
Comparison of ROM of DIP joint and two-point discrimination values of operated finger and non-operated same finger

	Mean $\pm$ SD	Min-Max	<i>p</i>
ROM DIP joint			
Operated finger	72.75 $\pm$ 7.3	55-85	0.084
Opposite finger	77 $\pm$ 5.7	70-90	$p>0.05$
Two-point discrimination values (mm)			$<0.0001$
Operated finger	6.8 $\pm$ 0.9	6-9	
Opposite finger	4.9 $\pm$ 0.7	4-6	

SD: Standard deviation; ROM: Range of motion; DIP: Distal interphalangeal joint.

**TABLE III**  
Ratios of complications

	n	%
Necrosis	1	5
Nail deformities	2	10
Bone resorption	1	5
Pain with percussion	4	20
Cold intolerance	3	15
Hyperpigmentation in the flap	1	5

In a patient with second and third fingers amputated on the same hand, necrosis was observed in the flap in the third finger while dividing the flap. The necrosis was followed and treated with local debridement, medical treatment and wound care. All other flaps were alive. Nail clawing developed in two patients and partial bone resorption was observed in one patient. Pain with percussion was detected in four patients. Cold intolerance was detected in three patients. In one patient, mild hyperpigmentation developed in the flap. Union was achieved in all bones, except for the patient who developed necrosis in the flap. No complications were observed in the donor area (Table III).

## DISCUSSION

Fingertip amputations are one of the most common injuries and there are many treatment options which fall between secondary healing and replantation. Which of the treatment methods should be selected depends on the type of injury, patient-related factors, cultural and geographical factors, surgical instruments, surgeon's preference, the center where the surgery will be applied, and economic reasons.<sup>[1]</sup> In cases where replantation cannot be applied, there is no consensus in the literature on the optimal treatment of these injuries. No prospective randomized trials providing treatment guidelines have been conducted so far.<sup>[1,15]</sup>

After a distal tip injury, the expectation from the treatment should be to provide a functional and painless finger according to the normal anatomy, length and appearance. The reposition-flap method is an option which can provide near normal anatomy and finger length in patients with distal tip amputations that cannot be replanted.<sup>[5]</sup> In our study, we used this method with flaps that have a short learning curve and do not require microsurgical experience.<sup>[16]</sup>

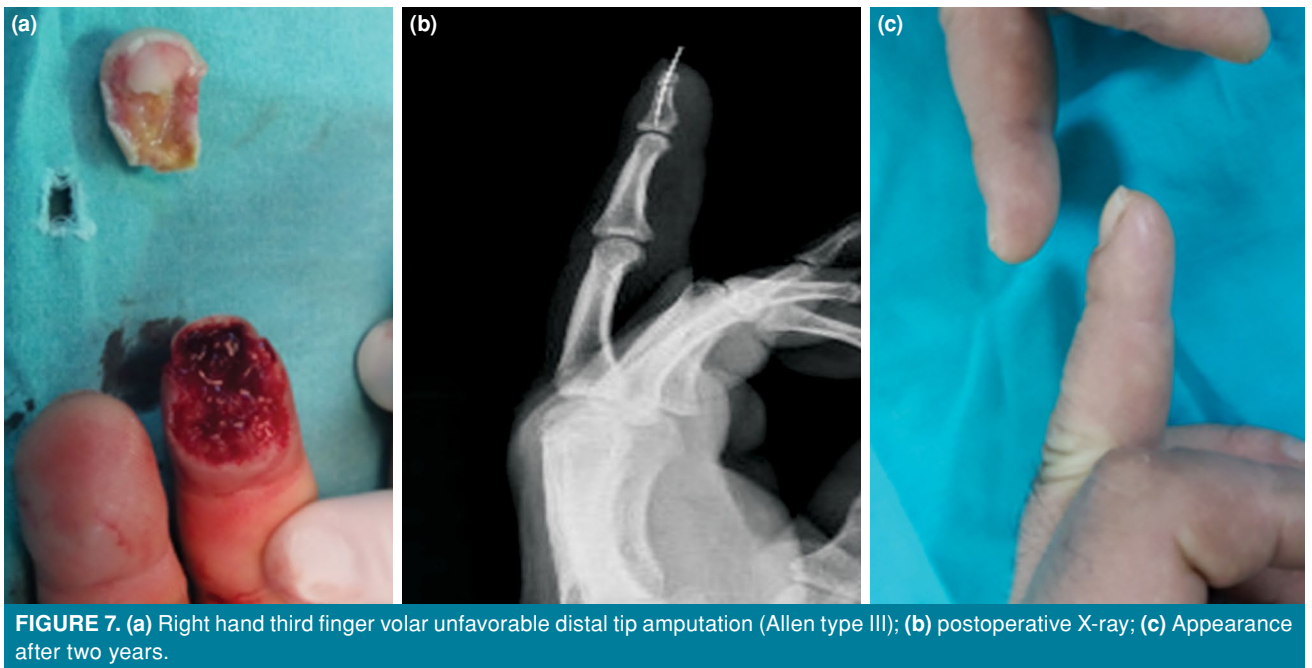
Foucher et al.<sup>[12]</sup> described the reposition-flap technique in non-replantable distal tip injuries and

applied immediate excision of the palmar tissues in the amputated part, then the distal bone and nail complex were held in place with a K-wire and cover was provided with a homodigital flap. In the results of that series, the Weber test was average 6 mm, moderate nail hook deformity was seen in 24% of the patients, and 24% reported cold intolerance. A technique was described by Mantero and Berlotti (in 1975. Unlike this technique, the amputate was first fixed to the stump without excision of the soft tissues, after tissues that develop necrosis were debrided and the defect was closed with a cross finger flap. Of 25 cases, failure occurred in four cases and poor results were achieved in five cases.<sup>[11]</sup>

Braga-Silva and Jaeger<sup>[5]</sup> published the results of 30 patients who underwent repositioning and flap. In that series, after the bone and nail complex was fixed to the bone following palmar segment excision of the amputate, as described by Foucher and Norris.<sup>[7]</sup> A homodigital unipedicled flap was used in 28 cases and a Tranquilli-Leali flap in two cases. Extension deficits developed in two patients, no shortness or clawing was detected in any of the patients and irregular contour developed in the nail of the two cases where the Tranquilli-Leali flap was applied. The two-point discrimination test was measured at an average of 8 mm, and cold intolerance developed in seven patients. Based on these results, it was concluded that the reposition-flap technique was a good surgical alternative. In our case series, 10% of the patients had nail deformity and 15% had cold intolerance.

Alagöz et al.<sup>[4]</sup> reported the 14-month follow-up results of 14 cases who underwent repositioning using a reverse homodigital neurovascular flap. According to the results, one patient developed local necrosis, one cold intolerance, and no movement disorder was detected. The mean two-point discrimination test result was 6.5 mm, bone healing was achieved in all patients, and all the nails were found to be aesthetically acceptable. The mean NRS score was 2.4±1.7 in our case series, indicating that our patients were aesthetically satisfied with the results.

Sbai et al.<sup>[17]</sup> published a series of 13 cases who were treated with reposition-flap mostly using a digital Chinese flap. According to the results, two patients had partial necrosis, one had bone resorption without clawing in the nail, three developed nail dystrophy, five had cold intolerance, and three had percussion pain. Recovery was completed with an average shortness of 4 mm. In our series, the mean shortness was measured as 3.7±1.9 mm and pain with percussion was detected in four patients.



**FIGURE 7.** (a) Right hand third finger volar unfavorable distal tip amputation (Allen type III); (b) postoperative X-ray; (c) Appearance after two years.

One patient in our case series, with the second and third finger distal tip amputation, developed necrosis in the third finger on which the thenar flap was applied. The reason for the necrosis in the flap was thought to be due to the effect of excessive pressure of the thenar flap. Due to the application of the cross finger flap to the second finger using the third finger as a donor and the thenar flap to the third finger at the same time.

Dubert et al.<sup>[6]</sup> published the results of six patients who underwent the reposition-flap technique. The blood supply and tissue cover were provided with a homodigital neurovascular anterograde island flap. An average shortening of 4.4 mm was found in patients who were not applied bone shortening during surgery and this was due to bone resorption. Clawing developed in all the nails, flexion contracture in the DIP joint in three patients, flexion contracture in the PIP joint in one patient, and cold intolerance in four patients. Based on these results, Dubert et al.<sup>[6]</sup> concluded that this technique had unsatisfactory results such as flexion contracture, shortness due to bone resorption, and claw-shaped fingernail.

In the current case series, partial bone resorption was observed in one patient. Bone resorption and related nail deformities are among the most important complications that adversely affect the results in reposition-flap applications. In our surgery technique, all bone surfaces except for the nail bed were

decorticated to accelerate the attachment of soft tissue to the bone, aim to prevent bone resorption and flap retraction. Controlled shortenings were applied to the bone fragments, when deemed necessary, to reduce flap tension. Joint contracture was not detected in any of the cases and there was no statistically significant difference in the ROM of the DIP joints between the operated fingers and the opposite fingers. The absence of joint stiffness and contractures, which are among the possible complications of cross finger or thenar flap applications, can be attributed to the shorter flap separation time and early rehabilitation.

In distal tip amputations, replantation may not be applied to every patient due to many factors. For this reason, many patients are treated with one of the treatment options other than replantation. Secondary healing is more preferred in selected cases and in small defects where the bone is not exposed. Time to return to work is usually less than one month for secondary healing. Allen type III and four amputations can be treated with secondary healing, but there is a strong likelihood that nail deformity would develop.<sup>[2,14,18,19]</sup> Upon the patient request or due to other conditions (e.g., severely contaminated injury, economic reasons), bone shortening and stump closure may be selected. Stump closure provides short operation time and early recovery, but results in more shortness.<sup>[20]</sup> Harris et al.<sup>[21]</sup> reported that, in their series of 584 patients, the rate of reoperation

due to complications after finger amputations with stump closure was 13.8%, and the most common complication was necrosis at the rate of 5.2%, nail deformity at 3.5%, and neuroma at 1.3%.

Many flap techniques that can be used after fingertip amputations have been described, depending on the type of injury and the surgeon's preference. Among these, one of the popular options is Atasoy's V-Y advancement flap technique. This technique is particularly applied in volar favored and transverse fingertip amputations. Atasoy et al.<sup>[22]</sup> reported that, along with excellent aesthetic results, normal ROM and sensory gain were achieved in 97% of their patients. The advantages of this technique are that it does not cause an additional donor side morbidity and it is a one-stage procedure.<sup>[22-24]</sup> In particular, after finger distal tip amputation with bone loss, if any flap technique is used without repositioning, only the existing shortness is preserved, as an advantage over shortening with closure. In our study, we consisted of patients with unfavorable volar amputation, in which there was extensive loss of volar tissue with bone loss. Therefore, in the repositioning flap technique that we applied, cross finger and thenar flaps were preferred using the amputated bone and nail bed as grafts to provide finger length.

The reposition-flap method, which was applied in this series using cross finger or thenar flaps, has the disadvantage of the need for a secondary surgical intervention for flap separation and it takes a long time to return to work. However, after the distal tip amputation, it is an effective method that can provide a near normal finger appearance and adequate functional results (Figure 7). This method does not require microsurgical experience, special surgical instruments and it has a short learning curve. As for any surgical method, there are possible complications. While evaluating the complications, it is important not to ignore the benefits of a surgical method applied to recover limb loss after injury.

The small number of patients, retrospective design with no randomization, and the lack of a control group are the main limitations to this study. Another limitation is the low number of females who may have more aesthetic expectations than many male patients.

In conclusion, in fingertip amputations, repositioning with a cross finger or thenar flaps is a feasible method that can achieve a near-normal fingertip appearance and good functional results with the advantages for the surgeon of a short learning curve and no requirement for microsurgery

experience. If replantation cannot be applied in fingertip amputations, this method should be considered among the treatment options.

**Ethics Committee Approval:** The study protocol was approved by the Şişli Hamidiye Etfal Clinical Research and Ethics Committee (date: 22.12.2020, no: 3078). The study was conducted in accordance with the principles of the Declaration of Helsinki.

**Patient Consent for Publication:** A written informed consent was obtained from each patient.

**Data Sharing Statement:** The data that support the findings of this study are available from the corresponding author upon reasonable request.

**Author Contributions:** Idea/consept, design, data collection and/processing, analysis and/or interpretation, references and fundings: N.C.; Control/supervision, literatur review, writing the article, critical, review, materials: M.K.

**Conflict of Interest:** The authors declared no conflicts of interest with respect to the authorship and/or publication of this article.

**Funding:** The authors received no financial support for the research and/or authorship of this article.

## REFERENCES

- Gürbüz K, Yontar Y. A four-year community hospital experience regarding procedures for the replantation and revascularization of fingers. *Jt Dis Relat Surg* 2021;32:383-90.
- Tang JB, Elliot D, Adani R, Saint-Cyr M, Stang F. Repair and reconstruction of thumb and finger tip injuries: A global view. *Clin Plast Surg* 2014;41:325-59.
- Venkatramani H, Sabapathy SR. Fingertip replantation: Technical considerations and outcome analysis of 24 consecutive fingertip replantations. *Indian J Plast Surg* 2011;44:237-45.
- Alagoz MS, Uysal CA, Kerem M, Sensoz O. Reverse homodigital artery flap coverage for bone and nailbed grafts in fingertip amputations. *Ann Plast Surg* 2006;56:279-83.
- Braga-Silva J, Jaeger M. Repositioning and flap placement in fingertip injuries. *Ann Plast Surg* 2001;47:60-3.
- Dubert T, Houimli S, Valenti P, Dinh A. Very distal finger amputations: Replantation or "reposition-flap" repair? *J Hand Surg Br* 1997;22:353-8.
- Foucher G, Norris RW. Distal and very distal digital replantations. *Br J Plast Surg* 1992;45:199-203.
- Ozcelik IB, Purisa H, Sezer I, Mersa B, Aydin A. Distal interfalangeal eklem ve distal falanks seviyesindeki replantasyon sonuçlari. *Acta Orthop Traumatol Turc* 2006;40:62-6.
- Uysal A, Kankaya Y, Ulusoy MG, Sungur N, Karalezli N, Kayran O, et al. An alternative technique for microsurgically unreplantable fingertip amputations. *Ann Plast Surg* 2006;57:545-51.
- Yamano Y. Replantation of the amputated distal part of the fingers. *J Hand Surg Am* 1985;10:211-8.
- Mantero R, Berlotti P. Le cross finger et reimplantation des extremités digitales. *Ann Chir* 1975;29:1019-23.

12. Foucher G, Braga Da Silva J, Boulas J. "Reposition-flap" technique in amputation of the finger tip. Apropos of a series of 21 cases. *Ann Chir Plast Esthet* 1992;37:438-42.
13. Ekinci Y, Gürbüz K. Is the cross-finger flap a good option at the extensor zone defect? *Jt Dis Relat Surg* 2020;31:267-72.
14. Allen MJ. Conservative management of finger tip injuries in adults. *Hand* 1980;12:257-65.
15. Bickel KD, Dosanjh A. Fingertip reconstruction. *J Hand Surg Am* 2008;33:1417-9.
16. Atik OŞ. Which articles do the editors prefer to publish? *Jt Dis Relat Surg* 2022;33:1-2.
17. Sbai MA, M'chirgui ME, Maalla R, Khorbi A. Place of the reposition flap in the treatment of distal amputations of the fingers. *Chin J Traumatol* 2017;20:198-201.
18. Neustein TM, Payne SH Jr, Seiler JG 3rd. Treatment of fingertip injuries. *JBJS Rev* 2020;8:e0182.
19. Sindhu K, DeFroda SF, Harris AP, Gil JA. Management of partial fingertip amputation in adults: Operative and non operative treatment. *Injury* 2017;48:2643-9.
20. Boudard J, Loisel F, El Rifai S, Feuvrier D, Obert L, Pluvy I. Fingertip amputations treated with occlusive dressings. *Hand Surg Rehabil* 2019;38:257-61.
21. Harris AP, Goodman AD, Gil JA, Sobel AD, Li NY, Raducha JE, et al. Incidence, timing, and risk factors for secondary revision after primary revision of traumatic digit amputations. *J Hand Surg Am* 2018;43:1040.e1-1040.e11.
22. Atasoy E, Ioakimidis E, Kasdan ML, Kutz JE, Kleinert HE. Reconstruction of the amputated finger tip with a triangular volar flap. A new surgical procedure. *J Bone Joint Surg [Am]* 1970;52:921-6.
23. Gürbüz K. The treatment of onychogryphosis of hand nails by total matricectomy and dorsal V-Y advancement flap. *Jt Dis Relat Surg* 2020;31:39-42.
24. Lim JX, Chung KC. VY advancement, thenar flap, and cross-finger flaps. *Hand Clin* 2020;36:19-32,