



Increase in range of motion after intra-articular injection of triamcinolone acetonide for the treatment of frozen shoulder is related to body mass index

Hyo-jin Lee, MD¹, Yang-soo Kim, MD¹, Bo-seoung Kim, MD¹

Department of Orthopedic Surgery, Seoul St. Mary's Hospital, College of Medicine, The Catholic University of Korea, Seoul, South Korea

Pathophysiological process of inflammation leading to fibrosis on the glenohumeral joint is known to be the main pathology of idiopathic frozen shoulder.^[1,2] Among various conservative treatments for frozen shoulder, intra-articular corticosteroid injection remains one of the verified methods commonly used in clinical practice. By reducing synovial inflammation, which leads to a decrease in pain perception, this promotes range of motion (ROM) recovery in frozen shoulder.^[3] Combining intra-articular injection with passive and active exercises accelerates recovery during the early stages of treatment for frozen shoulder.^[4]

However, despite the certified effect of intra-articular injection on frozen shoulder, patients tend to respond differently to the injection of triamcinolone acetonide. Some patients recover their ROM dramatically without much effort

ABSTRACT

Objectives: The aim of this study was to evaluate the clinical effect of glenohumeral injection with triamcinolone acetonide for frozen shoulder and to identify the factors related to extent of range of motion (ROM) recovery.

Patients and methods: Between July 2015 and May 2020, a total of 305 patients with primary frozen shoulder (147 males, 158 females; mean age: 55.8±4.3 years; range, 52 to 73 years) who underwent intra-articular glenohumeral injection of triamcinolone acetonide were retrospectively analyzed. The primary outcome measure was the range of changes in each aspect of ROM at six weeks after injection. The relationship between improvement and unresponsiveness to intra-articular injection for the treatment of frozen shoulder with various factors were evaluated. The analyzed factors were as follows: age, sex, body mass index (BMI), initial ROM before injection, symptom duration, hand dominance, smoking history, and the existence of underlying disease including diabetes mellitus, hypertension, coronary disease, thyroid disease, and hypercholesterolemia.

Results: There were significant improvements in all aspects of ROM at six weeks after injection. The forward flexion ($p=-0.346$, $p<0.001$) and external rotation ($p=-0.204$, $p=0.040$) showed a negative correlation with BMI. Multivariate analysis revealed that BMI was the sole factor related to recovery of forward flexion ($p=0.032$) and external rotation ($p=0.007$) at six weeks post-injection.

Conclusion: Intra-articular injection of triamcinolone acetonide is an effective method for improving ROM in patients with frozen shoulder. Increased BMI showed adverse effects on ROM recovery.

Keywords: Body mass index, frozen shoulder, triamcinolone acetonide.

Received: May 23, 2022

Accepted: July 21, 2022

Published online: October 06, 2022

Correspondence: Hyo-jin Lee, MD, Department of Orthopedic Surgery, Seoul St. Mary's Hospital, College of Medicine, The Catholic University of Korea, 137-701 Seoul, South Korea.

E-mail: hyojin1229@gmail.com

Doi: 10.52312/jdrs.2022.729

Citation: Lee HJ, Kim YS, Kim BS. Increase in range of motion after intra-articular injection of triamcinolone acetonide for the treatment of frozen shoulder is related to body mass index. *Jt Dis Relat Surg* 2022;33(3):496-504.

©2022 All right reserved by the Turkish Joint Diseases Foundation

This is an open access article under the terms of the Creative Commons Attribution-NonCommercial License, which permits use, distribution and reproduction in any medium, provided the original work is properly cited and is not used for commercial purposes (<http://creativecommons.org/licenses/by-nc/4.0/>).

with exercises or rehabilitation after injection, while some show little difference in ROM even after rehabilitation, with no definite evidence of complications. To date, several studies have revealed the risk factors or conditions associated with the etiology of primary frozen shoulder,

including diabetes mellitus, thyroid disease, cardiac or pulmonary problems.^[5] However, to the best of our knowledge, there is a limited number of data in the literature directly evaluating factors associated with post-injection status in frozen shoulders.

In the present study, we hypothesized that there would be an overall increase in ROM after injection and the presence of factors known to be closely related to the etiology of frozen shoulder might also affect the outcome of the intra-articular injection of triamcinolone acetonide. We, therefore, aimed to identify whether there was improvement in ROM within six weeks after triamcinolone acetonide injection and determine the factors related to the extent of ROM recovery after intra-articular injection of triamcinolone acetonide in patients with primary frozen shoulder.

PATIENTS AND METHODS

This single-center, retrospective study was conducted at Seoul St. Mary's Hospital, College of Medicine, The Catholic University of Korea, Department of Orthopedic Surgery between July 2015 and May 2020. A total of 534 patients under the diagnosis of unilateral frozen shoulder and received intra-articular injection of triamcinolone acetonide. We defined frozen shoulder based on previous studies as forward flexion less than 100° (maximal 150°; forward flexion is glenohumeral motion without scapulohumeral rhythm), external rotation under 45° (maximal 90°) in 0° of horizontal abduction (at side), or internal rotation at a level lower than the third lumbar spine (L3) (maximal T7 level).^[6,7]

For enrollment, we selected patients who underwent both plain radiograph and magnetic resonance imaging to detect reliable imaging indicators of frozen shoulder such as thickening of the capsule in the rotator interval, thickening of the coracohumeral ligament and obliteration of the fat triangle under the coracoid process.^[8] Also, detection of combined shoulder lesions that could cause restriction in shoulder motion or decreased ROM was made. Patients with concomitant shoulder lesions, including rotator cuff tear, labral tear, or arthritis, and those with a history of previous shoulder surgery or fracture were excluded.

To avoid including patients with inflammatory stage, of which the limitation is primarily caused by the subjective pain without actual pathological change of the intra-articular capsule itself, we confined the cohort to the patients with at least

three months of symptom duration before the injection. Also, patients with previous shoulder injection history were excluded. However, patients with other attempts including oral medications or physiotherapy prior to the injection were included.

To reduce the risk of complications following an increase in blood glucose level after the injection of triamcinolone acetonide, injections were allowed in diabetic patients with controlled diabetes (HbA1c <7) under the same medication for the past three months. Other underlying systemic conditions known to affect shoulder ROM or be associated with etiology of frozen shoulder such as thyroid diseases, hyperlipidemia, and hypertension were not considered as contraindications for intra-articular injection of triamcinolone acetonide. These conditions were considered to be underlying conditions, when the patient was under treatment or management after diagnostic confirmation. After excluding 229 patients, 305 patients with primary frozen shoulder (147 males, 158 females; mean age: 55.8±4.3 years; range, 52 to 73 years) were enrolled (Figure 1).

Injection technique

All injections were performed after sterilization of the injection site. A high-resolution transducer (12 MHz linear array) was utilized for needle guidance. A 21-gauge needle on syringe containing 40 mg of triamcinolone acetonide mixed with 1 mL of lidocaine (2%) was prepared. The procedure was performed with the patients sitting on a chair with a neutral position of the shoulder and elbow flexed 90°. The needle was inserted anteriorly at the level of coracoid process aiming medially to the humeral head. As soon as the needle made contact with the humeral head, the needle was tilted away from the head and advanced into the articular cavity. The location of the needle within the joint was confirmed by ultrasound.

Post-injection rehabilitation

The same standardized rehabilitation protocols were applied to every patient from the day after injection. The patients were required to follow the home-based instruction daily without additional clinic-based physiotherapy. Pendulum circumduction and self-stretching passive motion exercise in every plane were recommended for six weeks after injection. Pulley exercise was recommended for advanced forward flexion; isometric exercise was also recommended. No limit was imposed on use of the shoulder to the extent tolerated. Periodic supervision for compliance of rehabilitation was made every two weeks.

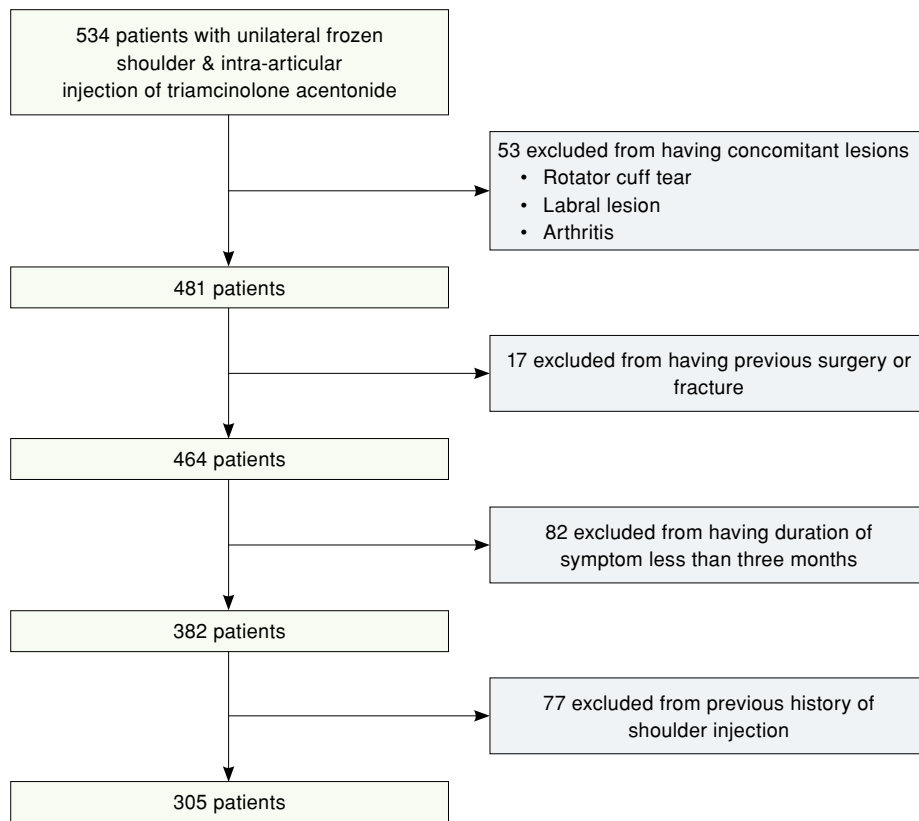


FIGURE 1. Study flowchart.

Assessment

The passive ROM was assessed before and after the injection. For the measurement, forward flexion and external rotation were evaluated with a goniometer, when the patient was in the supine position, excluding scapulohumeral motion. Internal rotation, which was measured in the sedentary position, was evaluated by the vertebral level reached by the tip of the thumb; internal rotation up to the level of the sacrum was designated as a zero point, and one point was added for each additional level upward. At six weeks post-injection, ROM was evaluated in the same manner.

We also attempted to identify the possible factors correlated with improvement or unresponsiveness to the intra-articular injection for the treatment of frozen shoulder. Therefore, the following factors were analyzed: age, sex, body mass index (BMI), initial ROM before injection, symptom duration, hand dominance, smoking history, and the existence of underlying disease including diabetes mellitus, hypertension, coronary disease, thyroid

disease and hypercholesterolemia. A condition was considered to be underlying, when the patient was under treatment or management after diagnostic confirmation, while the patient with a condition in controlled state without treatment did not qualify. All data were collected and evaluated by a clinical researcher who was blinded to the study assignments.

The primary outcome measure was the range of changes in each aspect of ROM at six weeks after injection.

Statistical analysis

Statistical analysis was performed using the SPSS version 18.0 software (SPSS Inc., Chicago, IL, USA). Descriptive data were expressed in mean \pm standard deviation (SD), median (min-max) or number and frequency, where applicable. A paired t test was used to compare the differences in ROM before and after injection for enrolled patients. Multivariate analysis using logistic regression analysis was performed to identify significant factors related to responsiveness and irresponsiveness of ROM to injection of triamcinolone acetonide. The amount

of ROM improvement at six weeks post-injection was determined using dependent variables and independent variables, including the other factors mentioned above. The Pearson correlation coefficient

(ρ) was performed to identify the relationship between ROM improvement and evaluated factors. A p value of <0.05 was considered statistically significant.

TABLE I				
Demographic and clinical data of patients				
	n	Mean \pm SD	Median	Range
Age (year)		55.8 \pm 4.3	57.55	52-73
Sex				
Male	147			
Female	158			
Mean follow-up, period (weeks)	7.54			
Mean BMI (kg/m ²)	23.2			
BMI >25 (overweight)	-105			
Smoking population	21			
Comorbidity				
Diabetes mellitus	52			
Hypertension	82			
Coronary disease	17			
Thyroid disease	28			
Hypercholesterolemia	84			
Initial range of motion				
Forward flexion		87.1 \pm 10.4		
External rotation		25.2 \pm 12.7		
Internal rotation*		2.4 \pm 0.8		

SD: Standard deviation; BMI: Body mass index; * Internal rotation measured base on the levels of vertebrae. The vertebral level was numbered serially as follows: 0 for any level below the sacral region and 1 additional point for each level higher than the sacrum.

TABLE II		
Multivariate analysis showing variables affecting recovery of forward flexion after the intra-articular injection of triamcinolone acetonide		
Characteristic	p	Beta
Age	0.288	0.034
Sex	0.327	0.626
Body mass index	0.032	-0.182
Initial range of motion		
Flexion	0.111	0.05
External rotation	0.346	0.022
Internal rotation	0.274	0.114
Duration of symptom before injection	0.390	0.132
Dominant hand	0.155	0.587
Smoking	0.547	-0.697
Diabetes mellitus	0.601	-0.366
Hypertension	0.921	-0.069
Coronary disease	0.613	-0.732
Thyroid disease	0.072	0.144
Hypercholesterolemia	0.787	0.180

RESULTS

Patient demographics are listed in Table I. There were significant improvements in all three aspects of ROM including forward flexion ($87.1^{\circ}\pm 10.4$ vs. $137.1^{\circ}\pm 21.7$, $p=0.024$), external ($25.2^{\circ}\pm 12.7$ vs. $55.4^{\circ}\pm 8.4$, $p=0.012$) and internal rotation (2.4 ± 0.8 vs. 10.8 ± 1.5 , $p=0.015$) at six weeks after injection.

Multivariate analysis revealed the sole and main factor related to recovery of forward flexion ($p=0.032$) and external rotation ($p=0.007$) at post-injection six weeks was BMI (Tables II and III). However, regression analysis did not show any significant differences between internal rotation with respect to the listed factors (Table IV).

TABLE III

Multivariate analysis showing variables affecting recovery of external rotation after the intra-articular injection of triamcinolone acetate

Characteristic	<i>p</i>	Beta
Age	0.310	-0.076
Sex	0.629	0.039
Body mass index	0.007	-0.203
Initial range of motion		
Flexion	0.174	-0.038
External rotation	0.548	0.545
Internal rotation	0.272	0.218
Duration of symptom before injection	0.807	0.019
Dominant hand	0.156	0.174
Smoking	0.367	0.068
Diabetes mellitus	0.286	-0.081
Hypertension	0.298	-0.080
Coronary disease	0.718	0.027
Thyroid disease	0.407	-0.602
Hypercholesterolemia	0.366	-0.068

TABLE IV

Multivariate analysis showing variables affecting recovery of internal rotation after the intra-articular injection of triamcinolone acetate

Characteristic	<i>p</i>	Beta
Age	0.542	-0.514
Sex	0.157	0.476
Body mass index	0.067	-0.549
Initial range of motion		
Flexion	0.144	0.565
External rotation	0.957	-0.141
Internal rotation	0.375	0.328
Duration of symptom before injection	0.242	-0.547
Dominant hand	0.214	0.175
Smoking	0.398	-0.241
Diabetes mellitus	0.617	0.226
Hypertension	0.581	0.384
Coronary disease	0.224	0.141
Thyroid disease	0.487	-0.219
Hypercholesterolemia	0.175	0.547

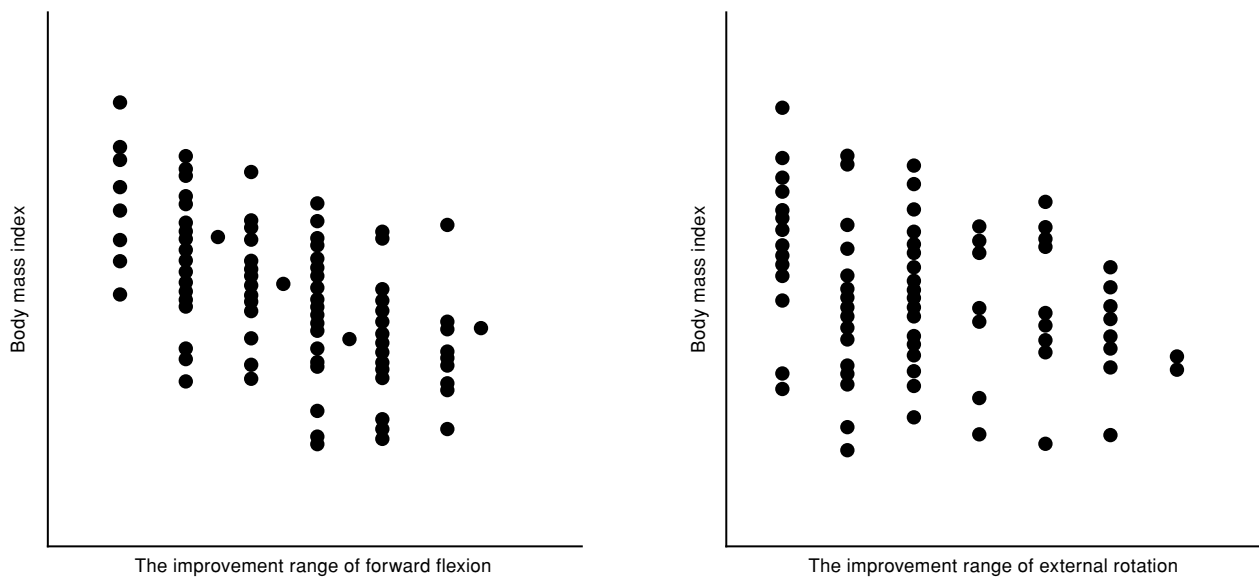


FIGURE 2. Scatter graph showing relationship between the improvement range of forward flexion, external rotation and body mass index.

The improvement range of forward flexion showed a negative correlation with BMI ($\rho=-0.346$, $p<0.001$). In case of external rotation, a negative correlation was observed with BMI ($\rho=-0.204$, $p=0.040$). However, internal rotation did not show any correlation with the analyzed factors (Figure 2).

The existence of diabetes mellitus or thyroid diseases, which were known to be related to the etiology of frozen shoulder, did not actually affect the recovery of ROM after injection. No patient reported symptoms or signs suggestive of acute infection or complication after injection.

DISCUSSION

This study revealed a significant improvement in ROM within six weeks after the intra-articular injection of triamcinolone acetonide in patients with frozen shoulder. In addition, the BMI affected the result of intra-articular injection of corticosteroid and was the sole factor that actually affected the recovery of both forward flexion and external rotation after injection. Increased BMI showed an inverse relationship on ROM recovery after injection, indicating that higher BMI values typically were associated with a lower range of recovery.

Obesity is a condition that is commonly involved with various systemic diseases and, due to a high incidence of obesity, it is not unexpected that there would be more obese patients with frozen shoulder

occurring in the future. Unlike diabetes, there are not many studies showing that obesity also plays a role in the pathogenesis of frozen shoulder. According to the cohort study by Kingston et al.,^[9] more than 50% of the enrolled patients were classified as either overweight or obese among the analyzed 2,190 patients who were diagnosed as adhesive capsulitis. A prospective comparison study by Lin et al.^[10] revealed that normal weight patients ($\text{BMI} < 25 \text{ kg/m}^2$) showed better Constant scores after corticosteroid injection for adhesive capsulitis compared to overweight patients. These results are consistent with our study suggesting that being overweight affected the result of the injection. The result of this study has clinical implications due to the fact that average BMI continues to increase worldwide and morbid obesity increases the risk of complications in many aspects. Specifically, obesity is also related to worse outcomes and higher risk of a revision surgery via shoulder arthroplasty.^[11,12] Understanding the effect of BMI on corticosteroid injection can help guide discussions about expectations with patients regarding the recovery of frozen shoulder. Our results clearly suggest that increased BMI is disadvantageous for the recovery from frozen shoulder and also providing this information to the patients may lead to voluntary weight control to maximize the benefits of corticosteroid injections.

Some possible explanations can be suggested why BMI is associated with outcomes of corticosteroid injection in frozen shoulders. First, increased BMI is associated not only with increased chronic musculoskeletal pain, but also with increased chronic pain in general.^[13-15] Persistent pain among patients with obesity may have reduced the effect of the injection and subsequent rehabilitation. This may be possible, as obesity, which is associated with decreased physical activity and having a larger and heavier arm, might have led to poor compliance of post-injection rehabilitation. Second, as shown in various joint problems, a more intense inflammatory reaction is known to happen in obese populations.^[16-18] Although the shoulder joint is not a weight-bearing joint, aggravated inflammation within the joint may hamper the injection result on a frozen shoulder.

Among many factors that are associated with etiology and prognosis of frozen shoulder, diabetes mellitus is probably one of the most frequently mentioned factors among various conditions or diseases. As corticosteroid therapy can lead to an increase in blood glucose levels and diabetic patients are vulnerable to complications following an increase in glucose levels, physicians tend to limit corticosteroid usage. Still, a corticosteroid injection is not considered as an absolute contraindication among diabetic patients, and is used in diabetic patients due to the fact that the injection is still effective for decreasing pain perception and accelerating functional recovery in the early post-injection period.^[3] Contrary to the expectation that the result of injection would be inferior among diabetic patients, diabetes itself did not actually affect the results and there were no cases with injection-related complications. We conclude that triamcinolone acetonide is a safe injection modality among diabetic patients with frozen shoulder under this condition, which is a well-controlled blood glucose level. Further, as long as diabetes is under control, the existence of the disease itself did not actually affect the efficacy of injection. According to Kim et al.,^[19] the different doses of triamcinolone acetonide did not actually show long-term differences for the treatment of frozen shoulder, except for the short-term glucose level increase with higher dose among diabetic patients.

Numerous studies have reported a relationship between abnormalities in serum lipid profiles and the incidence of frozen shoulder. The level of serum cholesterol or triglyceride was higher among patients with adhesive capsulitis and

hypercholesterolemia showed a prevalence of 17% among frozen shoulders.^[20,21] Sung et al.^[22] reported that hypercholesterolemia and inflammatory lipoproteinemia had a significant association with primary adhesive capsulitis. The authors suggested that higher levels of inflammatory lipoproteins in shoulder stiffness could induce inflammatory changes involved in adhesive capsulitis. However, existence of hypercholesterolemia itself did not significantly affect the ROM recovery after injection in this study. Similar to the included diabetic patients, hyperlipidemic patients were aware of the existing condition and under the medication in this particular study. Regarding the results shown with diabetic mellitus and hyperlipidemia, which are known to be associated with etiology of frozen shoulder, we conclude that triamcinolone acetonide injection is available and effective for the treatment of frozen shoulder, as long as these conditions are under control.

The limitations in internal rotation also showed an improvement after injection; however, unlike forward flexion or external rotation, its recovery was not affected by any evaluated factors. Indeed, different from the other motions, the deficit of internal rotation is not only caused by posterior capsule, which exists within the joint space, but also by adaptation from tightness of posterior musculotendinous tissue, including infraspinatus and teres minor.^[23-26] In the current study, intra-articular injection of triamcinolone acetonide is effective for improving ROM in patients with frozen shoulder. Increased BMI showed adverse effects on ROM recovery.^[27]

There have been many controversies regarding the contribution of posterior capsule pathology on internal rotation deficit leading to necessity of extended surgical release of the posterior capsule.^[7,28,29] Considering the dominating extra-articular factors, it can be explained that recovery of internal rotation could be less dependent on the effect of intra-articular injection when compared to the result of forward flexion and external rotation, and thus was not affected by the evaluation method.

Nonetheless, this study has some limitations. First, we were not able to account for all of the factors that can affect the recovery from frozen shoulder. For instance, although every patient was instructed to undergo the same routine exercise during post-injection recovery with periodic assessment of compliance, the individual compliance for rehabilitation cannot be identical. As the post-injection rehabilitation was completely based on

home exercise program with periodic supervision, careful monitoring may not be sufficient to ensure adherence. Also, even though we limited the cohort with no history of previous injection, we were not able to confirm all the specific treatments including physical therapy or self-motivated exercises prior to the injection. Second, the patient cohort was not large, which may have resulted in some contributing factors being overlooked. A larger sample size may have decreased the chance of type II error. Third, the change in ROM was used as the sole barometer in this evaluation. This study would provide more information, if additional clinical assessments, such as pain score, Constant score or American Shoulder and Elbow Surgeons (ASES) score, were utilized. Finally, this study only showed correlations and cannot explain a cause-effect relationship between various factors and the recovery.

In conclusion, our study results indicate that intra-articular injection of triamcinolone acetonide is an effective method for improving ROM in patients with frozen shoulder and the increased BMI values have adverse effects on ROM recovery.

Ethics Committee Approval: The study protocol was approved by the IRB of Seoul St. Mary's Hospital, the Catholic University of Korea Ethics Committee (KC17OESI0118). The study was conducted in accordance with the principles of the Declaration of Helsinki.

Patient Consent for Publication: Informed consent: not required (retrospective study).

Data Sharing Statement: The data that support the findings of this study are available from the corresponding author upon reasonable request.

Author Contributions: Analyzed and interpreted the data: H.J.L., Y.S.K.; Contributed to the acquisition of data: B.S.K.; Contributed to drafting the work and revising it critically for important intellectual content: Y.S.K., H.J.L.; Contributed to the final approval of the version to be published: H.J.L.; All authors agreed to be accountable for all aspects of the work to ensure that questions related to the accuracy or integrity of any part of the work are appropriately investigated and resolved.

Conflict of Interest: The authors declared no conflicts of interest with respect to the authorship and/or publication of this article.

Funding: The authors received no financial support for the research and/or authorship of this article.

REFERENCES

- Kim DH, Lee KH, Lho YM, Ha E, Hwang I, Song KS, et al. Characterization of a frozen shoulder model using immobilization in rats. *J Orthop Surg Res* 2016;11:160.
- Hand GC, Athanasou NA, Matthews T, Carr AJ. The pathology of frozen shoulder. *J Bone Joint Surg [Br]* 2007;89:928-32.
- Roh YH, Yi SR, Noh JH, Lee SY, Oh JH, Gong HS, et al. Intra-articular corticosteroid injection in diabetic patients with adhesive capsulitis: A randomized controlled trial. *Knee Surg Sports Traumatol Arthrosc* 2012;20:1947-52.
- Carette S, Moffet H, Tardif J, Bessette L, Morin F, Frémont P, et al. Intraarticular corticosteroids, supervised physiotherapy, or a combination of the two in the treatment of adhesive capsulitis of the shoulder: A placebo-controlled trial. *Arthritis Rheum* 2003;48:829-38.
- Manske RC, Prohaska D. Diagnosis and management of adhesive capsulitis. *Curr Rev Musculoskelet Med* 2008;1:180-9.
- Kim YS, Lee HJ, Park I, Im JH, Park KS, Lee SB. Are delayed operations effective for patients with rotator cuff tears and concomitant stiffness? An analysis of immediate versus delayed surgery on outcomes. *Arthroscopy* 2015;31:197-204.
- Kim YS, Lee HJ, Park IJ. Clinical outcomes do not support arthroscopic posterior capsular release in addition to anterior release for shoulder stiffness: A randomized controlled study. *Am J Sports Med* 2014;42:1143-9.
- Mengiardi B, Pfirrmann CW, Gerber C, Hodler J, Zanetti M. Frozen shoulder: MR arthrographic findings. *Radiology* 2004;233:486-92.
- Kingston K, Curry EJ, Galvin JW, Li X. Shoulder adhesive capsulitis: Epidemiology and predictors of surgery. *J Shoulder Elbow Surg* 2018;27:1437-43.
- Lin HH, Huang TF, Ma HL, Liu CL. Body mass index and active range of motion exercise treatment after intra-articular injection in adhesive capsulitis. *J Chin Med Assoc* 2013;76:225-8.
- Singh JA, Sperling JW, Cofield RH. Risk factors for revision surgery after humeral head replacement: 1,431 shoulders over 3 decades. *J Shoulder Elbow Surg* 2012;21:1039-44.
- Wagner ER, Houdek MT, Schleck C, Harmsen WS, Sanchez-Sotelo J, Cofield R, et al. Increasing body mass index is associated with worse outcomes after shoulder arthroplasty. *J Bone Joint Surg [Am]* 2017;99:929-37.
- Vincent HK, Adams MC, Vincent KR, Hurley RW. Musculoskeletal pain, fear avoidance behaviors, and functional decline in obesity: Potential interventions to manage pain and maintain function. *Reg Anesth Pain Med* 2013;38:481-91.
- Yoo JJ, Cho NH, Lim SH, Kim HA. Relationships between body mass index, fat mass, muscle mass, and musculoskeletal pain in community residents. *Arthritis Rheumatol* 2014;66:3511-20.
- Heim N, Snijder MB, Deeg DJ, Seidell JC, Visser M. Obesity in older adults is associated with an increased prevalence and incidence of pain. *Obesity (Silver Spring)* 2008;16:2510-7.
- Love TJ, Zhu Y, Zhang Y, Wall-Burns L, Ogdie A, Gelfand JM, et al. Obesity and the risk of psoriatic arthritis: A population-based study. *Ann Rheum Dis* 2012;71:1273-7.
- Bakirci S, Dabague J, Eder L, McGonagle D, Aydin SZ. The role of obesity on inflammation and damage in spondyloarthritis: A systematic literature review on body mass index and imaging. *Clin Exp Rheumatol* 2020;38:144-8.
- Urban H, Little CB. The role of fat and inflammation in the pathogenesis and management of osteoarthritis. *Rheumatology (Oxford)* 2018;57(suppl_4):iv10-iv21.

19. Kim YS, Lee HJ, Lee DH, Choi KY. Comparison of high- and low-dose intra-articular triamcinolone acetonide injection for treatment of primary shoulder stiffness: A prospective randomized trial. *J Shoulder Elbow Surg* 2017;26:209-15.
20. Bunker TD, Esler CN. Frozen shoulder and lipids. *J Bone Joint Surg [Br]* 1995;77:684-6.
21. Hand C, Clipsham K, Rees JL, Carr AJ. Long-term outcome of frozen shoulder. *J Shoulder Elbow Surg* 2008;17:231-6.
22. Sung CM, Jung TS, Park HB. Are serum lipids involved in primary frozen shoulder? A case-control study. *J Bone Joint Surg [Am]* 2014;96:1828-33.
23. Bailey LB, Shanley E, Hawkins R, Beattie PF, Fritz S, Kwartowitz D, et al. Mechanisms of shoulder range of motion deficits in asymptomatic baseball players. *Am J Sports Med* 2015;43:2783-93.
24. Poser A, Casonato O. Posterior glenohumeral stiffness: Capsular or muscular problem? A case report. *Man Ther* 2008;13:165-70.
25. Tyler TF, Nicholas SJ, Roy T, Gleim GW. Quantification of posterior capsule tightness and motion loss in patients with shoulder impingement. *Am J Sports Med* 2000;28:668-73.
26. Yamauchi T, Hasegawa S, Nakamura M, Nishishita S, Yanase K, Fujita K, et al. Effects of two stretching methods on shoulder range of motion and muscle stiffness in baseball players with posterior shoulder tightness: A randomized controlled trial. *J Shoulder Elbow Surg* 2016;25:1395-403.
27. Atik OŞ. Which articles do the editors prefer to publish? *Jt Dis Relat Surg* 2022;33:1-2.
28. Chen J, Chen S, Li Y, Hua Y, Li H. Is the extended release of the inferior glenohumeral ligament necessary for frozen shoulder? *Arthroscopy* 2010;26:529-35.
29. Nicholson GP. Arthroscopic capsular release for stiff shoulders: Effect of etiology on outcomes. *Arthroscopy* 2003;19:40-9.