



# Novel use of close-wedge osteotomy and monorail external fixator in the treatment of chronic Monteggia fracture

Rui Zhang, MD\*<sup>id</sup>, Feng Xue, MD\*<sup>id</sup>, Shenghe Liu, MD<sup>id</sup>, Hongjiang Ruan, MD<sup>id</sup>,  
Jia Xu, MD<sup>id</sup>, Qinglin Kang, MD<sup>id</sup>

Department Of Orthopedics, Shanghai Jiao Tong University Affiliated Sixth People's Hospital, Shanghai, China

Monteggia fracture refers to fracture of the proximal ulna and simultaneous dislocation of the ipsilateral radiocapitellar joint.<sup>[1-6]</sup> This rare lesion can be seen in both adult and children. However, pediatric patients are more likely to be missed due to their non-compliance during physical examination, atypical radiographic signs and careless intraoperative exploration of the dislocated radial head.<sup>[7]</sup> A Monteggia fracture then becomes chronic, if the lesion is not managed properly four weeks after injured, leading to cubitus valgus, pain, nerve palsy and loss of upper limb range of motion (ROM).<sup>[1,2,4,6,8,9]</sup>

Chronic Monteggia fracture usually requires surgical intervention to restore the alignment of

Received: March 31, 2022

Accepted: April 27, 2022

Published online: July 06, 2022

**Correspondence:** Qinglin Kang, MD. Department of Orthopedics, Shanghai Jiao Tong University Affiliated Sixth People's Hospital, 200233 Shanghai, China.

E-mail: orthokang@163.com

**Correspondence:** Jia Xu, MD. Department of Orthopedics, Shanghai Jiao Tong University Affiliated Sixth People's Hospital, 200233 Shanghai, China.

E-mail: xujia0117@126.com

Doi: 10.52312/jdrs.2022.662

\* Co-First Author

**Citation:** Zhang R, Xue F, Liu S, Ruan H, Xu J, Kang Q. Novel use of close-wedge osteotomy and monorail external fixator in the treatment of chronic Monteggia fracture. Jt Dis Relat Surg 2022;33(2):285-293.

©2022 All right reserved by the Turkish Joint Diseases Foundation

This is an open access article under the terms of the Creative Commons Attribution-NonCommercial License, which permits use, distribution and reproduction in any medium, provided the original work is properly cited and is not used for commercial purposes (<http://creativecommons.org/licenses/by-nc/4.0/>).

## ABSTRACT

**Objectives:** This study aims to evaluate the efficacy of close-wedge osteotomy and monorail external fixator in the treatment of chronic Monteggia fracture.

**Patients and methods:** Between January 2014 and December 2021, data of a total of 22 patients (14 males, 8 females; mean age: 15.6±5.1 years; range, 6 to 25 years) who suffered from chronic Monteggia fractures were retrospectively reviewed. All the patients were treated for acute angulation of the ulna after osteotomy and gradual angulation for radial head reduction. Range of motion of the elbow and forearm, the angle between the longitudinal axis of proximal radius and the hypothesized Støren's line (RSA), Visual Analog Scale (VAS), and Mayo Elbow Performance Score (MEPS), as well as Disabilities of Arm, Shoulder and Hand (DASH) score were recorded preoperatively and at the final follow-up.

**Results:** Objective parameters were all significantly improved in the aspects of range of motions of the elbow and forearm, and RSA (21.4±4.5° preoperatively and 2.0±1.4° at the final follow-up, t=18.20, p<0.05). The level of pain due to the chronic injury was eliminated, as the mean VAS was significantly lower at the final follow-up compared to preoperative scoring (2.8±2.0 preoperatively and 0.5±0.9 at the final follow-up, t=4.86, p<0.05). The function of the elbow and upper limb was restored, which was indicated by improved MEPS (73.2±12.5 preoperatively and 96.6±6.4 at the final follow-up, t=7.70, p<0.05) and DASH (28.3±6.0 preoperatively and 4.1±2.0 at the final follow-up, t=19.35, p<0.05). No complication was observed.

**Conclusion:** Close-wedge osteotomy and gradual lengthening with monorail external fixator in the treatment of chronic Monteggia fracture showed great efficacy. We also provided a specified osteotomy site aiming at PRUJ reconstruction.

**Keywords:** Chronic Monteggia fracture, close wedge, gradual lengthening, monorail external fixator, radial head, ulnar osteotomy.

the injured limb and the function of the elbow and forearm, which includes osteotomy of the ulna, reduction of the radial head, and repair of the annular ligament and trans-capitellar fixation in some cases.<sup>[1,2,10]</sup> While one-stage management through acute

elongation and angulation of the ulna and reduction of the radial head has been reported to achieve immediate reconstruction, several complications due to the distraction tension, including delayed union, compartment syndrome and re-dislocation of the radial head, sometimes occur.<sup>[8,11-15]</sup> On the other hand, gradual lengthening with external fixation may be an alternative to provide safe and effective correction of the composite deformities.<sup>[6,8,15-21]</sup>

In this study, we aimed to evaluate the efficacy of the novel use of close-wedge osteotomy and gradual lengthening with Ilizarov monorail external fixator in the treatment of chronic Monteggia fracture.

## PATIENTS AND METHODS

This single-center, retrospective study was conducted at Department of Orthopedics, Shanghai Sixth People's Hospital between January 2014 and December 2021. Patients' data were included

when: (i) painful and/or limited elbow and forearm movements existed, which disturbed daily activities, (ii) the bony prominence and bending forearm became cosmetic problems, and (iii) patients or parents of pediatric patients agreed with surgical intervention, while patients who refused surgical reconstruction or whose forearm had deformities caused by other diseases, e.g., congenital or post-traumatic proximal radioulnar synostosis multiple hereditary exostoses and chronic Essex-Lopresti injury, were excluded. A total of 22 patients (14 males, 8 females; mean age: 15.6±5.1 years; range, 6 to 25 years) who suffered from chronic Monteggia fracture were included. Except for nine of the patients who were skeletally mature (40.9%), the rest 13 (59.1%) were skeletally immature. The deformities were radiologically assessed according to Bado classification.<sup>[5]</sup> Eighteen of the deformities were classified as Bado type I, three as Bado type II, and one as Bado type III. Malunion ulna and

**TABLE I**  
Demographic data\*

Case	Age (year)	Sex	Side	Bado classification	FT (mo)	UL (mm)	EFI (d/cm)	BHI (d/cm)	DH	TSI (year)
1	14	Male	R	Type 1	36	21	23.8	38.1	R	8
2	22	Male	R	Type 1	33	33	20.3	30.6	R	6.5
3	18	Male	R	Type 1	41	20	26.5	41.5	R	6
4	8	Male	L	Type 1	53	23	23.9	36.5	R	4
5	12	Female	L	Type 1	50	31	21.0	31.0	R	5
6	6	Female	R	Type 1	47	19	24.7	39.5	R	3
7	19	Male	R	Type 1	48	28	20.7	34.3	R	11
8	25	Male	R	Type 1	36	30	20.7	33.3	R	15
9	23	Female	R	Type 2	46	32	20.3	32.8	R	14
10	13	Female	R	Type 2	44	22	24.1	45.0	R	8
11	15	Male	L	Type 1	42	21	25.2	44.3	R	9
12	17	Male	L	Type 1	28	23	22.2	40.9	R	12
13	11	Female	R	Type 3	33	20	25.0	41.0	R	5
14	20	Male	L	Type 1	35	18	26.1	45.6	R	12
15	22	Male	R	Type 1	40	19	26.3	46.3	R	12
16	21	Female	R	Type 1	41	23	23.5	40.4	R	13
17	15	Female	L	Type 1	43	21	24.8	41.9	R	7
18	15	Male	R	Type 1	58	23	22.6	37.0	R	9
19	14	Male	L	Type 1	60	29	21.0	35.2	R	7
20	12	Female	L	Type 1	22	21	26.2	41.9	R	7
21	13	Male	R	Type 2	29	33	20.9	33.3	R	8
22	9	Male	L	Type 1	33	20	26.5	47.5	R	5
Average	15.6±5.1				40.8±9.6	24.1±5.0	23.5±2.3	39.0±5.1		8.5±3.4

FT: Follow-up time; UL: Ulnar lengthen gained; EFI: External fixation index; BHI: Bone healing index; DH: Dominant hand; TSI: Trauma-to-surgery interval.

dislocated radial head existed in all of the patients preoperatively (Table I).

### Surgical procedures and postoperative care

Two stages of operations were performed: (i) close-wedge osteotomy, acute angulation and gradual lengthening of the ulna with monorail external fixator, and (ii) plate fixation once the lengthening was enough to reduce the radial head.

The first operation was carried out under brachial plexus nerve block anesthesia in adult patients and under general anesthesia in adolescents and children. The Boyd approach was utilized in patients whose preoperative range of forearm rotation was less than  $100^\circ$  (pronation plus supination) to debride of residual scar tissue. Monorail external fixator (Shanghai CIIC Hengkang Medical Instrument Co., Ltd. Shanghai, China) was, then, located with our specified positioning method and applied with two or more proximal half pins (Shanghai CIIC Hengkang Medical Instrument Co., Ltd. Shanghai, China) and two distal half pins. To facilitate the proximal ulna, one of the half pins should be beneath the coronoid process as close as possible. We precisely located the rail and osteotomy site as follows:

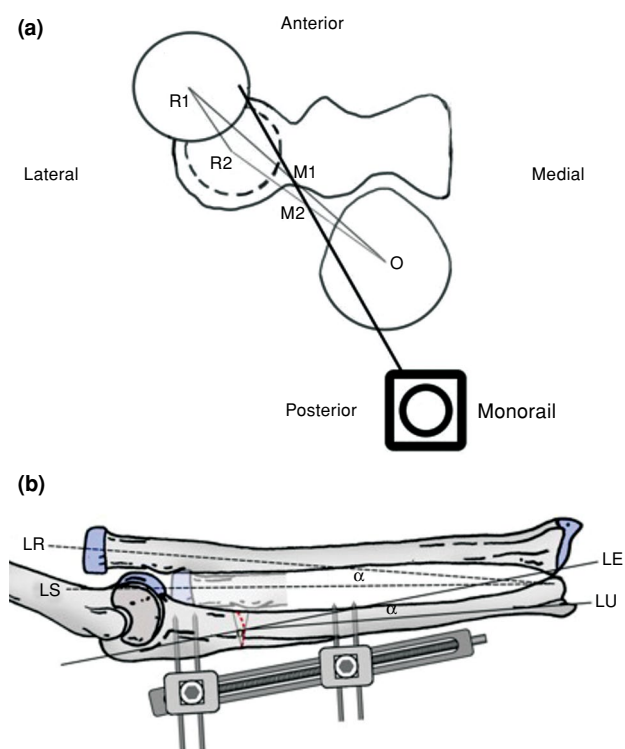
a) On the transverse view, the cross section of the monorail was determined according to the relative position of the dislocated radial head, the hypothesized reduced radial head (R2) and olecranon (O) (Figure 1a).

b) On the lateral-medial view, the Støren's line (LS), which travels through the center of the capitellum and proximal radial shaft, was applied to identify the alignment of the radiocapitellar joint.<sup>[22]</sup> Before osteotomy, the angle between the longitudinal axis of the monorail external fixator (LE) and the longitudinal axis of the ulna (LU) should equal to the angle (RSA) between the longitudinal axis of the radius (LR) and LS (Figure 1b).

c) Once the pins and external fixator were safely installed dorsal to the forearm, close-wedge osteotomy of the ulna was performed. We chose a plane where would be a possible proximal border of a radial notch according to the distance between the radial head and radial tubercle. Direction of the wedge equaled to the direction of the dislocated radial head, and the angle of the wedge should also equal to the RSA (Figure 1b). In Bado type I patients, the wedge was designed toward the anterior border of the ulna; to reduce the posteriorly dislocated radial head in type II patients, the wedge was designed toward the posterior border of the ulna; and for type III, toward the lateral border

of the ulna. After osteotomy, the external fixator was adjusted to be parallel to the distal longitudinal axis of the ulna.

Gradual distraction began at a rate of 0.75 mm per day after a latency of 7 days. During the lengthening period, the radius was pulled distally and against the direction of the dislocation through forearm interosseous membrane. For patients who were skeletally immature, the callus was transfixed with two additional Kirschner wires. All patients were scheduled for the follow-up before reduction which included outpatient appointment every two weeks



**FIGURE 1.** Conceptual graphs on how the monorail external fixator was located and how the osteotomy was performed. (a) On the transverse view, the midpoints (M1 and M2) of the segment which connects the dislocated radial head (R1) and olecranon (O), as well as the segment which connects the hypothesized reduced radial head (R2) and olecranon (O), are connected. This line must be perpendicular to the longitudinal axis of the rail. (b) The angle between the longitudinal axis of the monorail external fixator (LE) and that of the ulnar shaft distal to the osteotomy site (LU) before the osteotomy should equal to the angle (RSA) between the longitudinal axis of the radius (LR) and the Støren's line (LS). A plane was chosen to perform osteotomy where would be a possible proximal border of a radial notch according to the distance between the radial head and radial tubercle. And the angle of the wedge should also equal to the RSA. After osteotomy, the external fixator was adjusted to be parallel to the distal longitudinal axis of the ulna.

after distraction started and a last specific visit, if the radial head would be reduced within two weeks.

Postoperative movements of the shoulder, elbow, forearm and wrist was encouraged to avoid tendon adhesion and muscle atrophy.<sup>[23]</sup> The bony prominence (the dislocated radial head) gradually faded away during elongation and the reduction of radial head was confirmed by radiological examination. Another 15 to 20 days was waited for the stable formation of the fibrous tissue surrounding the radiocapitellar joint.

The monorail external fixator was completely removed before a locking compression plate (LCP) (Johnson & Johnson Medical Devices Co., Ltd., Shanghai, China) was inserted in the second step of surgery plan and the stability of the radiocapitellar joint was checked through full pronation of the forearm. Patients, then, kept the follow-up every month to ensure the bone union and reduction in one year. Eventually, the LCP was removed at least half a year after satisfying bone consolidation.

#### Data collection

Demographic data, including age, sex, injured side, dominant hand (DH), trauma-to-surgery interval (TSI), and follow-up time (FT), were collected via electric medical history system.

We evaluated the level of elbow pain with Visual Analog Scale (VAS) and ROM of the forearm and elbow preoperatively and at the time of final follow-up. Correction-related data were also measured, including the preoperative RSA and that at the final follow-up, the amount of ulnar lengthening (UL) gained, external fixator time (EFT), external fixator index (EFI), consolidation time (CT), and bone healing index (BHI). The UL refers to the radiological difference between the preoperative length of the ulnar and its length measured at the final follow-up. The EFI and BHI were calculated through the following formulae:

$$EFI = \frac{EFT}{UL} \text{ (d/cm)} \quad BHI = \frac{EFT+CT}{UL} \text{ (d/cm)}$$

The VAS was subjectively described by the patient preoperatively and at the final follow-up.

The ROM of the forearm and elbow was measured before and after the whole procedure. Function of the elbow was evaluated with Mayo Elbow Performance Score (MEPS) preoperatively and at the final follow-up.<sup>[10]</sup> Satisfaction comparison was measured using the Disabilities of Arm, Shoulder and Hand (DASH) score system preoperatively and at the final follow-up.<sup>[24]</sup>

#### Complications and management

Complications were recorded and treated, if observed. Local or venous antibiotics was applied, when track infection occurred. Acute nerve palsy and arterial crisis may be a consequence of too excessive elongation. In this case, the elongation should be stopped for at least two or three days and even the callus should be shortened 2 or 3 mm in size. Iliac crest autograft transplantation was the backup plan for delayed union and nonunion.

#### Statistical analysis

Statistical analysis was performed using the GraphPad Prism version 8.0 (GraphPad Software Inc., San Diego, CA, USA). Continuous variables were presented in mean  $\pm$  standard deviation (SD), while categorical variables were presented in number and frequency. Paired two-group t-test was applied to compare ROM, RSA, MEPS, and DASH score before and after the treatment. The Mann-Whitney U-test was applied to evaluate the VAS before and after the treatment. A *p* value of  $<0.05$  was considered statistically significant.

## RESULTS

#### Demographic data

The mean follow-up was  $40.8 \pm 9.6$  (range, 22 to 53) months. All patients were right hand-dominant and the mean TSI was  $8.5 \pm 3.4$  years on average. Six of them received additional radiocapitellar joint debridement at first surgery and eight of the pediatric patients received trans-callus Kirschner wire fixation. The mean UL, EFT, and BHI was  $24.1 \pm 5.0$  mm,  $23.47 \pm 2.26$  d/cm and  $9.00 \pm 5.12$  d/cm, respectively (Table I).

#### Outcomes

Objective parameters were all significantly improved in the aspects of elbow extension, elbow flexion, forearm pronation, forearm supination, and RSA ( $21.4 \pm 4.5^\circ$  preoperatively and  $2.0 \pm 1.4^\circ$  at the final follow-up,  $t=18.20$ ,  $p<0.05$ ) (Table II).

The level of pain due to the chronic injury was eliminated as mean VAS was significantly lower at the final follow-up compared to preoperative scoring ( $2.8 \pm 2.0$  preoperatively and  $0.5 \pm 0.9$  at the final follow-up,  $t=4.86$ ,  $p<0.05$ ). The function of the elbow and upper limb was restored, which was indicated by improved MEPS ( $73.2 \pm 12.5$  preoperatively and  $96.6 \pm 6.4$  at the final follow-up,  $t=7.70$ ,  $p<0.05$ ) and DASH ( $28.3 \pm 6.0$  preoperatively and  $4.1 \pm 2.0$  at the final follow-up,  $t=19.35$ ,  $p<0.05$ ) (Table II).

No major complications, such as re-dislocation, necrosis and nonunion, or minor complications, such as track infection were observed.

**Typical cases**

A 14-year-old male suffered from Bado type III chronic Monteggia fracture with a TSI of over eight years. His right forearm was in poor appearance with an abnormal carrying angle and bony prominence (dislocated radial head). Though the motion of his right elbow was slightly limited, the radial head remained obviously anterior dislocated, as RSA was 23° on the lateral view of the radiography. Ipsilateral elbow flexion and extension, and forearm pronation and supination were 120°, -4°, 73° and 77°, respectively (Figure 2a-f).

The patient received only close-wedge osteotomy and lengthening of the right ulna at first step of operation with three proximal half pins and two distal half pins monorail external fixator. The external fixator was installed according to our method mentioned above. Elbow ROM was carefully checked intraoperatively in case of the interference of the external fixator. After a latency of 7 days, the distal ulna was gradually lengthened at a speed of 0.75 mm per day for 28 days, and the radiocapitellar joint was eventually reduced (Figure 2g, h). After another 15-day latency, LCP was inserted via two minimal posterior forearm approach and the monorail external fixator was removed (Figure 2i, j). The LCP was removed 10 months after insertion, and the callus had already reached full consolidation (Figure 2k, l).

The patient acclimatized himself to the external fixator shortly after the first surgery. At the time of his final visit (at 36 months), the elbow flexion and extension, and forearm pronation and supination of the injured arm were 140°, 4°, 82° and 80°, respectively. Stability of the elbow was reconstructed as well as the ROM of elbow and forearm. Cosmetic problems were solved, and the patient with his parents was satisfied (Figure 2m-p).

**DISCUSSION**

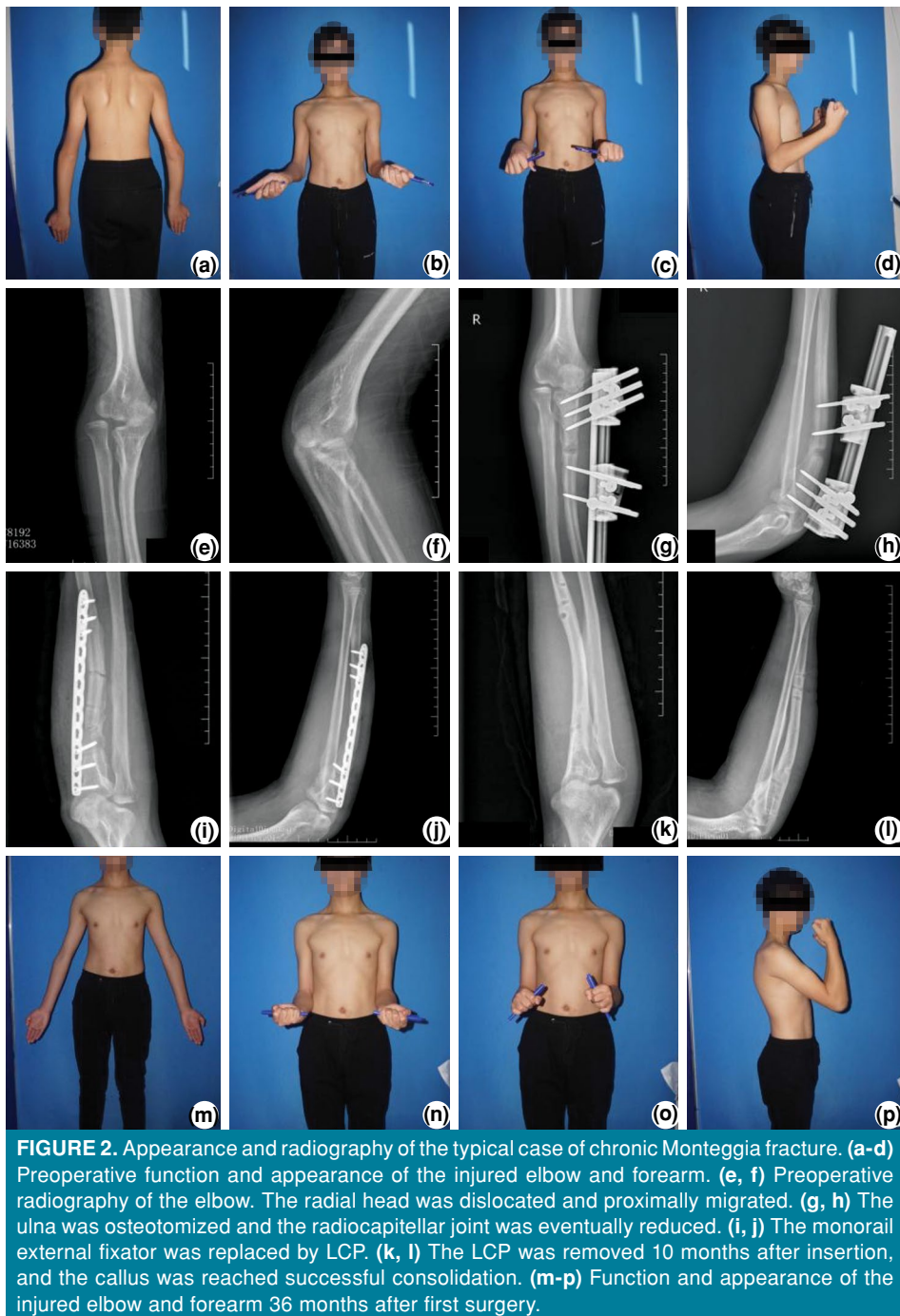
We introduced a novel technique in which acute angulation of the ulna was performed after osteotomy and the reduction of the radiocapitellar joint was achieved through gradual lengthening. We also provided a feasible site for osteotomy according to the position of radial tubercle and a viable angulating angle according to the angle between the radius and a hypothesized Støren's line. All patients eventually achieved satisfying outcomes and the function of injured elbow as well as upper limb was perfectly restored.

**TABLE II**  
Outcomes

Parameter	EE (°)	EF (°)	FP (°)	FS (°)	RSA (°)	VAS (points)	MEPS (points)	DASH (points)
Preoperative	-1.8±2.7	119.1±7.9	58.2±13.0	58.0±19.7	21.4±4.5	2.8±2.0	73.2±12.5	28.3±6.0
Last follow-up	2.6±1.1	138.9±7.4	74.5±6.0	75.1±6.2	2.0±1.4	0.5±0.9	96.6±6.4	4.1±2.0
t value	6.88	25.86	6.93	5.28	18.20	4.86	7.70	19.35
P value	<0.05	<0.05	<0.05	<0.05	<0.05	<0.05	<0.05	<0.05

EE: Elbow extension; EF: Elbow flexion; FP: Forearm flexion; FS: Forearm supination; RSA: The angle between the axis of proximal radius preoperatively and Støren's line; VAS: Visual Analog Scale; MEPS: Mayo Elbow Performance Score; DASH: Disability of arm-shoulder-hand score.





The missed Monteggia fracture or the chronic Monteggia fracture still remains a challenge for orthopedists to deal with, not only because of the proximal migration of the radius and the dysplastic changes of the radial head and capitellum, but also due to the difficulties in remodeling the ulna for the reduction of the dislocated radiocapitellar joint, as evidenced by numerous reconstruction

procedures.<sup>[1,2,6,25]</sup> These procedures included close or open reduction of the radial head, immediate or gradual lengthening of the ulna, artificial angulation of the ulna and annular ligament reconstruction (ALR).

The Bell-Tawse technique, consisting of osteotomy and immediate correction of the ulna with internal fixation, open reduction of the radial head and ALR

with triceps tendon, is one of the proven procedure for one-stage reconstruction of chronic Monteggia fracture.<sup>[10]</sup> The most difficult step of this technique is to stably insert the LCP, once the immediate elongation and angulation of the ulna promises simultaneous reduction of the radiocapitellar joint. To avoid mistake fixation and subluxation during these procedures, immediate angulating and distraction of the ulna after osteotomy for radial head reduction with hinged Ilizarov mini-fixator was advocated by Take et al.,<sup>[20]</sup> and Wang et al.<sup>[12]</sup> and Dukan et al.<sup>[15]</sup> introduced novel techniques using monorail external fixator for accurate correction of the osteotomized ulna and stable insertion of the LCP intraoperatively. Although the Bell-Tawse technique and its modified versions could guarantee satisfactory reduction intraoperatively and most patients received satisfying outcomes, severe complications, including nerve palsy, delayed union or nonunion, re-dislocation of the radial head and narrowing and, even necrosis of the radial neck after ALR.<sup>[6,7,12-14]</sup> On the other hand, safe and effective correction of the deformities could be achieved through gradual lengthening and angulation of the ulna using external fixation.

Ulnar osteotomy with angulation and gradual distraction using external fixator in treating chronic Monteggia fracture is less invasive without extensive exposure of the proximal ulna.<sup>[20,21]</sup> Gradual distraction can overcome tissue contracture and lower the incidence of nerve palsy and nonunion.<sup>[14]</sup> Although gradual elongation and angulation technique have promised outcomes in treating radial head dislocation caused by ulnar deformities, only few surgeons have advocated the use of gradual lengthening method in treating chronic Monteggia fracture.<sup>[16-18,26]</sup> Exner<sup>[18]</sup> was the first to apply Ilizarov method with simple osteotomy, and second-stage callotasis angulation and close reduction of the radial head in a 12-year-old patient with a TSI of over five years. Successful reduction was achieved and normal elbow and forearm function was regained in that case without any major complications. Bor et al.,<sup>[16]</sup> then, modified this technique with hinged elongation, ensuring that ulna was angulated during lengthening and the radial head was gradually reduced during elongation, and treated four chronic Monteggia fracture patients, resulting in significantly improved ROM of the elbow and forearm. Li et al.<sup>[19]</sup> performed Z-shaped osteotomy, overlapped the two ends as bayonet-like fracture instead of angulating the ulna for further reduction of the radial head, and added second-stage ALR, if the radial head could not be reduced once the ulna was elongated to adequate

length. Although a significant improvement was also seen in aspects of postoperative ROM and MEPS, this technique, in our opinion, is rather difficult since intraoperative Z-shape osteotomy requires higher plastic surgery expertise and may not follow the route calculated preoperatively. Besides, the reduction of the radiocapitellar joint seems too expectant, as open reduction and ALR was unavoidable in some cases. In our study, we applied close-wedge or V-shaped osteotomy by considering that (i) the angle could be easily calculated according to the axis of proximal radius and Storen's line and (ii) maximized contact area of the two bone ends would present lower rate of delayed union and nonunion.<sup>[27]</sup> However, angulation of the ulna prior to elongation in this technique has a strict and clear contraindication that the track of the radius cannot be blocked by the humerus at any time during angulation and elongation. Once the blockage is confirmed by preoperative three-dimensional CT deduction, alternative methods should be concerned, including hinged Ilizarov ring fixators.<sup>[16,26]</sup>

The optimal osteotomy site should be carefully concerned to provide solid fixation of the proximal ulna and to avoid delayed union and nonunion. Yet, few studies have concluded where exactly the osteotomy should be performed. Di Gennaro et al.<sup>[9]</sup> reported that osteotomy at proximal one-third presented lower rate of bone nonunion. Some researchers believed that center of rotation angulation (CORA) might be a better site for osteotomy, while others recommended meta-to-diaphyseal area.<sup>[28-30]</sup> Recent studies have shown that the involvement of proximal radioulnar joint (PRUJ) should not be ignored in chronic Monteggia fracture, as it can be an important factor for prognosis.<sup>[3,8]</sup> In this study, we chose a plane where would be a possible proximal border of a radial notch, as we considered that the interaction between the radial tubercle and the callus during postoperative physical rehabilitation would bring out a notch-like callus for PRUJ reconstruction. The re-established stability of PRUJ may be a reason for which our patients received satisfied forearm rotation without re-dislocation of the radial head.

Whether ALR should be performed is still controversial in the literature. Those who aimed at facilitating the radial head advocated performing the reconstruction in patients with a TSI less than two months.<sup>[9,10,12,31]</sup> The repair of the remnant of annular ligament or autograft transplantation, including triceps tendon, palmaris longus and forearm fascia, was performed in these studies, and complication rate of lost ROM of forearm, narrowing of the radial neck and its necrosis is eliminating in recent years.<sup>[19,32-36]</sup>

Other researchers, applying either immediate or gradual correction of the deformities, did not chose ALR to lower the incidence of open reconstruction-related complications.<sup>[16,19,37]</sup> In the current study, we only performed joint debridement in patients with severely limited preoperative ROM of forearm to deliberate forearm pronation and supination, as the remnant of annular ligament was difficult to recognize after years of TSI and might even go atrophy. The stability of the reduced radiocapitellar joint could be restored by fibrous scar tissue proliferation during latency time, as well as the reestablished PRUJ.

We also performed plate fixation before removing the monorail fixator. Healing of the osteotomized ulna usually takes six to eight weeks, which is similar to the time of postoperative latency and elongation time in this study. Replacing the external fixator with LCP would let the skin heal in advance and local cleaning could be performed earlier. Besides, most of our patients were young people who required to use keyboards and writing with the injured hand. Early removing of the external fixator would bring about early adjustment to their daily work. The replacement of internal fixation might also enhance the adolescents' self-confidence since the "weird" apparatus disappeared. Whether this plating after lengthening technique ensures better outcomes than using just external fixation for lengthening and consolidation needs further investigation.

Nonetheless, this study has certain limitations. First, the sample size of this retrospective study was rather small and most of the patients were with Bado type I chronic Monteggia fracture, making the efficacy of this technique less persuasive for type II and type III cases. Second, we did not include Bado type IV chronic Monteggia fractures, as managing concomitant radius fractures could be sophisticated and even need radial head arthroplasty. How to treat this type of chronic Monteggia fracture with the method of close-wedge osteotomy and gradual lengthening needs further investigation. Besides, all patients were treated a few years after the injury and ALR were not performed in any of the patients due to the dense adhesion of the remnant. Finally, DASH scoring system was the only utilized parameter for subjective satisfaction of the outcomes, which may have led to certain bias in pediatric patients.

In conclusion, close-wedge osteotomy and gradual lengthening with monorail external fixator in the treatment of chronic Monteggia fracture showed great efficacy and all patients received

satisfactory outcomes in this study. We also provided a specified osteotomy site aiming at PRUJ reconstruction. Further long-term studies are still needed to testify the efficacy and complications of this method.

**Ethics Committee Approval:** Shanghai Sixth People's Hospital human research committee (Date of review 2020-08-25, No. 2020-107). The study was conducted in accordance with the principles of the Declaration of Helsinki.

**Patient Consent for Publication:** A written informed consent was obtained from each patient.

**Data Sharing Statement:** The data that support the findings of this study are available from the corresponding author upon reasonable request.

**Author Contributions:** Manuscript drafting: R.Z., X.W.; Data collection: S.L.; Data analysis: H.R.; Study design: J.X., Q.K.

**Conflict of Interest:** The authors declared no conflicts of interest with respect to the authorship and/or publication of this article.

**Funding:** Received financial support from National Natural Science Foundation of China (No. 82072421) and National Science Foundation of Shanghai (No.20ZR1442200).

## REFERENCES

1. Soni JF, Valenza WR, Pavelec AC. Chronic Monteggia. *Curr Opin Pediatr* 2019;31:54-60.
2. Hubbard J, Chauhan A, Fitzgerald R, Abrams R, Mubarak S, Sangimino M. Missed pediatric Monteggia fractures. *JBJS Rev* 2018;6:e2.
3. Ring D. Monteggia fractures. *Orthop Clin North Am* 2013;44:59-66.
4. Delpont M, Louahem D, Cottalorda J. Monteggia injuries. *Orthop Traumatol Surg Res* 2018;104:S113-S120.
5. Bado JL. The Monteggia lesion. *Clin Orthop Relat Res* 1967;50:71-86.
6. Goyal T, Arora SS, Banerjee S, Kandwal P. Neglected Monteggia fracture dislocations in children: A systematic review. *J Pediatr Orthop B* 2015;24:191-9.
7. Chin K, Kozin SH, Herman M, Horn BD, Ebersson CP, Bae DS, et al. Pediatric Monteggia fracture-dislocations: Avoiding problems and managing complications. *Instr Course Lect* 2016;65:399-407.
8. Gryson T, Van Tongel A, Plasschaert F. The management of chronic paediatric Monteggia fracture-dislocation. *J Orthop* 2021;24:65-76.
9. Di Gennaro GL, Martinelli A, Bettuzzi C, Antonioli D, Rotini R. Outcomes after surgical treatment of missed Monteggia fractures in children. *Musculoskelet Surg* 2015;99 Suppl 1:S75-82.
10. Mohan Kumar EG, Yathisha Kumar GM, Noorudheen M. Functional outcome of bell tawse procedure for the management of chronic unreduced Monteggia fracture-dislocation in children. *Indian J Orthop* 2019;53:745-50.
11. Gallone G, Trisolino G, Stilli S, Di Gennaro GL. Complications during the treatment of missed Monteggia fractures with unilateral external fixation: A report on 20 patients in a 10-year period in a tertiary referral center. *J Pediatr Orthop B* 2019;28:256-66.



12. Wang Q, Du MM, Pei XJ, Luo JZ, Li YZ, Liu YC, et al. External fixator-assisted ulnar osteotomy: A novel technique to treat missed Monteggia fracture in children. *Orthop Surg* 2019;11:102-8.
13. De Boeck H. Radial neck osteolysis after annular ligament reconstruction. A case report. *Clin Orthop Relat Res* 1997;(342):94-8.
14. Nishimura M, Itsubo T, Horii E, Hayashi M, Uchiyama S, Kato H. Tardy ulnar nerve palsy caused by chronic radial head dislocation after Monteggia fracture: A report of two cases. *J Pediatr Orthop B* 2016;25:450-3.
15. Dukan R, Le Hanneur M, Pannier S, Fitoussi F. Use of an external fixator during one-step surgical management of missed chronic Monteggia injuries. *Orthop Traumatol Surg Res* 2022;108:102963.
16. Bor N, Rubin G, Rozen N, Herzenberg JE. Chronic anterior monteggia lesions in children: Report of 4 cases treated with closed reduction by ulnar osteotomy and external fixation. *J Pediatr Orthop* 2015;35:7-10.
17. Lammens J, Mukherjee A, Van Eygen P, Fabry G. Forearm realignment with elbow reconstruction using the Ilizarov fixator. A case report. *J Bone Joint Surg [Br]* 1991;73:412-4.
18. Exner GU. Missed chronic anterior Monteggia lesion. Closed reduction by gradual lengthening and angulation of the ulna. *J Bone Joint Surg [Br]* 2001;83:547-50.
19. Li J, Zhao X, Rai S, Ding Y, Zhang Q, Ze R, et al. Two-stage strategy for neglected Monteggia fracture in children: A retrospective study of 51 patients. *Medicine (Baltimore)* 2021;100:e25129.
20. Take M, Tomori Y, Sawaizumi T, Majima T, Nanno M, Takai S. Ulnar osteotomy and the ilizarov mini-fixator for pediatric chronic monteggia fracture-dislocations. *Medicine (Baltimore)* 2019;98:e13978.
21. Yuan Z, Xu HW, Liu YZ, Li YQ, Li JC, Canavese F. The use of external fixation for the management of acute and chronic Monteggia fractures in children. *J Child Orthop* 2019;13:551-9.
22. Storen G. Traumatic dislocation of the radial head as an isolated lesion in children; Report of one case with special regard to roentgen diagnosis. *Acta Chir Scand* 1959;116:144-7.
23. Wang S, Lu M, Wang W, Yu S, Yu R, Cai C, et al. Macrophage polarization modulated by NF- $\kappa$ B in polylactide membranes-treated peritendinous adhesion. *Small* 2022;18:e2104112.
24. Ostlie K, Franklin RJ, Skjeldal OH, Skronidal A, Magnus P. Assessing physical function in adult acquired major upper-limb amputees by combining the Disabilities of the Arm, Shoulder and Hand (DASH) outcome questionnaire and clinical examination. *Arch Phys Med Rehabil* 2011;92:1636-45.
25. Kim HT, Conjares JN, Suh JT, Yoo CI. Chronic radial head dislocation in children, Part 1: Pathologic changes preventing stable reduction and surgical correction. *J Pediatr Orthop* 2002;22:583-90.
26. Zhang R, Wang X, Liu S, Ruan H, Xu J, Kang Q. Hinge positioning method of Ilizarov apparatus in correcting radial head luxation caused by multiple hereditary exostoses. *Jt Dis Relat Surg* 2022;33:40-50.
27. Xu J, Sun Y, Wu T, Liu Y, Shi L, Zhang J, et al. Enhancement of bone regeneration with the accordion technique via HIF-1 $\alpha$ /VEGF activation in a rat distraction osteogenesis model. *J Tissue Eng Regen Med* 2018;12:e1268-e1276.
28. Kim HT, Ahn TY, Jang JH, Kim KH, Lee SJ, Jung DY. A graphic overlay method for selection of osteotomy site in chronic radial head dislocation: An evaluation of 3D-printed bone models. *J Pediatr Orthop* 2017;37:e88-e95.
29. Posey SL, Cole HA, Halverson S, Stutz C, Schoenecker JG. Intra-articular Monteggia fracture: A case study of using the center of rotational angulation to improve a functional outcome. *J Orthop Case Rep* 2018;8:27-30.
30. Xu Z, Li Y, Wang Z, Cai H. Open reduction combined with CORA-based osteotomy of the ulna in the treatment of missed Bado type I Monteggia injury: A retrospective study of 5 cases. *Medicine (Baltimore)* 2017;96:e8609.
31. Nakamura K, Hirachi K, Uchiyama S, Takahara M, Minami A, Imaeda T, et al. Long-term clinical and radiographic outcomes after open reduction for missed Monteggia fracture-dislocations in children. *J Bone Joint Surg [Am]* 2009;91:1394-404.
32. Wang MN, Chang WN. Chronic posttraumatic anterior dislocation of the radial head in children: Thirteen cases treated by open reduction, ulnar osteotomy, and annular ligament reconstruction through a Boyd incision. *J Orthop Trauma* 2006;20:1-5.
33. Kim HT, Park BG, Suh JT, Yoo CI. Chronic radial head dislocation in children, Part 2: Results of open treatment and factors affecting final outcome. *J Pediatr Orthop* 2002;22:591-7.
34. Cai C, Wang W, Liang J, Li Y, Lu M, Cui W, et al. MMP-2 responsive unidirectional hydrogel-electrospun patch loading TGF- $\beta$ 1 siRNA polyplexes for peritendinous anti-adhesion. *Adv Funct Mater* 2021;31:2008364.
35. Hirayama T, Takemitsu Y, Yagihara K, Mikita A. Operation for chronic dislocation of the radial head in children. Reduction by osteotomy of the ulna. *J Bone Joint Surg Br* 1987;69:639-42.
36. Cai C, Zhang X, Li Y, Liu X, Wang S, Lu M, et al. Self-healing hydrogel embodied with macrophage-regulation and responsive-gene-silencing properties for synergistic prevention of peritendinous adhesion. *Adv Mater* 2022;34:e2106564.
37. Rajasekaran S, Venkatadass K. "Sliding angulation osteotomy": Preliminary report of a novel technique of treatment for chronic radial head dislocation following missed Monteggia injuries. *Int Orthop* 2014;38:2519-24.