









## Severe spaghetti wrist injury: Should we expand the terminology from wrist to proximal forearm?

Feiyan Wang, MD , Rui Zhang, MD\* , Shenghe Liu, MD , Hongjiang Ruan, MD ,  
Jia Xu, MD , Qinglin Kang, MD 

Department of Orthopedics, Shanghai Jiao Tong University Affiliated Sixth People's Hospital, Shanghai, China

Constant use of hand to carry out daily living makes the superficial anatomic structures of the wrist and distal forearm vulnerable to major injuries which may result in lifelong dysfunction as well as psychological, economic, and social consequences.<sup>[1,2]</sup> Multicomponent soft tissue injuries of the wrist and distal forearm, also known as “spaghetti wrist injuries”, refer to an extensive volar laceration which at least three structures of the 12 flexor tendons, two arteries and two nerves are transected between the distal wrist crease and flexor musculotendinous junction.<sup>[3,4]</sup> Among the severed structures, devastating functional deficiency is more common in those whose medial and/or ulnar nerves are completely severed.

Received: March 19, 2022

Accepted: April 05, 2022

Published online: July 06, 2022

**Correspondence:** Qinglin Kang, MD. Department of Orthopedics, Shanghai Jiao Tong University Affiliated Sixth People's Hospital, 200233 Shanghai, China.

E-mail: orthokang@163.com

**Correspondence:** Jia Xu, MD. Department of Orthopedics, Shanghai Jiao Tong University Affiliated Sixth People's Hospital, 200233 Shanghai, China.

E-mail: xujia0117@126.com

DOI: 10.52312/jdrs.2022.652

\* Co-First Author

**Citation:** Wang F, Zhang R, Liu S, Ruan H, Xu J, Kang Q. Severe spaghetti wrist injury: Should we expand the terminology from wrist to proximal forearm?. Jt Dis Relat Surg 2022;33(2):273-284.

©2022 All right reserved by the Turkish Joint Diseases Foundation

This is an open access article under the terms of the Creative Commons Attribution-NonCommercial License, which permits use, distribution and reproduction in any medium, provided the original work is properly cited and is not used for commercial purposes (<http://creativecommons.org/licenses/by-nc/4.0/>).

### ABSTRACT

**Objectives:** This study aims to point out the key principles for the management of multicomponent soft tissue injuries of the wrist and forearm to discuss whether we should expand the term “spaghetti” from the wrist to forearm in such terrifying cases.

**Patients and methods:** Data from a total of 50 patients (44 males, 6 females; mean age:  $48.5 \pm 25.7$  years; range, 10 to 70 years) who were treated for multicomponent soft tissue injuries of the wrist and forearm, including at least one major artery and one major nerve, between February 2020 and December 2021 were retrospectively analyzed. The patients were divided into the wrist injury group (n=30) and forearm injury group (n=20) according to the location of laceration. Demographic characteristics, including age, sex ratio and mechanism and side of injury, total lacerated structures, and outcomes, including tendon function, opposition, intrinsic muscle function, deformities, sensation and grip strength were evaluated.

**Results:** In the wrist injury group, a mean of  $12.27 \pm 3.53$  structures at the volar side were injured. It took a mean time of  $1.8 \pm 0.4$  h for emergency surgical repair and, after a mean of  $16.6 \pm 5.3$  month follow-up, most patients received excellent/good outcomes in the six aspects. In the forearm injury group, a mean of  $12.95 \pm 2.96$  structures at the volar side were injured. It took an average time of  $2.1 \pm 0.4$  h for emergency surgical repair and, after a mean of  $15.4 \pm 6.4$  month follow-up, most patients received excellent/good outcomes and were satisfied with the functional recovery. Only surgical time ( $p=0.018$ ) and final grip strength ( $p=0.023$ ) between the two groups showed a statistically significant difference.

**Conclusion:** We propose to merge the severe wrist and proximal forearm laceration of multiple tendons/muscles with at least one major artery and one major nerve as a whole, namely the spaghetti-ketchup injury, since the laceration of wrist and that of proximal forearm in this study share similar mechanisms and outcomes after primary repair or reconstruction.

**Keywords:** Complex forearm trauma, expansion, multiple tissue injury, outcomes, spaghetti wrist, terminology.

Although spaghetti wrist injuries may cause catastrophic functional outcomes and are frequently seen among young and middle-aged population, who are the main work force of the society, there remains relatively little data of literature discussing this specific type of injury.<sup>[3-14]</sup>

The raging pandemic novel coronavirus 2019 disease (COVID-19) has interrupted all aspects of routine life and industries and has brought great depression, anxiety and rising unemployment to the society.<sup>[2]</sup> During our microsurgical practice since 2020, we have seen multicomponent soft tissue injuries of the upper limbs in patients who vented their feelings by glass punching or suicide, and who were amateurs to use electrical saws or lathes to make a living and were accidentally hurt. Interestingly, the injured areas of these patients were sometimes beyond the typical region of spaghetti wrist injury, for instance, proximal to the musculotendinous junction. Besides, the mechanism of these laceration injuries may involve not only the conventional cutting and stabbing, but also avulsion and twisting, even with fractures. Although there are differences between these injuries and spaghetti wrist injury in the perspectives of position and mechanism, they share similar depressing outcomes of poor motor and sensory function of the wrist and hand.

In the present study, we aimed to point out the key principles for the management of multicomponent soft tissue injuries of the wrist and forearm through a retrospective review of a large group of patients

and to discuss whether we should expand the term “spaghetti” from the wrist to forearm in such terrifying cases.

## PATIENTS AND METHODS

### Study design and study population

This single-center, retrospective study was conducted at the Department of Orthopedics, Shanghai Jiao Tong University Affiliated Sixth People’s Hospital between February 2020 and December 2021. Data from a total of 50 patients (44 males, 6 females; mean age: 48.5±25.7 years; range, 10 to 70 years) who were treated for multicomponent soft tissue injuries of the wrist and forearm were retrospectively obtained through scheduled follow-up for a minimum period of six months. Patients who met the following criteria were included: (i) a single laceration between the distal wrist crease and the line connecting lateral and medial humeral condyles, with or without a single laceration at ipsilateral hand; (ii) a minimum of three volar structures travelling through the forearm were transected, involving at least one major artery (the ulnar and/or radial artery) and at least one major nerve (the ulnar and/or median nerve); and (iii) arterial injuries did not impair the

**TABLE I**  
Modified classification system of spaghetti wrist<sup>[15]</sup>

	Grade 1	Grade 2	Grade 3
Lacerated structures			
No. of volar structures	≤5	6-9	≥10
Nerve*	Ulnar or median	Ulnar and/or median	Ulnar and/or median
Artery**	Ulnar or radial	Ulnar and/or radial	Ulnar and/or radial
Flexor tendons	≤3	4-7	≥8
Extensor tendons***	- or +	- or +	- or +
Bones***	- or +	- or +	- or +
Type of laceration			
A1: Sharp	A1	A1	A1
A2: Crush/avulsive	A2	A2	A2
A3: Infected	A3	A3	A3
Type of repair****			
B1: Primary	B1	B1	B1
B2: Delayed primary	B2	B2	B2
B3: Secondary	B3	B3	B3

\* Specify laceration of the cutaneous nerves; \*\* Specify laceration of major veins; \*\*\* Specify number of tendons and bones; \*\*\*\* Specify timing of repair of each structure.

blood supply of the hand. The included patients were, then, classified according to the modified classification system by Koshy et al.<sup>[15]</sup> (Table I). Patients with burn injuries, soft tissue defects, severe contamination, history of hand surgery and any musculoneuropathy or psychiatric disease were excluded.

The patients were divided into two groups according to the position of the wound. Those whose wounds siting within distal 50% forearm, which had no chance of forearm muscle belly injury, were grouped as the wrist injury group (n=30).<sup>[16]</sup> The remaining patients were grouped as forearm injury group (n=20), in which cases forearm muscles were interrupted.

### Surgical procedure and postoperative care

One-stage debridement and repair of the soft tissue were performed within 8 h in all patients after emergency visit by a single experienced surgical team. Antitetanic immunoglobulin serum and broad-spectrum antibiotics were administered to these patients after preoperative testing. To screen out potential COVID-19 virus carrier, the result of nucleic acid testing was of necessity for operating room arrangement since August 1<sup>st</sup>, 2021. Emergency operation was carried out under brachial plexus anesthesia, tourniquet control and operation microscope magnification by Zeiss OPMI PENTERO 900 (Zeiss Co., Baden-Württemberg, Germany).

**TABLE II**  
Postoperative physiotherapy protocol of spaghetti wrist<sup>[6]</sup>

	Weeks				
	1-4	5-6	7	8	9-10
Splint	Dorsal extension block splint. Wrist 20 to 30° flexion, MCP 60° flexion, IP neutral	Wrist neutral, MCP 20° flexion, IP neutral		Ceasing splint	
Metal fixation	External fixation	Internal fixation replacement	Pulsed ultrasound		Tendon gliding
Every-other-day supervised physiotherapy	Passive flexion and restricted active extension of fingers in splint	Pulsed ultrasound			
	Compressive bandage in splint	Ceasing bandage	Tendon gliding		Scar tissue mobilization
	Tendon gliding	Tendon gliding	Scar tissue mobilization		Silicone sheet
	Scar tissue mobilization	Scar tissue mobilization	Silicone sheet		Isometric finger flexion
Home exercise programme	Silicone sheet	Silicone sheet	Isometric finger flexion		HVPGS
	Passive flexion and active extension of fingers in splint	Active finger flexion and extension in splint	Tenodesis exercises		
	Scar tissue massage (every 2h daily)	Scar tissue massage (every 3h daily)	Isometric finger flexion		
			Tendon gliding Scar tissue massage Grasping sponge (2 times daily)		

MCP: Metacarpophalangeal joints; IP: Interphalangeal joints; HVPGS: High voltage pulsed galvanic current, applied in patients without internal fixation.

An axial longitudinal forearm exposure was performed incorporating with the initial transverse wound and the carpal tunnel was opened during severe transected ends retraction for adequate tissue identification and reconstruction. After precise dissection, all transected structures were identified and grouped for step-by-step repair through flexor digitorum profundus, flexor pollicis longus, arteries and vessels, flexor digitorum superficialis (FDS), flexor carpi and palmaris longus (PL). External fixation was applied before soft tissue repair, if wrist and/or forearm fractures existed. Transected dorsal structures were reunited after volar structure reconstruction. Tendon repair was performed by Tajima-Kessler two-strand technique using 3-0 nylon sutures with two buried knots and was reinforced with 4-0 continuous peritendinous suture. Muscles were repaired with 2-0 absorbable suture and transected arteries were anastomosed with 8-0 polypropylene sutures under microscope. Epineural suturing was performed

with 8-0 polypropylene in cases with sharp nerve injuries, while nerve release was added when tension on proximal and distal ends restricted nerve repair. No neural or vascular graft was required during one-stage reconstruction. Hand surgery was, then, carried out, if necessary.

Dorsal extension block splint was applied postoperatively in cases without fractures or the fracture cannot be fixed with external fixation for financial and extent reasons. In cases with fractures and fixed externally, secondary intramedullary wires, Kirschner wires (K-wires) and plates fixation replacement were performed after at least two weeks according to the situation of skin and soft tissue repair.

Passive and active tendon exercises as well as physical rehabilitation protocol were presented according to Boynuyogun et al.<sup>[6]</sup> (Table II). All patients stick to the follow-up plan at one, three, and six weeks, and later every month after the initial surgery,

**TABLE III**  
Spaghetti wrist follow-up evaluation system<sup>[10]</sup>

	Tendon function	Opposition	Intrinsic	Deformities	Sensation	Grip strength
Excellent	Individual tendon function is evident with 85% to full range of motion or finger flexion to 1.0 cm or less from the distal palmar crease	When the tip of the thumb moves freely over the three phalanges of the other four fingers	When the patient can do both finger abduction and adduction with negative Froment sign	Major if there is both claw and ape hand	When two-point discrimination is less than 10 mm	At least 90% of contralateral hand
Good	70-84% total normal range of motion or 2.0 cm from the distal palmar crease	When the tip of the thumb touches only the tip of the other four fingers	When the patient can do both finger abduction and adduction with positive Froment sign		When two-point discrimination is 10-20 mm	75-90% of contralateral hand
Fair	59% total normal range of motion		When the patient can do either finger abduction or adduction with positive Froment sign	Minor if there is either claw or ape hand	When two-point discrimination is more than 20 mm with light touch and pinprick sensation	50-75% of contralateral hand
Poor	Fixed contractures or adhesions	When the tip of the thumb cannot reach the tip of the other four fingers	When the patient cannot do finger abduction or adduction with positive Froment sign		When there are tropic changes or skin ulceration	<50% of contralateral hand

unless specific complications occurred which needed closer observation.

### Data collection and clinical assessment

Age, sex, comorbidities, date of injury, time from injury to emergency, time waiting for surgery, time of surgery and hospitalization, mechanism of injury, affected hand with position of the wound, type of fixation and transected structures were noted. Physical examinations, including tendon function, opposition, intrinsic hand function, deformity and sensitivity, were assessed through the evaluation system reported by Noaman<sup>[10]</sup> at last follow-up which was at least 4.5 months after the first surgery (Table III).

Disability of Arm, Shoulder and Hand (DASH) questionnaire was also applied for subjective evaluation which contained overall activities of daily living, pain, work performance, esthetics and subjective satisfaction with hand function<sup>[17]</sup> preoperatively and at the final follow-up.

### Statistical analysis

Statistical analysis was performed using the GraphPad Prism version 5.0. (Graphpad Software Inc., San Diego, CA, USA). Normal distribution was checked statistically. Descriptive data were expressed in mean  $\pm$  standard deviation (SD) for continuous variables, and in number and frequency for categorical variables. Unpaired two-group t-test was applied to compare age, time related with management and follow-up, numbers of injured structures, and objective outcomes (DASH scores). The chi-square t-test was applied to compare different characteristics of injuries of the two groups, including mechanisms, distribution of structure laceration, classification of the injury and subjective outcomes (the Noaman evaluation system). A *p* value of  $<0.05$  was considered statistically significant.

## RESULTS

### Wrist injury group

Of 30 wrist injury patients, all were right-hand dominant and the right extremity was involved in 14 patients (46.7%).

The most frequent mechanism of wrist injury group was electric saw-related laceration (43.3%), all were inadvertently, followed by glass-related laceration (40.0%). Blunt injury and knife-related injury were rarely seen.

Over 368 volar structures were repaired, of which 283 were tendons (pronator quadratus and

brachioradialis were included), 42 were arteries and 47 were nerves (superficial branch of radial nerve was included). Of the volar side, a mean of  $12.27 \pm 3.53$  structures were injured per patient, including  $9.43 \pm 2.91$  tendons,  $1.40 \pm 0.49$  arteries and  $1.57 \pm 0.62$  nerves. The most frequently injured volar tendons were PL (96.6%), flexor carpi radialis (FCR, 90.0%), and FDS of index finger (FDS2, 90.0%). The injury rates of radial artery, median nerve, ulnar artery and ulnar nerve were 76.7%, 83.3%, 63.3%, and 60.0%, respectively. Simultaneous injuries of both median and ulnar nerves occurred in 43.3% patients. Simultaneous transections of both radial and ulnar arteries were observed in 40.0% patients. Concomitant ulnar neurovascular bundle and flexor carpi ulnaris (defined as the ulnar triad) injury occurred in 40.0% patients, while the so defined radial triad injury, which refers to concomitant transections of PL, FCR, and median nerve, occurred in 83.3% patients. While grouping the patients according to the modified classification system, 30.0% were assessed as Grade 2 and 70.0% were Grade 3. A total of 90.0% of the lacerations were sharp (A1) and the rest were avulsion injuries (A2). All patients received first stage volar soft tissue repair or reconstruction (B1). All patients met the definition of spaghetti wrist injury, which contained at least three completely transected tendons and at least one major nerve and often a major artery, described by Puckett and Meyer.<sup>[13]</sup>

Two-thirds of the patients also suffered from a mean of  $2.2 \pm 2.4$  dorsal tendon transections, of which the most frequently involved was the first dorsal compartment, containing extensor pollicis brevis and abductor pollicis longus. Forty percent patients developed concomitant ipsilateral fractures, of which the most frequently involved were the carpal bones (10 bones), followed by six radius, six ulnar, and five metacarpal bones. Six of the fractured patients required one-stage K-wire fixation or one-stage external fixation and secondary plate fixation. The mean surgical time was  $1.8 \pm 0.4$  h with a mean emergency hospitalization time of  $5.8 \pm 1.9$  days (Table IV).

Artery reconstruction necessitated bridging with forearm superficial vein autologous grafts in three cases and artificial nerve graft bridging were performed in five cases where direct tension free suturing was difficult.

The mean follow-up was  $16.6 \pm 5.3$  months (Table IV). As for the evaluation based on the system reported by Noaman,<sup>[10]</sup> the majority of each aspect, namely tendon function, opposition, intrinsic function, deformity, sensation and grip

**TABLE IV**  
Demographic and clinical data of patients (n=50)

	Wrist injury			Forearm injury			t value/ $\chi^2$ value	p
	n	%	Mean $\pm$ SD	n	%	Mean $\pm$ SD		
Emergency surgery	30	60.0		20	40.0			0.722
Sex								0.721
Male	26	86.7		18	90.0			
Female	4	13.3		2	10.0			
Age (year)			50.9 $\pm$ 10.9			46.1 $\pm$ 14.2	0.359	0.721
Time								
Before emergency (h)			2.0 $\pm$ 0.3			2.1 $\pm$ 0.3	0.738	0.464
Before surgery (h)			2.0 $\pm$ 1.1			2.5 $\pm$ 1.3	1.373	0.176
Surgery (h)			1.8 $\pm$ 0.4			2.1 $\pm$ 0.4	2.455	0.018*
Hospitalization (d)			5.8 $\pm$ 1.9			7.0 $\pm$ 3.3	1.555	0.127
Follow-up (mo)			16.6 $\pm$ 5.3			15.4 $\pm$ 6.4	0.705	0.484
Mechanism of injury							7.611	0.179
Electric saw	13	43.3		8	40.0			
Glass punch	12	40.0		7	35.0			
Heavy object smash	2	6.7		0	0.0			
Lathe	0	0.0		1	5.0			
Ground injury	1	3.3		4	20.0			
Knife	2	6.7		0	0.0			
Side of injury							1.624	0.203
Left	16	53.3		7	35.0			
Right	14	46.7		13	65.0			
Fixation							1.794	0.408
Splint	24	80.0		14	70.0			
Kirschner wire	1	3.3		0	0.0			
External fixation with secondary plate fixation	5	16.7		6	30.0			
Major artery injury	42			27			0.135	0.713
Radial artery	23	54.8		16	59.3			
Ulnar artery	19	45.2		11	40.7			
Major nerve injury	47			39			7.536	0.057
Median nerve	25	53.2		19	48.7			
Superficial branch of the radial nerve	4	8.5		5	12.8			
Deep branch of the radial nerve	0	0.0		5	12.8			
Ulnar nerve	18	38.3		10	25.6			
Volar tendon laceration			9.4 $\pm$ 2.9			9.9 $\pm$ 2.1	0.606	0.547
Top 3 most affected tendon								
PL	29			20				
FCR	27			18				
FDS2	27			17				
Dorsal tendon laceration			2.2 $\pm$ 2.4			2.2 $\pm$ 2.7	0.044	0.965
Most affected tendon								
APL/EPB	11			8				
Ipsilateral fracture	28 (14/30)*			13 (7/20)*			11.920	0.018
Radius	6	21.4		7	53.8			
Ulna	6	21.4		4	30.8			
Humerus	1	3.6		2	15.4			
Carpal bones	10	35.7		0	0.0			
Metacarpal bones	5	17.9		0	0.0			
Classification								
Laceration structures							1.480	0.224
Grade 1	0	0.0		0	0.0			
Grade 2	9	30.0		3	15.0			
Grade 3	21	70.0		17	85.0			
Type of laceration							2.679	2.262
A1	27	90.0		15	75.0			
A2	3	10.0		4	20.0			
A3	0	0.0		1	5.0			
Type of repair							1.531	0.216
B1	30	100.0		19	95.0			
B2	0	0.0		1	5.0			
B3	0	0.0		0	0.0			
DASH score at final follow-up			17.3 $\pm$ 8.1			19.6 $\pm$ 6.5	1.033	0.307
Complications								
Temporary infection	2			1				
Wrist arthrodesis	1							
Elbow arthrodesis	1							

SD: Standard deviation; PL: Palmaris longus; FCR: Flexor carpi radialis; FDS: Flexor digitorum superficialis; \* Number of fractured bone (number of patients with fracture/number of patients in this group).

**TABLE V**  
Overall functional outcome evaluation based on the report of Noaman<sup>[10]</sup>

	Tendon function		Opposition		Intrinsic		Deformities		Sensation		Grip strength	
	n	%	n	%	n	%	n	%	n	%	n	%
<b>Wrist injury</b>												
Excellent	18	60.0	13	43.3	7	23.3	0	0.0	15	50.0	16	53.3
Good	7	23.3	11	36.7	18	60.0	17	56.7	14	46.7	11	36.7
Fair	2	6.7	5	16.7	4	13.3			1	3.3	3	10.0
Poor	3	10.0	1	3.3	1	3.3	13	43.3	0	0.0	0	0.0
<b>Forearm injury</b>												
Excellent	10	50.0	3	15.0	4	20.0	0	0.0	4	20.0	3	15.0
Good	3	15.0	10	50.0	9	45.0	11	55.0	12	60.0	14	70.0
Fair	5	25.0	5	25.0	5	25.0			3	15.0	3	15.0
Poor	2	10.0	2	10.0	2	10.0	9	45.0	1	5.0	0	0.0
$\chi^2$ value	3.512		4.824		2.357		0.014		6.794		7.557	
P value	0.319		0.185		0.502		0.907		0.079		0.023*	

strength, distributed in excellent (60.0%), excellent (43.3%), good (60.0%), minor deformities (56.7%), excellent (50.0%) and excellent (53.3%). In total, almost 46.7% patients received excellent/good outcomes at last follow-up. However, no patients had excellent outcomes in all aspects for assessment, probably due to the laceration in at least one major nerve which would cause either claw or ape hand deformity (Table V). Arterial anastomosis had 100% patency rate during each follow-up. With a mean DASH score of  $17.3 \pm 8.1$  at the final follow-up, most patients were satisfied with the outcomes of the reconstruction of the severe injuries.

Two patients in the wrist injury group had temporary infection and were treated with oral and intravenous antibiotics medication. One wrist required one-stage wrist arthrodesis due to irreparable radiocarpal destruction. Besides, one elbow fracture resulted in unfortunate secondary arthrodesis due to nonunion and financial issue (Table IV).

#### Forearm injury group

Of 20 enrolled forearm injury patients, all were right-hand dominant and the right extremity was involved in 13 patients (65.0%).

The most frequent mechanism of wrist injury group was electric saw-related laceration (40.0%), all were inadvertently, followed by glass-related laceration (35.0%). Blunt injury were seen in four patients.

Overall, 259 volar structures were repaired, of which 198 were tendons/muscles (pronator teres and

brachioradialis were included), 27 were arteries and 39 were nerves (superficial and deep branches of radial nerve were included). Of the volar side, a mean of  $12.95 \pm 2.96$  structures were injured per patient, including  $9.90 \pm 2.10$  tendons/muscles,  $1.35 \pm 0.48$  arteries and  $1.90 \pm 0.99$  nerves. The most frequently injured volar tendons were PL (100.0%), FCR (90.0%) and FDP2 (95.0%). The injury rates of radial artery, median nerve, ulnar artery, ulnar nerve and radial nerve were 80.0%, 95.0%, 55.0%, 50.0%, and 25.0%, respectively. Simultaneous injuries of both median and ulnar nerves occurred in nine patients, among which one patient had additional radial nerve injury. Simultaneous transections of both radial and ulnar arteries were observed in 35.0% patients. Ulnar triad injury occurred in 50.0% patients, while radial triad injury occurred in 90.0% patients. While grouping the patients according to the modified classification system, 15.0% were assessed as Grade 2 and 85.0% were Grade 3. A total of 75.0% of the lacerations were sharp (A1) and the rest were 20.0% avulsion injuries (A2) and 5.0% infected (A3). All but one patient received first stage volar soft tissue repair or reconstruction (B1).

Thirteen of the 20 patients also suffered from a mean of  $2.2 \pm 2.7$  dorsal tendon transections, of which the most frequently involved was also the first dorsal compartment. A total of 35.0% patients developed concomitant ipsilateral fractures, of which the most frequently involved were the radius bones (seven bones), followed by four ulnae and two humeri. Six of the fractured patients required one-stage

external fixation and secondary plate fixation. The mean surgical time was  $2.1 \pm 0.4$  h with a mean emergency hospitalization of  $7.0 \pm 3.3$  days (Table IV).

Artery reconstruction necessitated bridging with forearm superficial vein autologous grafts in two cases and artificial nerve graft bridging were performed in three cases where direct tension free suturing was difficult.

The mean follow-up was  $15.4 \pm 6.4$  months (Table IV). As for the evaluation based on the system reported by Noaman,<sup>[10]</sup> the majority of each aspect, namely tendon function, opposition, intrinsic function, deformity, sensation and grip strength, distributed in excellent (50.0%), good (50.0%), good (45.0%), minor deformities (55.0%), good (60.0%), and good (70.0%). In total, only 40.0% patients received excellent/good outcomes at the final follow-up. Besides, no patients had excellent outcomes in all aspects for assessment (Table V). Arterial anastomosis had 100% patency rate during each follow-up. With a mean DASH score of  $19.6 \pm 6.5$  at the final follow-up, most patients were satisfied with the outcomes of the reconstruction of the severe injuries.

One patient in the forearm injury group had temporary infection and was treated with oral and intravenous antibiotics medication. No other major complications were observed (Table IV).

### Comparison of the groups

Although these two groups of patients had injuries at different segments of the forearm, which indicated different reconstruction strategies against tendon or muscle laceration and different rehabilitation programs, with at least one major artery and one major nerve involved, a significant difference was only observed in surgical time ( $1.8 \pm 0.4$  h to  $2.1 \pm 0.4$  h,  $t=2.455$ ,  $p=0.018$ ) (Table IV) and grip strength at the final follow-up ( $\chi^2=7.557$ ,  $p=0.023$ ) (Table V) between the wrist injury group and forearm injury group under the same rehabilitation program as described by Boynuyogun et al.<sup>[6]</sup>

Similar sex ratio, distribution of mechanism of injury, distribution of fixation, distribution of frequently involved tendon, artery and nerve, and classification of number and type of laceration and type of repair were seen in both groups, while it did not reach statistical significance. Also, there was no significant difference in the aspects of age, time before emergency, time before surgery, time for emergency hospitalization and DASH score at the final follow-up. Despite the ratio of dominant

injury site showed difference in count (wrist 16 left: 14 right to forearm 7 left: 13 right) between the two groups, there was no statistically significant difference ( $\chi^2=1.624$ ,  $p=0.203$ ) (Table IV).

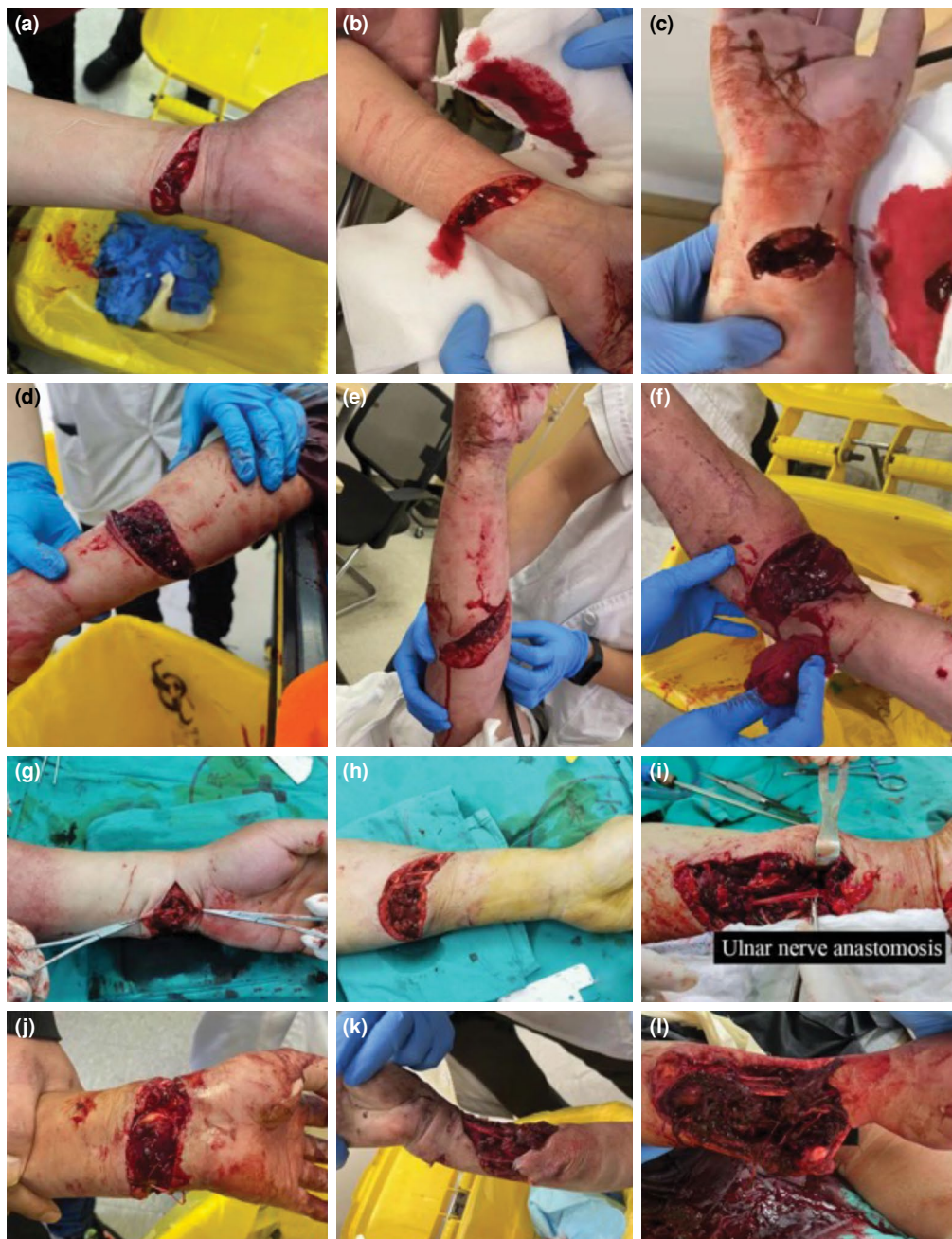Majority of outcomes of the patients differed in aspects of opposition, sensation and grip strength, as the wrist injury group showed excellent-dominant outcomes of the three parameters while the forearm injury group showed a good-dominant pattern (Table V). A more proximal level of injury might explain this difference which would result in more difficult nerve self-repair and muscle atrophy due to disuse and ischemia.

### DISCUSSION

The term “spaghetti wrist injury” was first introduced in 1985 by Puckett and Meyer<sup>[13]</sup> to highlight the devastating injury of the superficial structures of the volar forearm and wrist between the distal wrist crease and musculotendinous junction. The term “full-house spaghetti wrist injury” was, then, added by Widgerow<sup>[8]</sup> to describe a more severe spaghetti wrist injury circumstance in which more than 10 structures were transected. Since then, multiple studies have discussed the definition of this type of injury based on quantitative and qualitative characteristics. Apart from number of completely injured structures, functional consequences were another vital factor for the definition of this kind of injury, while Koshy et al.<sup>[15]</sup> recently reported modified classification of spaghetti based on number of lacerated structures, and type of laceration and repair. A more critically important problem was the lack of appropriate parameters for the evaluation of outcomes of this common injury, which was surpassed by Noaman<sup>[10]</sup> who reported an assessment system based on tendon and nerve reconstruction and intrinsic muscle function. We previously noticed that severe spaghetti wrist injury, involving at least one major artery and one major nerve, shared similar hand motor and sensory function with forearm laceration proximal to the musculotendinous junction using the Noaman’s evaluation system and, thus, we investigated whether the term “spaghetti” could be expanded from wrist injury to the forearm injury. Interestingly, similar outcomes and other baseline information were observed between the two groups of wrist and forearm injury in this retrospective study, although the spaghetti-like tendon injuries were sometimes replaced by ketchup-like muscle injuries (Figure 1).

In the current study, due to strict inclusive and exclusive criteria, finally 50 patients, among which





**FIGURE 1.** Different kinds of severe typical spaghetti wrist and forearm ketchup-like injury involving at least one major nerve and major artery during COVID-19 pandemic. (a) Suicidal spaghetti wrist involving ulnar triad and volar tendons. (b) A more proximal suicidal spaghetti wrist involving ulnar triad and volar muscles and tendons. (c) Glass-related spaghetti wrist involving radial triad and volar tendons. (d) Glass-related spaghetti wrist involving both ulnar and radial triad and volar muscles and tendons. (e) Glass-related forearm ketchup-like injury involving ulnar triad and volar and dorsal muscles. (f) Glass-related forearm ketchup-like injury involving radial triad, humeral vein and volar muscles. (g) Electric saw-related spaghetti wrist involving ulnar triad, volar tendons and ulna. (h) A more proximal electric saw-related spaghetti wrist involving radial triad and volar muscles and tendons. Median nerve, radial artery and superficial branch of radial nerve were anastomosed. (i) Oblique to longitudinal electric saw-related forearm ketchup-like injury involving ulnar triad and volar muscles and tendons. (j) Crush spaghetti wrist caused by lathe involving radial triad and volar tendons. (k) Avulsive spaghetti wrist and forearm ketchup-like injury caused by machine tool involving multiple tissue damage. (l) Avulsive and infected spaghetti wrist and forearm ketchup-like injury caused by blender involving multiple tissue damage.

30 were spaghetti wrist injury and 20 were proximal forearm laceration, concluded a mean of  $16.1 \pm 5.8$  months of follow-up. However, these patients showed different demographic patterns to previous studies, since glass related trauma was the second common mechanism of injury in wrist injury group (40.0%) and forearm group (35.0%), and a predominance of involvement of relatively middle-aged men ( $50.9 \pm 10.9$  years and  $46.1 \pm 14.2$  years, respectively). In previous studies, instead, a younger population of spaghetti wrist injury with a mean age of 17.1 to 34.7 years was reported, along with glass-related trauma as dominant mechanism (55% to 100%).<sup>[3,4,7,10,11,14]</sup> These differences could be explained by several reasons. As one of the largest industrial nations, China has seen great amount of industry-related injury including electric saw laceration and lathe smash in the past decades, which have contributed to the majority of civil spaghetti wrist injuries. With the recent spread of university education in China, young individuals in this country are asked to take part in technological industry with less potential of life-threatening issues instead of manual labor. Besides, middle-aged population has higher pressure of raising children and supporting the elder. During the pandemic of COVID-19 in China, compulsory restrict of population mobility left this less educated population no choice but to work in local factories and to face limb-threatening danger. Most of the patients we met in clinical practice during this period were amateurs in using electric devices and machines with little pre-occupational training, which indicates older age of injury, compared to foreign reports. Besides, the unique culture of China demands the people to forbear when facing anxiety, depression and fury instead of letting off. This could illustrate a different distribution of mechanisms of injury with less glass-punch- and suicide-related spaghetti wrist or forearm laceration in middle-aged population.

Spaghetti wrist injury, as well as forearm deep laceration, could be even more challenging during the pandemic of COVID-19 for experienced surgeons, since contact with any unidentified sample from patients might be biohazard. Safe and effective emergency management of such injuries cannot be achieved unless productive cooperation of related departments, including department of orthopedics, anesthesia, nursing, radiology and laboratory, is well established. As one of the biggest trauma centers in southeast China, our department of emergency orthopedics has two separate, but closely connected teams for preoperative consultation and postoperative care and for surgical management, respectively. Thanks to the hard work of the assistant

departments of radiology and laboratory, the results of preoperative examinations were reported within less than 3 h, which significantly eliminated time waiting for surgery ( $2.0 \pm 1.1$  in the wrist group and  $2.5 \pm 1.3$  in the forearm group), compared to 16 to 48 h reported in the relevant literature.<sup>[3,4,7]</sup> A shorter time of surgery was also observed in the two groups, compared to former works, due to not only the empirically quick reattachment of the cross-sectional anatomic structures by the orthopedists, but also the meritorious service of the anesthetists.<sup>[3,4,14]</sup> The brachial plexus anesthesia guarantees long-lasting analgesic effect which certainly relieves tendons and muscles from entrapping nerves and vessels for tension free suturing, while a tourniquet significantly decreases blood loss. To the best of our knowledge, only two studies of spaghetti wrist utilized wide-awake local-anesthesia no-tourniquet (WALANT) technique, in which the advantages of WALANT technique, including eliminated time waiting for surgery, patient-assistant recognition of anatomical structures and earlier discharge from hospital, were reported.<sup>[9,11,18]</sup> However, most patients we met were scared after injury and refused to see or know what the surgeons were doing inside the open wounds. To this extent, brachial plexus anesthesia may be a better choice. Layered identification and reattachment of severed structures is a globally admitted strategy for the repair or reconstruction for spaghetti wrist injury.<sup>[12,19]</sup> We also advocate careful documentation by photos for rehabilitation and medicolegal purposes.

Despite the sufficient teamwork and meticulous repair of the injury, we observed relatively less acceptable outcomes compared with the excellent/good rate reported in former studies. This is attributed to the increased severity of the forearm injury with at least one artery and one nerve damage and even fracture and extensor involvement.<sup>[3,4,10,13]</sup> It is a consensus that the most important prognostic factor for the functional recovery of such injury is not the number of transected tendons but the number of involved nerves. In accordance with such findings, the majority of opposition, intrinsic muscle and sensory function lay in the good level rather than the excellent level in the current study. Besides, much poorer outcomes of opposition (25.0% fair) and intrinsic muscle (25.0% fair) function were more common in the forearm group, due to a more proximal level of motor and sensory neuron injury. Decreased grip strength was observed in the forearm group compared to the wrist group, which was probably due to inflammatory peritendinous adhesion and muscle belly atrophy of disuse due to immobilization before ceasing the splint.<sup>[20-22]</sup> Luckily, all severed

arteries reached proper patency which confirmed blood supply for the distal part of the injured limb. Although average DASH score was slightly lower than expected in both groups and severe complications were seen as two patients even required arthrodesis of elbow or wrist, the overall subjective outcomes of these patients were satisfactory, since the surgical management and rehabilitation agreed with the tradition of limb salvage against amputation.

Little literature reported the indication of repair of nerve, vessels and muscle belly and the outcomes of severe proximal forearm laceration. Alluri et al.<sup>[16]</sup> proposed in their prospective study that temporization rather than excessive exploration should be the first option for proximal forearm laceration, as long as advanced ultrasonic and fluoroscopic examination reported negative results of arterial or neural injury, since tendinous injury was rare in the proximal half of the forearm. However, this algorithm may ignore the situation in which liquid or adelomorphic contamination lies in the deep and in which the advanced examinations are of no availability. In our study, all patients in the forearm group underwent surgical exploration and injury of vessels and nerves was found despite the negative results of accurate physical examination. Damage to the ulnar artery is one of the most frequently missed diagnoses as the forearm laceration, either distal or proximal, showed a radial-dominant pattern in previous and current studies.<sup>[5,16]</sup> Other studies have focused on muscle belly tear with open wound lies in the field of fractures with open reduction and internal fixation. For instance, the pronator quadratus is often torn during fracture of distal radius and no significant difference of function of the forearm pronation was concluded whether repair it or not during the surgery.<sup>[23]</sup> However, laceration of the proximal forearm muscle belly in our study was all sutured to cover the repaired vessels and nerves in case of desiccation and for potential necrosis, if the injury damaged the ambiguous blood supply of the muscle belly.<sup>[24]</sup> To the best of our knowledge, this is also the first report to compare the outcomes of lacerated wrist and proximal forearm,<sup>[25]</sup> in which incredible similarity in the aspects of demographic characteristics, such as age, sex ratio, and mechanism and side of injury, and outcomes of tendon function, intrinsic muscle function and sensory, were observed despite the fact that patients in the two groups were lacerated at different levels of the forearm. One of the possible reasons is that simultaneous artery and

nerve injury often occurs within deep wounds, which indicates multiple tendon/muscle ruptures with limb- or even life-threatening severity. Hence, severe volar forearm lacerations, either distal or proximal, should be considered as a whole for the emergency management and functional recovery. We advocate to expand the term “spaghetti wrist injury” to a broader range when simultaneous complete ruptures of artery and nerve happen, namely “spaghetti-ketchup injury”, which includes the proximal forearm lacerations with similar severity, to draw attention to its ponderance in this period when industry- and pressure-related trauma significantly increase.<sup>[25]</sup>

This study has certain limitations. First, the sample size of this retrospective study was rather small, which might not properly reveal the similarity or difference between proximal volar forearm laceration and spaghetti wrist injury. Second, patients with burn injury, degloving injury and large skin and soft tissue defect were not included in this study to simplify the comparison of management and outcomes between the two groups. Further study can try to bring these types of injury into consideration, although they were not described in the definition of Spaghetti wrist before.

In conclusion, after much consideration of demographic patterns, characteristics of injuries and outcomes, we reached a conclusion which proposes merging the severe wrist and proximal forearm laceration of multiple tendons/muscles with at least one major artery and one major nerve as a whole, namely the spaghetti-ketchup injury, since the laceration of wrist and that of proximal forearm in this study share similar mechanisms and outcomes after primary repair or reconstruction with proper rehabilitation except for a longer surgical time of the latter. It is a surgeon’s duty to strive for primary repair of such injury and to provide gradual rehabilitation program postoperatively for better outcomes. Besides, what the society can offer for healthcare of spaghetti-ketchup injury lies in production safety improvement and guiding emotion control of the depressed.

**Ethics Committee Approval:** Ethical approval of the study was obtained from Institutional Ethics Committee of Shanghai Sixth People’s Hospital (2021-KY-113(K)). The study was conducted in accordance with the principles of the Declaration of Helsinki.

**Patient Consent for Publication:** A written informed consent was obtained from each patient.

**Data Sharing Statement:** The data that support the findings of this study are available from the corresponding author upon reasonable request.

**Author Contributions:** Manuscript drafting; F.W., R.Z.; Data collection: S.L.; Data analysis: H.R.; Study design: J.X., Q.K.

**Conflict of Interest:** The authors declared no conflicts of interest with respect to the authorship and/or publication of this article.

**Funding:** Received financial support from National Natural Science Foundation of China (No. 82072421) and Natural Science Foundation of Shanghai (No.20ZR1442200).

## REFERENCES

- Haucke M, Heinz A, Liu S, Heinz S. The Impact of COVID-19 lockdown on daily activities, cognitions, and stress in a lonely and distressed population: Temporal dynamic network analysis. *J Med Internet Res* 2022;24:e32598.
- Das De S, Liang ZC, Cheah AE, Puhaindran ME, Lee EY, Lim AYT, et al. Emergency hand and reconstructive microsurgery in the COVID-19-positive patient. *J Hand Surg Am* 2020;45:869-75.
- Stefanou N, Kontogeorgakos V, Varitimidis S, Malizos KN, Dailiana Z. Spaghetti wrist: Transverse injury, axial incision, layered microsurgical reconstruction. *Injury* 2021;52:3616-23.
- Demirdover C, Ozturk FA, Yazgan HS, Yogurtcu N, Sevindik M, Vayvada H. Surgical treatment and functional outcomes of multicomponent soft tissue injuries of the wrist. *Hand Surg Rehabil* 2018;37:160-6.
- Gibson TW, Schnall SB, Ashley EM, Stevanovic M. Accuracy of the preoperative examination in Zone 5 wrist lacerations. *Clin Orthop Relat Res* 1999;(365):104-10.
- Boynuyogun E, Ozdemir DM, Firat T, Uzun H, Aksu AE. Combined nerve, vessel, and tendon injuries of the volar wrist: Multidisciplinary treatment and functional outcomes. *Hand Surg Rehabil* 2021;40:729-36.
- Yildirim A, Nas K. Evaluation of postoperative early mobilization in patients with repaired flexor tendons of the wrist, the spaghetti wrist. *J Back Musculoskelet Rehabil* 2010;23:193-200.
- Widgerow AD. Full-house/spaghetti wrist injuries. Analysis of results. *S Afr J Surg* 1990;28:6-10.
- Prasetyono TOH, Tunjung N. Long-term follow-up of full-awake hand surgery in major flexor tendon injury of the hand and forearm. *Ann Plast Surg* 2019;83:163-8.
- Noaman HH. Management and functional outcomes of combined injuries of flexor tendons, nerves, and vessels at the wrist. *Microsurgery* 2007;27:536-43.
- Arik HO, Coskun T, Kose O. Management of spaghetti wrist under WALANT technique. *Hand Surg Rehabil* 2021;40:655-9.
- Geoghegan L, Nikkhah D. The 'outside to inwards' approach in the spaghetti wrist. *Ann Med Surg (Lond)* 2020;56:5-6.
- Puckett CL, Meyer VH. Results of treatment of extensive volar wrist lacerations: The spaghetti wrist. *Plast Reconstr Surg* 1985;75:714-21.
- Yazdanshenas H, Naeeni AF, Ashouri A, Washington ER 3rd, Shamie AN, Azari K. Treatment and postsurgery functional outcome of spaghetti wrist. *J Hand Microsurg* 2016;8:127-33.
- Koshy K, Prakash R, Luckiewicz A, Alamouti R, Nikkhah D. An extensive volar forearm laceration - the spaghetti wrist: A systematic review. *JPRAS Open* 2018;18:1-17.
- Alluri RK, Vakhshori V, Hill R, Azad A, Ghiassi A, Stevanovic M. A diagnostic algorithm to guide operative intervention of zone 5 flexor injuries. *HSS J* 2022;18:57-62.
- Hudak PL, Amadio PC, Bombardier C. Development of an upper extremity outcome measure: The DASH (disabilities of the arm, shoulder and hand) [corrected]. The Upper Extremity Collaborative Group (UECG). *Am J Ind Med* 1996;29:602-8.
- Prasetyono TOH. FAHS (Full-Awake Hand Surgery) for major flexor tendon injury. *Ann Plast Surg* 2020;85:202-3.
- Meals CG, Chang J. Ten tips to simplify the spaghetti wrist. *Plast Reconstr Surg Glob Open* 2018;6:e1971.
- Wang S, Lu M, Wang W, Yu S, Yu R, Cai C, et al. Macrophage polarization modulated by NF- $\kappa$ B in polylactide membranes-treated peritendinous adhesion. *Small* 2022;18:e2104112.
- Cai C, Wang W, Liang J, Li Y, Lu M, Cui W, et al. MMP-2 responsive unidirectional hydrogel-electrospun patch loading TGF- $\beta$ 1 siRNA polyplexes for peritendinous anti-adhesion. *Adv Funct Mater* 2021;31:2008364.
- Cai C, Zhang X, Li Y, Liu X, Wang S, Lu M, et al. Self-healing hydrogel embodied with macrophage-regulation and responsive-gene-silencing properties for synergistic prevention of peritendinous adhesion. *Adv Mater* 2022;34:e2106564.
- Shi F, Ren L. Is pronator quadratus repair necessary to improve outcomes after volar plate fixation of distal radius fractures? A systematic review and meta-analysis. *Orthop Traumatol Surg Res* 2020;106:1627-35.
- Wang C, Xu J, Wen G, Chai Y. Reconstruction of complex tissue defect of forearm with a chimeric flap composed of a sural neurocutaneous flap and a vascularized fibular graft: A case report. *Microsurgery* 2018;38:790-4.
- Atik OŞ. What are the expectations of an editor from a scientific article? *Jt Dis Relat Surg* 2020;31:597-8.