












# Vitamin B<sub>12</sub> reduces the negative effects of nicotine on fetal bone development in the rats

Ahmet Payas, Lect.,<sup>1</sup>, Yakup Ekinci, MD<sup>2</sup>, Kaan Gürbüz, MD<sup>2</sup>, Sabri Batın, MD<sup>2</sup>, Tolga Ertekin, PhD<sup>3</sup>, Kadirhan Doğan, Lect.,<sup>4</sup>, Hatice Güler, PhD<sup>5</sup>, Özge Al, PhD<sup>5</sup>, Halil Yılmaz, PhD<sup>6</sup>, Mehtap Nisari, PhD<sup>5</sup>

<sup>1</sup>Hitit University, Vocational College of Sungurlu, Çorum, Turkey

<sup>2</sup>Department of Orthopedics and Traumatology, Kayseri City Education and Training Hospital, Kayseri, Turkey

<sup>3</sup>Department of Anatomy, Afyonkarahisar Health Science University, Faculty of Medicine, Afyonkarahisar, Turkey

<sup>4</sup>Kapadokya University, College of Health Sciences, Nevşehir, Turkey

<sup>5</sup>Department of Anatomy, Erciyes University, Faculty of Medicine, Kayseri, Turkey

<sup>6</sup>Nevşehir Hacı Bektaş Veli University, Kozaklı Vocational School, Nevşehir, Turkey

Although it is known to be very harmful for human health, the rate of smoking is quite high all over the world.<sup>[1,2]</sup> Nicotine, which is the main addictive component of tobacco, contains 0.6 to 2 mg in a single cigarette.<sup>[3,4]</sup> Since nicotine ingested through active or passive smoking is a compound that can pass through the placenta and mix with the fetal circulation, it can cause growth retardation, birth anomalies (limb shortening, cleft palate and lip, gastroschisis, etc.), and even mortality.<sup>[5-8]</sup>

With nicotine stimulation of catecholamine release, it causes vasoconstriction in the vessels leading to the uterus and placenta. As a result of the decrease in blood

## ABSTRACT

**Objectives:** The aim of this experimental rat study was to investigate the effectiveness of vitamin B<sub>12</sub> (Vit-B<sub>12</sub>) against the teratogenic effects of nicotine use during pregnancy in the fetus.

**Materials and methods:** Eighteen Wistar-Albino pregnant rats were divided into six groups (n=3, each) as Group 1 (control), Group 2 (Vit-B<sub>12</sub>), Group 3 (nicotine 3 mg/kg/day), Group 4 (nicotine 3 mg/kg/day + Vit-B<sub>12</sub>), Group 5 (nicotine 6 mg/kg/day) and Group 6 (nicotine 6 mg/kg/day + Vit-B<sub>12</sub>). Nicotine was administered subcutaneously and Vit-B<sub>12</sub> was administered intraperitoneally for 20 days. The skeletal systems of the embryos were stained using the double-staining method. The total bone length (TBL), the length of the ossified part, and the ossification rate were calculated using the ImageJ program. In addition, the weight and crown-rump length (CRL) of the embryos were measured and recorded.

**Results:** Clinical shock effect was observed in all rats administered nicotine. A significant decrease in weight, CRL, and TBL was measured in Group 3 (p=0.0081) and, particularly in Group 5 (p=0.026), which were given only nicotine, compared to other groups. In the morphometric measurements of Group 4 and Group 6 to which Vit-B<sub>12</sub> was added, values close to the control group were measured (p=0.173). The data of Group 6 were statistically significantly larger than Group 5 (p=0.007), while it was statistically smaller than Group 1 (p=0.0038).

**Conclusion:** Nicotine use negatively affects the morphological development of the embryo. On the other hand, Vit-B<sub>12</sub> provides benefits in reducing these negative effects.

**Keywords:** Bone length, embryonic development, nicotine, teratogenic, vitamin B<sub>12</sub>.

Received: January 11, 2022

Accepted: February 24, 2022

Published online: March 28, 2022

**Correspondence:** Yakup Ekinci, MD, Kayseri Şehir Eğitim ve Araştırma Hastanesi, Ortopedi ve Travmatoloji Kliniği, 38080 Kocasinan, Kayseri, Türkiye.

E-mail: belduya@gmail.com

Doi: 10.52312/jdrs.2022.552

**Citation:** Payas A, Ekinci Y, Gürbüz K, Batın S, Ertekin T, Doğan K, et al. Vitamin B<sub>12</sub> reduces the negative effects of nicotine on fetal bone development in the rats. Jt Dis Relat Surg 2022;33(1):216-224.

©2022 All right reserved by the Turkish Joint Diseases Foundation

This is an open access article under the terms of the Creative Commons Attribution-NonCommercial License, which permits use, distribution and reproduction in any medium, provided the original work is properly cited and is not used for commercial purposes (<http://creativecommons.org/licenses/by-nc/4.0/>).

flow to the uterus and placenta, a decrease in fetal nutrition and oxygenation occurs. Nicotine, passing through the placenta, mixes with the amniotic fluid

in the fetal circulation and is absorbed by the fetus's skin and passes to the fetus.<sup>[9,10]</sup> Nicotine suppresses osteoblast activity and stimulates osteoclast activity, causing an increase in bone destruction. In addition, as nicotine prevents the re-synthesis and tissue migration of structures such as fibroblasts and macrophages, it causes scar tissue formation. Nicotine restricts ossification by decreasing the storage of vitamin D, which is important for bone development, and by increasing the level of homocysteine.<sup>[11,12]</sup> It is also reported that nicotine oxidant-antioxidant causes harm by disrupting the grinder and antioxidants are beneficial against these damages.<sup>[3]</sup>

Vitamin B<sub>12</sub> (Vit-B<sub>12</sub>), a water-soluble vitamin synthesized by microorganisms, takes part in two enzymatic reactions that are extremely important for the organism.<sup>[13]</sup> One of these is conversion reaction of homocysteine to methionine, while the other is the reaction of methylmalonyl CoA to convert succinyl to CoA. In vitamin B<sub>12</sub> deficiency, increased homocysteine causes many diseases such as birth defects, pregnancy complications, cognitive deficiencies, cardiovascular, peripheral vascular and osteoporosis. In addition, the increase in homocysteine level disrupts the collagen structure of the organic matrix of bone tissue, which causes the precipitation of low-level minerals. Affected bone mineral density (BMD) causes osteoporosis. In recent studies, it has been also found that homocysteine level suppresses osteoblast activity and negatively affects ossification by stimulating osteoclast activity. Increasing methylmalonyl CoA has a toxic effect on structures such as the central nervous system, kidney and bone marrow.<sup>[13,14]</sup>

In the literature, there are studies reporting that Vit-B<sub>12</sub>, which is a powerful antioxidant and plays an important role in growth and bone development, has a protective effect against the toxic effects of nicotine.<sup>[9,15]</sup> However, there is no study showing the teratogenic effect of this effect on fetal bone development. The aim of this study was to examine the bone damage in rats exposed to nicotine at different doses during pregnancy and the protective effects of Vit-B<sub>12</sub> against nicotine using a double-staining method.

## MATERIALS AND METHODS

This study was approved by the decision of the Erciyes University Medical Animal Experiments Ethics Committee (Date: 09/12/2015, No: 15/152) and conducted in accordance with the Turkish Law 6343/2, Veterinary Medicine Deontology Regulation 6.7.26, and the Helsinki Declaration of Animal Rights.

In this study, Wistar-Albino female rats which were maintained in individual cages at a constant temperature of 23±2°C with a 14/10-hour light-dark cycle and fed standard pellet diet and tap water were used. Power analysis was conducted to calculate the number of Wistar-Albino rats involved which was  $p=0.88$  for min 27 subjects in each group. The mean number of fetuses in a pregnant rat is 9.4±0.8. 18 female rats (weight 150 to 180 g) were randomly assigned to nine cages with one male for mating at 17:00 P.M. Each female subject was taken under vaginal smear test at 07:00 A.M. next morning. Female subjects with sperm remnants on vaginal smear were considered to be pregnant. A total of subjects were, then, assigned to six groups with block randomization.

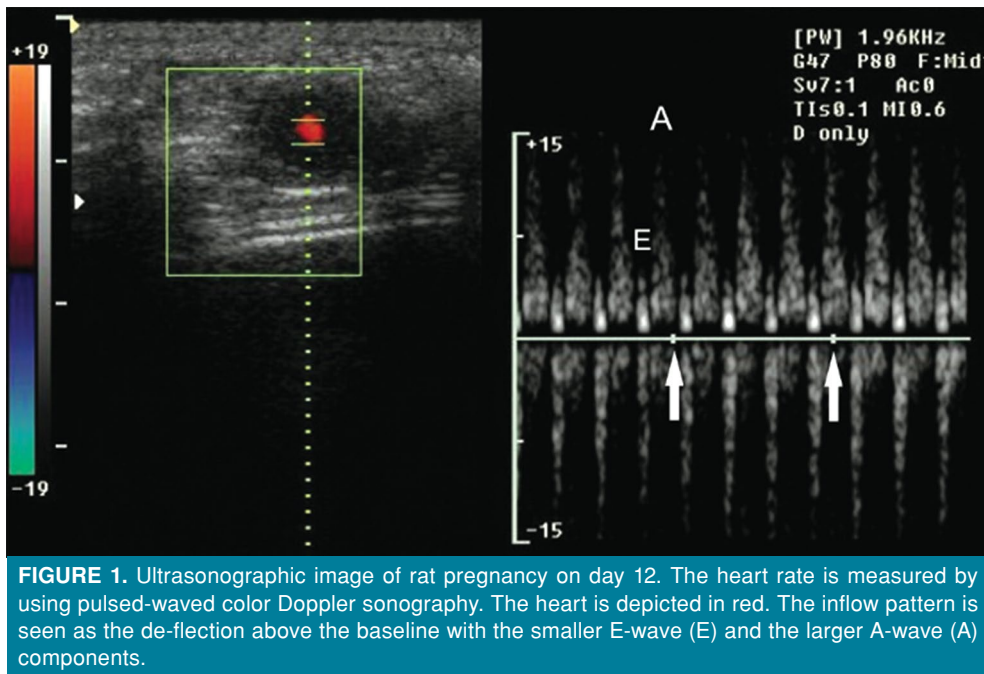
On Day 12, the rats were placed in dorsal recumbency under general anesthesia (2% sevoflurane in oxygen). The abdominal area was clipped, and ultrasound scanning gel was applied to the tip of the probe. They were examined with transabdominal real-time ultrasonography by using a 12-MHz linear transducer and pulsed-waved color Doppler sonography (HDI 1500, Philips™, Netherlands) to recognize the embryonic heart rate (Figure 1). During the examination, rectal temperature and heart rate were monitored (Vet Ox 4700 Plus™, SDI, USA). Body temperature remained between 36 and 37°C and the heart rate between 310 and 340 bpm. Scanning progressed from right to left, with the probe oriented perpendicular to the abdominal wall in a sagittal plane, starting at the right inguinal region and rotated, if needed, to the axial plane at the level of the caudal abdomen. Upon detection of evidence of pregnancy, the examination proceeded cranially along the course of the uterine horn to realize the number of fetuses which was nine to 11 for each pregnant rat in each group.

Group 1: Saline Solution (Merck™- NIST® SRM® 975a) applied intraperitoneally 1 mL/kg/day at 05:00 P.M. in each every day for 20 days.

Group 2: Vit-B<sub>12</sub> (Sigma-Aldrich™ Lot: V2876-25G) applied intraperitoneally 0.5 mg/kg/day at 05:00 P.M. in each every day for 20 days.

Group 3: Nicotine (Merck™ Lot: M820877.0025) applied subcutaneously 3 mg/kg/day at 04.30 P.M. in each every day for 20 days.

Group 4: Nicotine (Merck™ Lot: M820877.0025) applied subcutaneously 3 mg/kg/day at 04:30 P.M. in each every day for 20 days and half an hour after nicotine implementation Vit-B<sub>12</sub> (Sigma-Aldrich™ Lot: V2876-25G) applied intraperitoneally 0.5 mg/kg/day at 17:00 P.M. in each every day for 20 days.



**FIGURE 1.** Ultrasonographic image of rat pregnancy on day 12. The heart rate is measured by using pulsed-waved color Doppler sonography. The heart is depicted in red. The inflow pattern is seen as the de-flexion above the baseline with the smaller E-wave (E) and the larger A-wave (A) components.

Group 5: Nicotine (Merck™ Lot: M820877.0025) applied subcutaneously 3 mg/kg/day with 2×1 posology at 07:00 A.M. and 04:30 P.M. in each every day for 20 days.

Group 6: Nicotine (Merck™ Lot: M820877.0025) applied subcutaneously 3 mg/kg/day with 2×1 posology at 07:00 A.M. and 04:30 P.M. in each every day for 20 days and half an hour after the second dosage of nicotine implementation Vit-B<sub>12</sub> (Sigma-Aldrich™ Lot: V2876-25G) applied intraperitoneally 0.5 mg/kg/day at 05:00 P.M. in each every day for 20 days.

On Day 21, all pregnant rats were sedated with 6 to 8 mg/kg xylazine (Rompun 2% solution, 50 mL vial, Bayer-Turk™ Ilac Ltd., Istanbul, Turkey) and 60 to 80 mg/kg ketamine (Ketalar 50 mg/mL 10 mL vial, Pfizer™ Ilaclar Ltd., Istanbul, Turkey), and subsequently sacrificed via cervical dislocation.

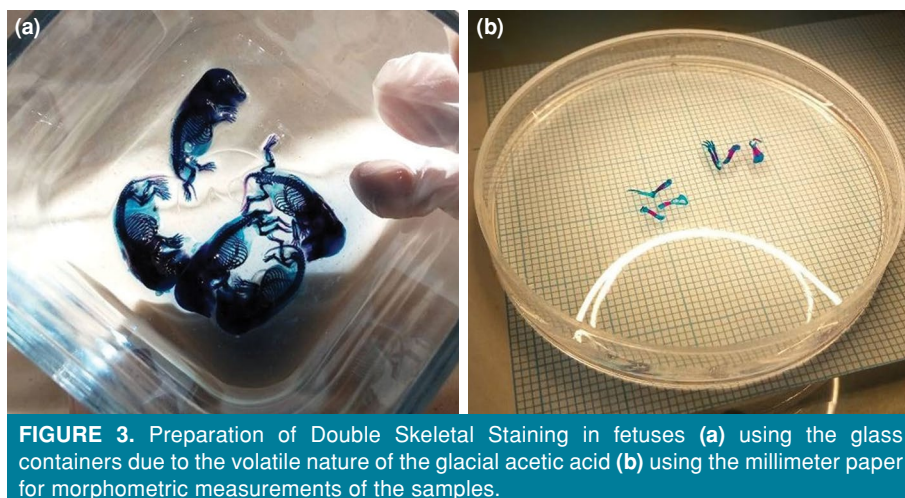
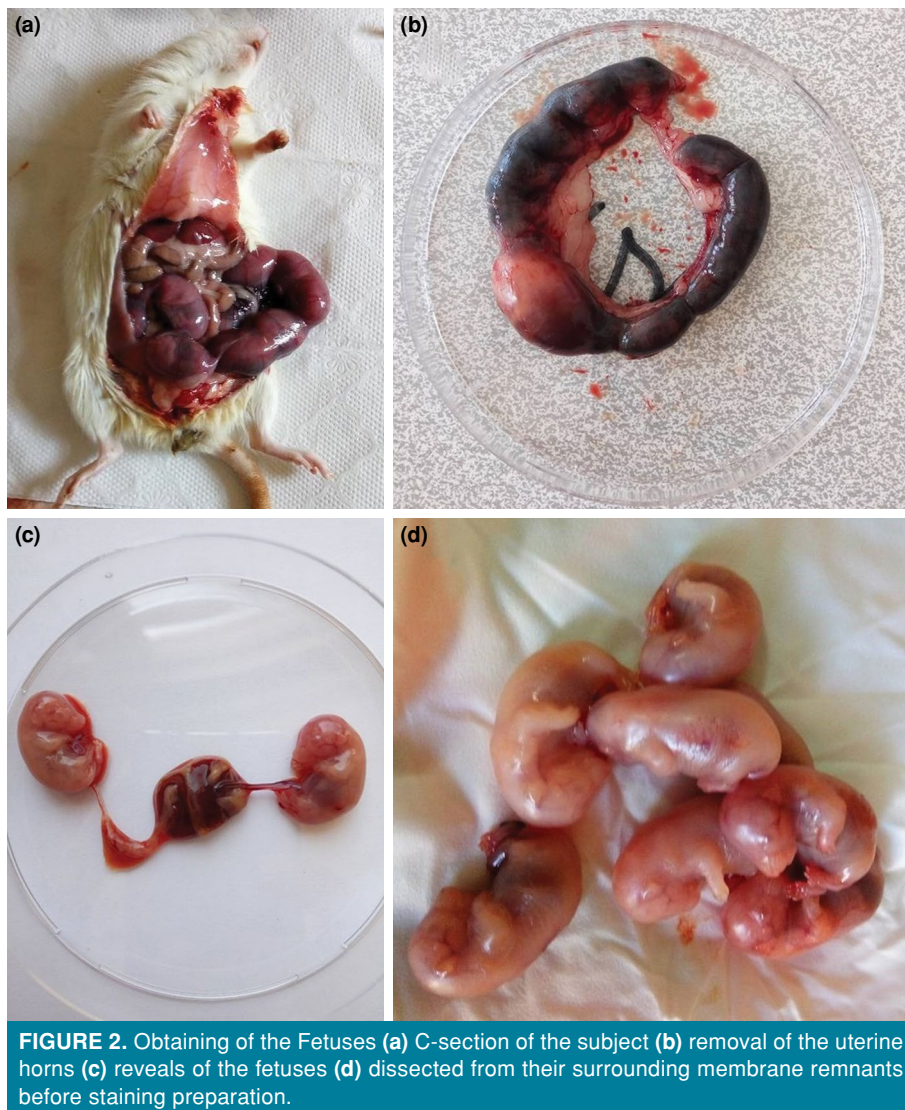
#### Procedures on the preparation of double skeletal staining in fetuses

Laparotomy was used to access the abdomen and remove the uterine horns. The uterine horns were placed in a glass of normal saline and the anti-mesometrial border of the uterine horns was incised to disclose the embryos (experimental units). The embryo's surrounding membranes were removed using a dissecting microscope and fine forceps (Figure 2). In none of the rats, embryonic resorption sites (failed pregnancies) were recorded. Then,

they were placed in 70% ethyl alcohol to provide dehydration. After waiting for seven days, the fluid contained in the fetus was drawn. Then, it was kept in pure acetone for three days to remove the fat of the fetus. The dye solution was prepared according to Inouye's double skeleton painting method. Due to the volatile nature of the glacial acetic acid in the dyeing solution, the glass containers were used (Figure 3).<sup>[16]</sup> Then, prepared glass containers were placed in an oven set at 40°C and kept for seven days, and the tissues were stained. Fetuses were, then, washed with running tap water for 2 h. After this process, the transparency phase was started. Fetuses stained during the transparency phase were kept in mixtures of: one day 1% KOH, five days 80 mL 1% KOH and 20 mL 20% glycerin, five days 50 mL 1% KOH and 50 mL 50% glycerin, five days 20 mL 1% of KOH and 80 mL of 80% glycerin. After the transparency phase, the fetuses were stored in 100% pure glycerin.

#### Morphometric measurements

The scapula bone length was measured as the distance between the trigonum spinae and the cavitas glenoidalis. Also, the bone length measurement of the humerus, ulna, and radius was measured as the distance between the distal and proximal endpoints of each bone. All ossification length measurements of each bone were carried out by taking the distance between the endpoints of each bone's ossifying regions.



To make morphometric measurements, after the anterior extremities of the fetus were carefully separated, photographs were taken on millimeter paper with a Nikon™ E5700 camera (2×10 magnification) (Figure 4). Measurements included extremity lengths, length of the ossified regions, and percentage of ossification were measured using non-profit commercially available “Image Processing and Analysis in Java” (<https://imagej.nih.gov/ij/index.html>) program.

Intra- and inter-observer reliability were evaluated based on morphometric measurements from all subjects repeated twice with an interval of one month by two orthopedic and two anatomy specialists with 10 years of professional experience. A two-way mixed effects model and intraclass correlation coefficients (ICC) were used to evaluate agreement and differences between intra- and inter-observer measurements. In this study, ICC values less than 0.5 were considered to have poor reliability, values between 0.5 and 0.75 had moderate reliability, values between 0.75 and 0.9 had good reliability, and values greater than 0.90 had excellent reliability.<sup>[17]</sup>

#### Statistical analysis

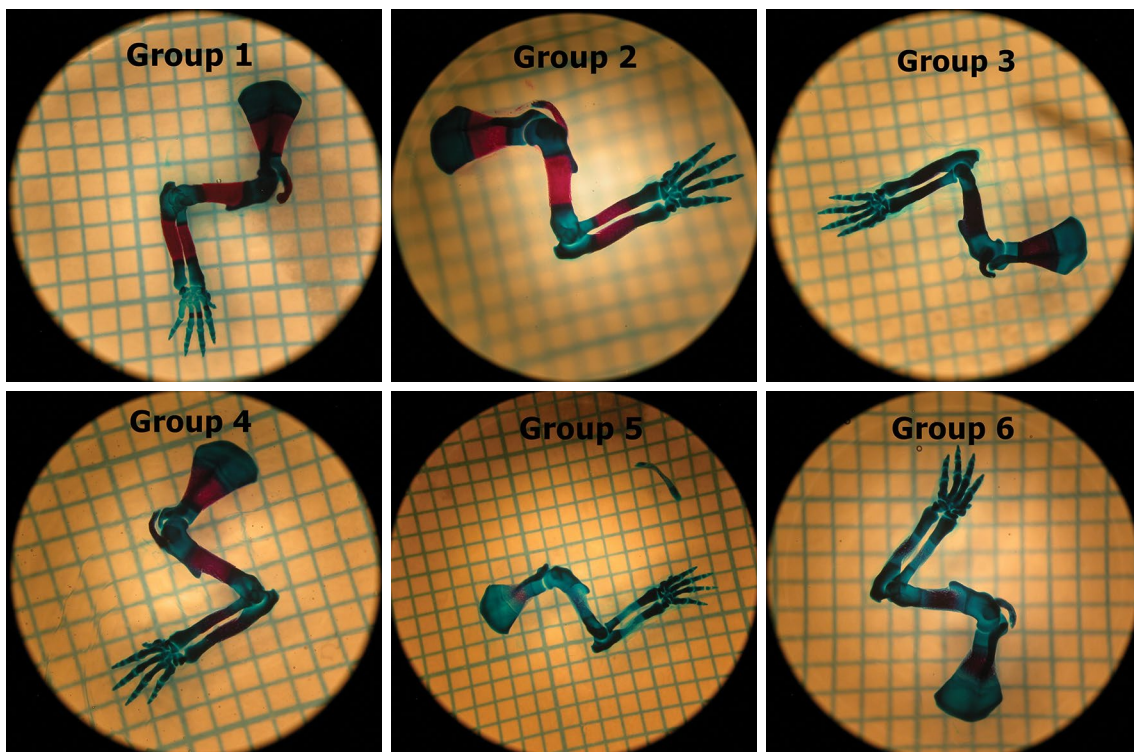
Statistical analysis was performed using the IBM SPSS version 23.0 software (IBM Corp.,

Armonk, NY, USA). The Kolmogorov-Smirnov test was used to ensure that all variables were normal. The data were described in mean ± standard deviation (SD), median (min-max) or number and frequency, where applicable. The Pearson chi-square test was used for univariate analysis. One-way analysis of variance (ANOVA) was used to compare the results between groups. A *p* value of < 0.05 was considered statistically significant.

#### RESULTS

The first clinically observed finding in rats after nicotine application was the shock effect. After the shock effect, for 1-min, severe tonic-clonic convulsions and hyperextension contractions in the torso were observed. Subsequently, the sedative phase was observed and lasted for 2 to 3 min. It was documented that on Day 5 of the nicotine application, the convulsion time decreased markedly.

Morphometric measurement results were presented in Table I with respect to scapula, ulna, radius, and humerus. In Group 3 and Group 5, which were given only nicotine, total bone length, length of ossified part, and ossification rate were also measured lower in all bones compared to other groups. This difference was statistically significant in



**FIGURE 4.** Morphometric measurements of upper extremity on millimeter paper under 2×10 magnification.

**TABLE I**  
**Morphometric results of bones**

	Group 1 (n=29)		Group 2 (n=30)		Group 3 (n=31)		Group 4 (n=28)		Group 5 (n=31)		Group 6 (n=29)	
	Mean±SD	Min-Max	Mean±SD	Min-Max	Mean±SD	Min-Max	Mean±SD	Min-Max	Mean±SD	Min-Max	Mean±SD	Min-Max
<b>Radius</b>												
TBL (mm)	3.2±0.1	2.78-3.43	3.2±0.1	2.86-3.49	3.1±0.1 <sup>sd</sup>	2.71-3.41	3.2±0.1	2.92-3.47	3.1±0.2 <sup>sd</sup>	2.71-3.33	3.1±0.1	2.88-3.49
LOP (mm)	1.4±0.2	0.93-1.64	1.3±0.2	0.93-1.62	1.2±0.1 <sup>ab,d</sup>	0.79-1.42	1.3±0.1	0.88-1.55	0.6±0.4 <sup>ab,c,d,e</sup>	0-1.13	1.2±0.2	0.76-1.55
OR (%)	40.0±7.2	26.45-56.23	40.1±5.5	30.14-48.22	32.6±6.9 <sup>ab,d</sup>	16.73-43.58	40.1±5.1	27.71-49.2	17.6±12.9 <sup>ab,c,d,e</sup>	0-44.67	37.3±7.2	25.54-54.4
<b>Ulna</b>												
TBL (mm)	4.2±0.2	3.7-4.59	4.2±0.1	3.94-4.51	4.1±0.2	3.37-4.53	4.2±0.2	3.35-4.6	4.1±0.1 <sup>sd</sup>	3.78-4.29	4.1±0.2	3.55-4.68
LOP (mm)	1.5±0.2	1.23-1.86	1.5±0.1	1.34-1.75	1.3±0.1 <sup>ab,d</sup>	1.00-1.55	1.5±0.2	1.12-1.85	0.7±0.5 <sup>ab,c,d,e</sup>	0-1.87	1.4±0.2	1.11-1.87
OR (%)	34.6±3.4	28.87-39.49	35.3±4.5	27.33-47.52	26.1±6.4 <sup>ab,d</sup>	11.0-38.28	32.7±4.2	21.65-38.3	14.5±9.8 <sup>ab,c,d,e</sup>	0-32.9	31.5±4.3	26.43-40.8
<b>Humerus</b>												
TBL (mm)	4.4±0.2	4.06-4.7	4.3±0.2	3.9-4.77	4.1±0.2 <sup>sd</sup>	3.72-4.36	4.3±0.2	3.88-4.49	4.1±0.2 <sup>ab,d</sup>	3.65-4.42	4.2±0.2	3.86-4.62
LOP (mm)	1.8±0.1	1.66-2.01	1.8±0.2	1.41-2.11	1.5±0.1 <sup>ab,d</sup>	1.12-1.66	1.7±0.2 <sup>sd</sup>	1.41-2.0	0.9±0.4 <sup>ab,c,d,e</sup>	0-1.45	1.6±0.1 <sup>sd</sup>	1.36-1.91
OR (%)	38.0±3.4	31.79-46.41	39.1±6.6	24.9-56.44	34.5±4.2 <sup>ab,d</sup>	24.83-42.3	38.1±4.4	28.4-42.27	18.3±8.8 <sup>ab,c,d,e</sup>	0-2.43	35.9±4.5	27.47-49.35
<b>Scapula</b>												
TBL (mm)	3.3±0.1	3.09-3.6	3.3±0.1	3.08-3.59	3.2±0.1 <sup>sd</sup>	2.89-3.38	3.3±0.1	3.0-3.6	3.1±0.2 <sup>ab,d</sup>	2.75-3.48	3.2±0.2	2.79-3.62
LOP (mm)	1.7±0.1	1.46-1.95	1.6±0.1	1.48-1.75	1.4±0.1 <sup>ab,c,d</sup>	1.1-1.58	1.6±0.1	1.33-1.89	0.8±0.3 <sup>ab,c,d,e</sup>	0.3-1.27	1.6±0.1	1.22-1.74
OR (%)	45.7±4.6	38.7-55.45	46.4±4.8	38.82-54.66	37.6±3.6 <sup>ab,c,d</sup>	29.53-45.93	44.2±1.6	34.0-53.28	18.8±8.3 <sup>ab,c,d,e</sup>	0.99-30.28	41.3±4.0 <sup>sd</sup>	31.07-49.74

SD: Standard deviation; TBL: Total bone length; LOP: Length of ossified part; OR: Ossification rate; ANOVA test; p<0.05 was considered statistically significant; a: Significantly smaller compared to the Group 1; b: Significant when compared with Group 4; c: Significant when compared with Group 6; d: Significantly smaller compared to Group 2; e: Significantly smaller compared to Group 3.

**TABLE II**  
Data of fetus groups

	Group 1 (n=29)	Group 2 (n=30)	Group 3 (n=31)	Group 4 (n=28)	Group 5 (n=31)	Group 6 (n=29)
	Mean±SD	Mean±SD	Mean±SD	Mean±SD	Mean±SD	Mean±SD
Weight (g)	2.6±0.1	2.5±0.1	2.3±0.2 <sup>a,d</sup>	2.4±0.2	2.1±0.2 <sup>a,c,d,e</sup>	2.3±0.2 <sup>a,d</sup>
CRL (mm)	30.0±1.2	29.9±1.0	28.5±1.2 <sup>a,d</sup>	29.4±1.2	26.1±2.1 <sup>a,b,c,d,e</sup>	27.9±1.7 <sup>a</sup>

SD: Standard deviation; CRL: The crown-rump length; Tamhane's T2  $p < 0.05$  was considered statistically significant; a: Significantly smaller compared to the Group 1; b: Significant when compared with Group 4; c: Significant when compared with the Group 6; d: Significantly smaller compared to the Group 2; e: Significantly smaller compared to the Group 3.

total bone length measurements in Group 3, compared to the other groups except for Group 4 ( $p=0.0081$ ). A statistically significant decrease was measured in Group 5, compared to all groups ( $p=0.026$ ) (Table I).

In Groups 4 and 6, which received Vit-B<sub>12</sub> in addition to the nicotine group, it was lower than the control group, but this difference was not statistically significant while measuring close values ( $p=0.173$ ). Moreover, there was no statistically significant difference between the length of ossification and the percentage of ossification of the scapula, humerus, ulna, radius bones in Group 2 and Group 1 ( $p=0.18$ ).

The crown-rump length (CRL) and weight of fetuses were found to be statistically decreased in Group 3 and Group 5, compared to the Group 1 ( $p=0.023$ ). There was no statistically significant difference in the head-rump length and weight values of the fetuses between Group 4 with Group 2 ( $p=0.34$ ). The data of the Group 6 were statistically larger than Group 5 ( $p=0.007$ ), while it was statistically smaller than Group 1 ( $p=0.0038$ ) (Table II).

Intra- and inter-observer reliability of morphometric measurement results were determined to be excellent (ICC: 0.971-0.984) and good (ICC: 0.860-0.995), respectively.

## DISCUSSION

The main finding of the study is that Vit-B<sub>12</sub> has many important functions for livings and is a powerful antioxidant, and although it has many harmful effects for the body, it has a protective effect against the teratogenic effect of nicotine, which is one of the main components of cigarettes used by many individuals in all age groups.<sup>[18]</sup>

For smokers, the daily nicotine consumption ranges between 10.5 and 78.6 mg, with 90% of the nicotine being taken by inhalation. The nicotine intake of a 60 kg female would range between 0.16 and 1.18 mg/kg body weight per day, depending on her age and sex.<sup>[19]</sup> To analyze the effects of nicotine

taken during pregnancy, the nicotine dose varies in studies. In this study, doses of 3 mg/kg/day and 6 mg/kg/day, which are in the intake range of heavy smokers, were preferred to see the teratogenic effects more optimally. Demographic data in the study are compatible with the literature.<sup>[3,20]</sup>

Yilmaz et al.<sup>[3]</sup> evaluated the femur, tibia, fibula, humerus, radius and ulna bones in their experimental study on fetuses of pregnant rats, and reported that there was a significant decrease in bone length and ossification center measurements, which were not significant in fetuses of nicotine administered rats. While the rate of complete ossification was quite low in rats given low-dose nicotine, the rate of no ossification was reported to be the same as in other groups. Ossification was not observed in almost all of those given high-dose nicotine. In addition, this study showed that all limb bones were affected in a similar pattern.

In our study, although shortness of bone length was observed in rats given nicotine, it was not a significant shortening. The fact that the ratio of bone length is affected even in the acute period shows that these measurements would be more meaningful in long-term follow-ups.

In their studies, Kurtoglu et al.<sup>[19]</sup> and Koklu et al.<sup>[21]</sup> reported that, in addition to birth weight and femur length, BMD rates were lower in the nicotine given group. Horta et al.,<sup>[22]</sup> in their study of 5,166 live births in Brazil, reported that the children of mothers who smoked during pregnancy had 142 g lower birth weight than mothers who did not smoke. In our study, the low birth weights draw attention in line with the literature.

Zhao and Reece,<sup>[11]</sup> in their study, showed the teratogenic effect of nicotine on CRL by its pathways. In this study, they found that nicotine led to a decrease in CRL. Similarly, in our study, it was found that nicotine had a negative effect on CRL. Sellerand Bnait,<sup>[23]</sup> in their study, reported that when fetuses were exposed to nicotine for

17 days, fetal body weight and the number of skeletal ossification centers decreased after Day 18. Carmines et al.<sup>[24]</sup> reported a significant increase in the number of non-ossified bones in the offspring of female rats exposed to cigarette smoke two weeks before and for 20 days during pregnancy.

In the current study, we observed that nicotine had a significant negative effect on ossification rates in accordance with the literature. In addition, one of the important findings in our study is the acute effect of nicotine on the living things. It has been observed that nicotine causes a convulsion-like effect in the acute phase in rats. This can be considered as another harm of nicotine that has not been mentioned in other studies. Researchers have been studying the preventive impact of natural or synthetic antioxidants against nicotine in recent years, and their findings have been encouraging. Of note, Vit-B<sub>12</sub> is a type of vitamin with powerful antioxidant properties. The Vit-B<sub>12</sub> deoxyribonucleic acid (DNA) synthesis and maternal health during pregnancy are important for the normal development and growth of the fetus.<sup>[25]</sup> De Martinis et al.<sup>[26,27]</sup> reported in their studies that Vit-B<sub>12</sub> played an important role in both homocysteine metabolism and bone turnover, and also affected bone cell function through osteoblasts by directly and indirectly affecting the bone.

One of the toxic effects of nicotine is on the pancreas. Bhattacharjee et al.<sup>[15,28]</sup> used 0.63 mg/kg Vit-B<sub>12</sub> to examine at the protective role of Vit-B<sub>12</sub> against the effect of Vit-B<sub>12</sub> on the adult endocrine pancreas and reported that Vit-B<sub>12</sub> provided a significant protection against nicotine-induced toxicity in pancreatic islets. However, additional studies are needed to elucidate the toxicological effects and mechanism of nicotine-induced mitochondrial dysfunction. The aforementioned authors, in their experimental study conducted with 20 rats, reported that as a result of the effect of nicotine on enzymatic pathways, it changed islet cell mitochondrial redox status and apoptotic mechanism, and reversed mitochondrial changes with Vit-B<sub>12</sub> supplementation.<sup>[29]</sup> Merriman et al.,<sup>[30]</sup> when they compared 9,506 cases with pernicious anemia due to Vit-B<sub>12</sub> deficiency with healthy individuals, concluded that the risk of osteoporotic hip fracture was higher. Roman-Garcia et al.<sup>[31]</sup> investigated the role of Vit-B<sub>12</sub> on growth and bone mass of rat pups and showed that Vit-B<sub>12</sub> deficiency resulted in severe growth retardation and osteoporosis. In our study, in accordance with the literature, we observed that Vit-B<sub>12</sub> partially neutralized the negative effects of nicotine on upper extremities.

Although this current *ex-vivo* study was conducted with a sufficient and competent number of subjects according to the power analysis, the first limitation of the present study is that the two factors nicotine and Vit-B<sub>12</sub> used in the intervention could not be measured numerically and objectively in each subject of placenta-fetus transition. Another limitation is that the subjects were their first pregnancies and had a relatively early caesarean section (average natural gestation period of 23 to 24 days). Another limitation is application type and dosage. Clinical effects of Vit-B<sub>12</sub> against nicotine, the optimum dosage for the inhalation intervention and for applications should be investigated in detail.

In conclusion, nicotine used during pregnancy has a negative morphological effect on the fetus, dose-dependently. The use of Vit-B<sub>12</sub> reduces the negative effects of nicotine on the fetus. Further biomolecular pathway studies are required to highlight the underlying mechanism of these effects.

#### Declaration of conflicting interests

The authors declared no conflicts of interest with respect to the authorship and/or publication of this article.

#### Funding

The authors received no financial support for the research and/or authorship of this article.

## REFERENCES

1. Shea AK, Steiner M. Cigarette smoking during pregnancy. *Nicotine Tob Res* 2008;10:267-78.
2. McGrath-Morrow SA, Gorzkowski J, Groner JA, Rule AM, Wilson K, Tanski SE, et al. The effects of nicotine on development. *Pediatrics* 2020;145:e20191346.
3. Yılmaz H, Ertekin T, Atay E, Nisari M, Susar Güler H, Al Ö, et al. Antioxidant role of melatonin against nicotine's teratogenic effects on embryonic bone development. *Iran J Basic Med Sci* 2018;21:787-93.
4. Benowitz NL, Hukkanen J, Jacob P 3rd. Nicotine chemistry, metabolism, kinetics and biomarkers. *Handb Exp Pharmacol* 2009;(192):29-60.
5. Spector LG, Murphy SE, Wickham KM, Lindgren B, Joseph AM. Prenatal tobacco exposure and cotinine in newborn dried blood spots. *Pediatrics* 2014;133:e1632-8.
6. Faber T, Kumar A, Mackenbach JP, Millett C, Basu S, Sheikh A, et al. Effect of tobacco control policies on perinatal and child health: A systematic review and meta-analysis. *Lancet Public Health* 2017;2:e420-e437.
7. Nakamura A, François O, Lepeule J. Epigenetic alterations of maternal tobacco smoking during pregnancy: A narrative review. *Int J Environ Res Public Health* 2021;18:5083.
8. Suter MA, Aagaard KM. The impact of tobacco chemicals and nicotine on placental development. *Prenat Diagn* 2020;40:1193-200.
9. Mizrak S, Turan V, Caglayan O, Ercan G. The effect of long term pre/postnatal low/high dose nicotine exposure on



- tissue oxidant/antioxidant status and DNA damage in rats. *Drug Res (Stuttg)* 2015;65:432-6.
10. Onuki M, Yokoyama K, Kimura K, Sato H, Nordin RB, Naing L, et al. Assessment of urinary cotinine as a marker of nicotine absorption from tobacco leaves: A study on tobacco farmers in Malaysia. *J Occup Health* 2003;45:140-5.
  11. Zhao Z, Reece EA. Nicotine-induced embryonic malformations mediated by apoptosis from increasing intracellular calcium and oxidative stress. *Birth Defects Res B Dev Reprod Toxicol* 2005;74:383-91.
  12. Abate M, Vanni D, Pantalone A, Salini V. Cigarette smoking and musculoskeletal disorders. *Muscles Ligaments Tendons J* 2013;3:63-9.
  13. Swart KM, van Schoor NM, Lips P. Vitamin B12, folic acid, and bone. *Curr Osteoporos Rep* 2013;11:213-8.
  14. Monsen AL, Refsum H, Markestad T, Ueland PM. Cobalamin status and its biochemical markers methylmalonic acid and homocysteine in different age groups from 4 days to 19 years. *Clin Chem* 2003;49:2067-75.
  15. Bhattacharjee A, Prasad SK, Pal S, Maji B, Syamal AK, Banerjee A, et al. Protective efficacy of folic acid and vitamin B12 against nicotine-induced toxicity in pancreatic islets of the rat. *Interdiscip Toxicol* 2015;8:103-11.
  16. Miller DM, Tarpley J. An automated double staining procedure for bone and cartilage. *Biotech Histochem* 1996;71:79-83.
  17. Lee KM, Lee J, Chung CY, Ahn S, Sung KH, Kim TW, et al. Pitfalls and important issues in testing reliability using intraclass correlation coefficients in orthopaedic research. *Clin Orthop Surg* 2012;4:149-55.
  18. Atik OŞ. What are the expectations of an editor from a scientific article? *Jt Dis Relat Surg* 2020;31:597-8.
  19. Kurtoglu S, Gunes T, Koklu E, Bastug O, Canoz O, Kula M, et al. Influence of maternal nicotine exposure on neonatal rat bone: Protective effect of pentoxifylline. *Exp Biol Med (Maywood)* 2007;232:398-405.
  20. Altun I, Yuksel KZ. An experimental study on the effects of smoking in the perinatal period and during lactation on the intervertebral disks of newborns. *World Neurosurg* 2017;99:1-5.
  21. Koklu E, Gunes T, Gunes I, Canoz O, Kurtoglu S, Duygulu F, et al. Influence of maternal nicotine exposure on neonatal rat bone: Protective effect of ascorbic acid. *Am J Perinatol* 2006;23:387-95.
  22. Horta BL, Victora CG, Menezes AM, Halpern R, Barros FC. Low birthweight, preterm births and intrauterine growth retardation in relation to maternal smoking. *Paediatr Perinat Epidemiol* 1997;11:140-51.
  23. Seller MJ, Bnait KS. Effects of tobacco smoke inhalation on the developing mouse embryo and fetus. *Reprod Toxicol* 1995;9:449-59.
  24. Carmines EL, Gaworski CL, Faqi AS, Rajendran N. In utero exposure to 1R4F reference cigarette smoke: Evaluation of developmental toxicity. *Toxicol Sci* 2003;75:134-47.
  25. Gunes T, Koklu E, Gunes I, Narin F, Koklu S. Influence of maternal nicotine exposure on neonatal rat oxidant-antioxidant system and effect of ascorbic acid supplementation. *Hum Exp Toxicol* 2008;27:781-6.
  26. De Martinis M, Sirufo MM, Nocelli C, Fontanella L, Ginaldi L. Hyperhomocysteinemia is associated with inflammation, bone resorption, vitamin B12 and folate deficiency and MTHFR C677T polymorphism in postmenopausal women with decreased bone mineral density. *Int J Environ Res Public Health* 2020;17:4260.
  27. De Martinis M, Sirufo MM, Suppa M, Ginaldi L. IL-33/IL-31 axis in osteoporosis. *Int J Mol Sci* 2020;21:1239.
  28. Bhattacharjee A, Prasad SK, Pal S, Maji B, Syamal AK, Mukherjee S. Synergistic protective effect of folic acid and vitamin B12 against nicotine-induced oxidative stress and apoptosis in pancreatic islets of the rat. *Pharm Biol* 2016;54:433-44.
  29. Bhattacharjee A, Prasad SK, Banerjee O, Singh S, Banerjee A, Bose A, et al. Targeting mitochondria with folic acid and vitamin B12 ameliorates nicotine mediated islet cell dysfunction. *Environ Toxicol* 2018;33:988-1000.
  30. Merriman NA, Putt ME, Metz DC, Yang YX. Hip fracture risk in patients with a diagnosis of pernicious anemia. *Gastroenterology* 2010;138:1330-7.
  31. Roman-Garcia P, Quiros-Gonzalez I, Mottram L, Lieben L, Sharan K, Wangwiwatsin A, et al. Vitamin B12-dependent taurine synthesis regulates growth and bone mass. *J Clin Invest* 2014;124:2988-3002.