



## Poland's syndrome concomitant with congenital proximal and distal radioulnar synostosis: A rare case report

Şerif Seyyid Ünsal, MD<sup>1</sup>, Uğur Bezirgan, MD<sup>2</sup>, Emre Anıl Özbek, MD<sup>3</sup>, Mustafa Özyıldırım, MD<sup>3</sup>, Tuğrul Yıldırım, MD<sup>4</sup>, Mehmet Armangil, MD<sup>3</sup>

<sup>1</sup>Department of Hand Surgery, Kanuni Training and Research Hospital, Trabzon, Turkey

<sup>2</sup>Department of Hand Surgery, Ankara City Hospital, Ankara, Turkey

<sup>3</sup>Department of Orthopedics and Traumatology, Ankara University School Of Medicine, Ankara, Turkey

<sup>4</sup>Department of Orthopedics and Traumatology, Emot Hospital, Izmir, Turkey

Congenital radioulnar synostosis, a rare congenital malformation,<sup>[1]</sup> was first described by Sandifort<sup>[2]</sup> in 1793. Approximately 350 cases of proximal congenital radioulnar synostosis have been reported in the literature.<sup>[2,3]</sup> Toward the end of the fourth week of embryogenic development, the buds that would form the upper extremities begin to appear. At the end of the fifth week, cartilage analogs of the humerus, radius, and ulna appear. Before segmentation, these cartilage analogs+ are interconnected, and they have a common perichondrium.<sup>[2,4]</sup> In the seventh week of the embryonic life, synostosis occurs as a result of a defect in segmentation. As a result of endochondral ossification, the cartilaginous bridge ossifies or fibrous synostosis occurs. Since the fetal

### ABSTRACT

Radioulnar synostosis is a rare disease which causes supination and pronation restriction as a result of osseous or fibrous connections between the radius and ulna. Radioulnar synostosis includes both congenital and post-traumatic types. Post-traumatic radioulnar synostosis can be seen in the proximal, middle, and distal part of the forearm, depending on the location of the trauma. Congenital proximal radioulnar synostosis occurs as a result of a separation defect between the radius and ulna in the embryonic period. In the presence of congenital proximal radioulnar synostosis, the patient should be evaluated for accompanying syndromes and possible developmental anomalies. In this report, we present a rare case of both proximal and distal radioulnar synostosis. Hypoplasia of the right pectoral muscle mass, hypoplastic appearance of the right nipple, presence of proximal and distal radioulnar synostosis in the right forearm, and accompanying symbrachydactyly suggested Poland syndrome. To the best of our knowledge this is the first case of congenital proximal and distal radioulnar synostosis with Poland syndrome.

**Keywords:** Poland syndrome, radioulnar synostosis, symbrachydactyly.

Received: March 21, 2021

Accepted: May 07, 2021

Published online: November 19, 2021

**Correspondence:** Emre Anıl Özbek, MD, Ankara Üniversitesi Tıp Fakültesi Ortopedi ve Travmatoloji Anabilim Dalı, 06590 Çankaya, Ankara, Türkiye.

E-mail: anil\_ozbek@hotmail.com

Doi: 10.52312/jdrs.2021.100

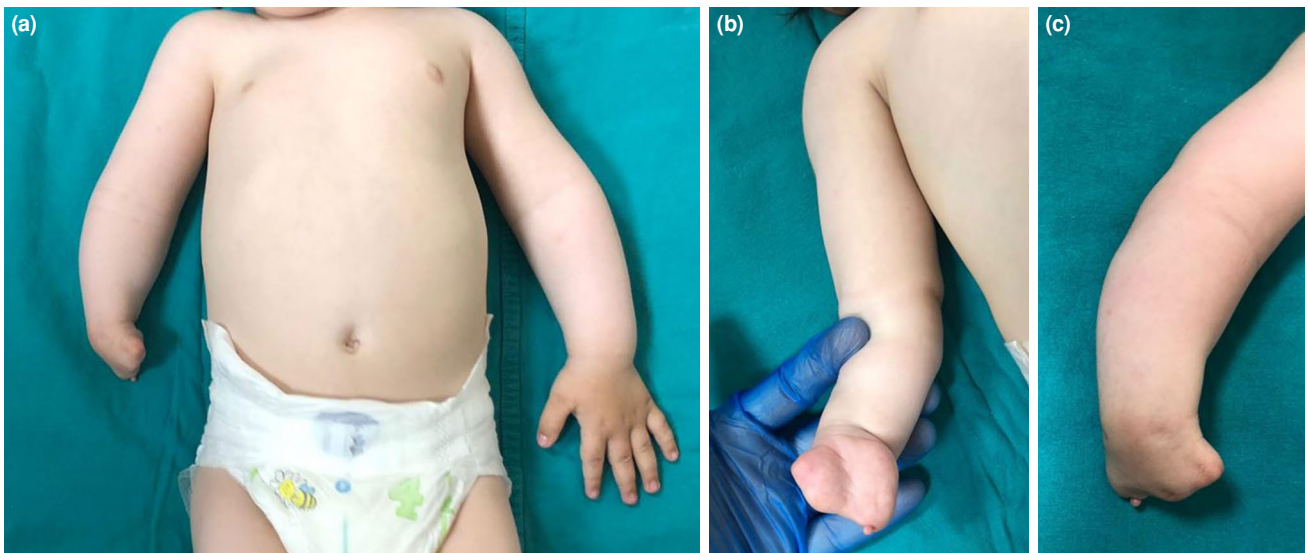
**Citation:** Ünsal ŞŞ, Bezirgan U, Özbek EA, Özyıldırım M, Yıldırım T, Armangil M. Poland's syndrome concomitant with congenital proximal and distal radioulnar synostosis: A rare case report. Jt Dis Relat Surg 2021;32(3):814-817.

©2021 All right reserved by the Turkish Joint Diseases Foundation

This is an open access article under the terms of the Creative Commons Attribution-NonCommercial License, which permits use, distribution and reproduction in any medium, provided the original work is properly cited and is not used for commercial purposes (<http://creativecommons.org/licenses/by-nc/4.0/>).

forearm is in the pronation at the seventh week, the same position is preserved in the next stages of development.<sup>[4,5]</sup>

Although it is present from birth, most patients are diagnosed with restricted pronation and supination in childhood between the ages of two and six years. Functionally mild cases may not be noticed until adolescence.<sup>[6]</sup> The reason for the delay in diagnosis is that infants do not need forearm rotation or shoulder and wrist motion can compensate fixed position of the forearm.<sup>[7]</sup> Most cases of congenital radioulnar synostosis reported in the literature are proximal radioulnar synostosis, and 60% have been reported to be bilateral.<sup>[2]</sup>



**FIGURE 1.** (a) Right forearm in pronation, right pectoral region is hypoplastic compared to left; (b) 1<sup>st</sup>, 2<sup>nd</sup>, 3<sup>rd</sup> and 4<sup>th</sup> fingers congenitally missing; (c) 5<sup>th</sup> finger rudimentary.

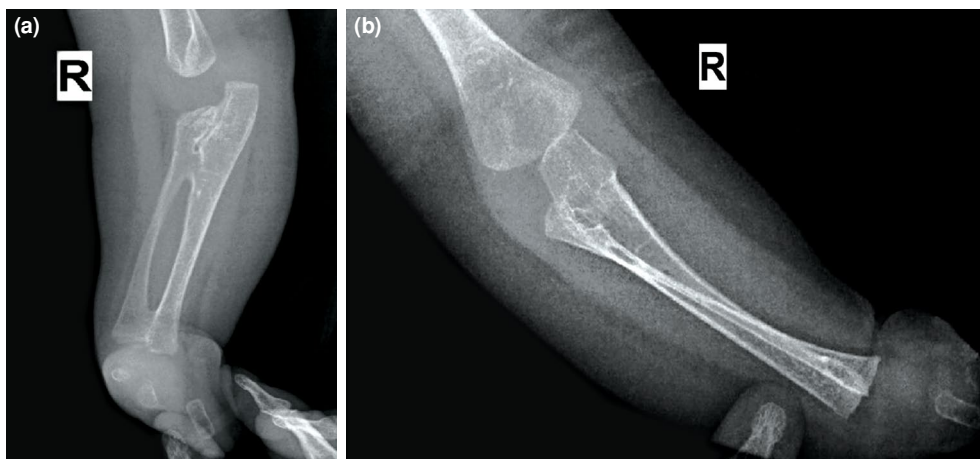
Other musculoskeletal anomalies may accompany, such as thumb hypoplasia, carpal coalition, developmental hip dysplasia, clubfoot (pes equinovarus), syndactyly, polydactyly, and Madelung deformity. Underlying syndromes, such as Poland syndrome, Holt-Oram syndrome, Apert syndrome, and fetal alcohol syndrome should be investigated. Patients should be evaluated by cardiac, gastrointestinal, renal, and neurological system examinations.

In this article, we report a rare case of congenital proximal and distal radioulnar synostosis with Poland syndrome.

## CASE REPORT

A one-year-old male patient was admitted to our clinic with limited supination in the right forearm and agenesis of the first, second, third, and fourth fingers of the right hand. His 32-year-old mother gave birth to him at term by normal vaginal delivery. There were five miscarriages before the first live birth by the mother. There was no history of drug use by the mother during the pregnancy. His sibling was a four-year-old female and was previously operated for bilateral postaxial type B polydactyly.

On physical examination, the right forearm was in a fixed pronation position of 45 degrees. He had full



**FIGURE 2.** Osseous bridging appearance between proximal and distal metaphyseal regions between radius and ulna in the right forearm radiography. Proximal and distal congenital radioulnar synostosis.

active and passive elbow and wrist range of motion. He had aphyalangia type symbrachydactyly; aplasia of the first, second, third, and fourth fingers of the right hand, and a rudimentary fifth finger. The right nipple was hypoplastic compared to the left nipple (Figure 1). No other pathology was found in the musculoskeletal examination. When the patient's face was examined, no syndromic appearance suggesting clinical conditions, such as fetal alcohol syndrome or Apert syndrome, was observed. He had no accompanying cardiac, renal, or gastrointestinal anomaly except for cryptorchidism. Osseous bridging was observed in the proximal and distal metaphyseal regions between the right radius and ulna on radiography. The radial head was not yet ossified (Figure 2). The patient was consulted to the pediatric department in terms of other possible genetic disorders. The results of the cytogenetic analysis were reported to be normal (46XY).

A written informed consent was obtained from the parents of the patient.

## DISCUSSION

First described by Sir Alfred Poland.<sup>[8]</sup> in 1841, Poland syndrome is a rare disease characterized by aplasia or hypoplasia of the sternocostal head of the pectoralis major muscle.<sup>[9,10]</sup> It is usually accompanied by hypoplasia or aplasia of ipsilateral breast tissue, lack of subcutaneous fat tissue, and ipsilateral upper extremity anomalies. Hypoplasia in the radius and ulna, hypoplastic hand, brachysyndactyly, finger agenesis, and radioulnar synostosis are the major skeletal deformities of the upper extremity.<sup>[11,12]</sup> Rib, sternum, and clavicle anomalies may accompany, and vertebral anomalies may be observed.<sup>[13]</sup> Dextrocardia may accompany left-sided involvement, which is due to narrowing of the left thoracic cavity.<sup>[14]</sup> In cases with a severe clinical course, involvement can be also observed in the pectoralis minor, serratus, latissimus dorsi, infraspinatus, and supraspinatus muscles.<sup>[15]</sup>

The incidence of Poland syndrome has been reported to be approximately one in 30,000 live births.<sup>[16]</sup> Fraser et al.<sup>[9]</sup> reported that the female:male ratio was 1:3, and the right side of the body was affected in 67 to 75% of cases. Although it is typically sporadic, familial cases are reported in the literature.<sup>[10]</sup> Despite the etiology of Poland syndrome remains unclear, it is thought to develop because of the decreased blood supply to the pectoralis major muscle in the embryonic period.<sup>[17]</sup>

Al-Qattan<sup>[18]</sup> published a classification of hand anomalies that accompany Poland syndrome.

In type I, the hands are completely normal; however, there is an isolated pectoral anomaly. In type II, the ipsilateral hand is hypoplastic compared to the contralateral side. type III has brachysyndactyly. Some fingers are congenitally absent in type IV. Depending on the adactyly, cleft hand and clubhand deformities may accompany. type V does not have all fingers on the hand, or there are rudimentary remnants without function. In type VI, the metacarpals are rudimentary. type VII has a phocomelia-like deficiency. The patient's right hand was diagnosed as type V according to the Al-Qattan classification.

We examined a case that presented to our clinic with hypoplasia of the right pectoral muscle mass, hypoplastic right nipple, presence of proximal and distal radioulnar synostosis in the right forearm, and accompanying finger agenesis, which suggested Poland syndrome. The thorax and vertebra were not affected. There were no concomitant cardiac, gastrointestinal, or renal anomalies.

Most of the congenital radioulnar synostosis cases reported in the literature are proximal radioulnar synostosis. However, there is a double synostosis both proximal and distal part of forearm in the presented case. To the best of our knowledge, this is the first reported case of congenital proximal and distal radioulnar synostosis.

The indication for the surgical treatment of congenital radioulnar synostosis remains unclear. In determining the treatment, functional limitations caused by the deformity in the patient should be considered. In parallel with the development of the current technology, as the use of a keyboard and mouse in most white-collar professions requires a pronation position, the final position of the forearm should be decided after the child's interests are revealed or after the choice of profession. Surgery is considered in patients with pronation deformity of more than 60 degrees in cases of severe functional restriction of activities requiring supination.<sup>[2]</sup> Excisions (*i.e.*, bony bridge, annular-ligament-like tissue, anterior capsule, radial head), rotational osteotomies, and interpositional grafts are surgical techniques described in the literature.<sup>[19]</sup> However, the risk of recurrence is high.<sup>[2,20]</sup> Since there was no functional hand in the case we presented, surgical treatment for radioulnar synostosis was not planned at this stage.

In conclusion, congenital radioulnar synostosis is a rare malformation. It should be evaluated in terms of accompanying symptoms or systemic

anomalies. Congenital radioulnar synostosis cases reported in the literature are proximal radioulnar synostosis. Proximal and distal congenital radioulnar synostosis was observed in our case, which was thought to be compatible with Poland syndrome based on other system examinations and related department consultations. Indication for surgical treatment of congenital radioulnar synostosis remains controversial. Functional limitations and degree of deformity should be considered to determine the type of the treatment.

#### Declaration of conflicting interests

The authors declared no conflicts of interest with respect to the authorship and/or publication of this article.

#### Funding

The authors received no financial support for the research and/or authorship of this article.

## REFERENCES

1. Lescault E, Mulligan J, Williams G. Congenital radioulnar synostosis in an active duty soldier: Case report and literature review. *Mil Med* 2000;165:425-8.
2. Radial-ulnar synostosis. eMedicine. 2020. Available at: <http://emedicine.medscape.com/article/1240467-overview> [Accessed: February 01, 2021]
3. Siemianowicz A, Wawrzynek W, Besler K. Congenital radioulnar synostosis - case report. *Pol J Radiol* 2010;75:51-4.
4. Moore KL, Persaud TVN, Torchia MG, editors. *The developing human: Clinically oriented embryology*. 10th ed. Philadelphia: Elsevier; 2015.
5. Wilkie DPD. Congenital radioulnar synostosis. *Br J Surg* 1914;1:366-75.
6. Guma M, Teitel AD. Adolescent presentation of congenital radioulnar synostosis. *Clin Pediatr (Phila)* 1996;35:215-7.
7. Green WT, Mital MA. Congenital radio-ulnar synostosis: Surgical treatment. *J Bone Joint Surg [Am]* 1979;61:738-43.
8. Poland A. Deficiency of the pectoral muscles. *Guy's Hospital Reports* 1841;6:191-3.
9. Fraser FC, Teebi AS, Walsh S, Pinsky L. Poland sequence with dextrocardia: which comes first? *Am J Med Genet* 1997;73:194-6.
10. Jones KL, Jones MC, editors. *Smith's recognizable patterns of human malformation*. 7th ed. Philadelphia: Saunders; 2013.
11. Romanini MV, Torre M, Santi P, Dova L, Valle M, Martinoli C, et al. Proposal of the TBN classification of thoracic anomalies and treatment algorithm for Poland syndrome. *Plast Reconstr Surg* 2016;138:50-8.
12. Hammer SG. Poland sequence: Two unusual cases and brief review of the literature. *WMJ* 1999;98:52-4.
13. Bavinck JN, Weaver DD. Subclavian artery supply disruption sequence: Hypothesis of a vascular etiology for Poland, Klippel-Feil, and Möbius anomalies. *Am J Med Genet* 1986;23:903-18.
14. Sucuoğlu H, Aslan H, Avdan Aslan A, Öz V. Poland sendromu: İki olgu sunumu. *Turk J Phys Med Rehab* 2016;62:264-8.
15. Cochran JH Jr, Pauly TJ, Edstrom LE, Dibbell DG. Hypoplasia of the latissimus dorsi muscle complicating breast reconstruction in Poland's syndrome. *Ann Plast Surg* 1981;6:402-4.
16. Stevens DB, Fink BA, Prevel C. Poland's syndrome in one identical twin. *J Pediatr Orthop* 2000;20:392-5.
17. National Human Genome Research Institute. Learning about polandanomaly. 2012. Available at: <http://www.genome.gov/14514230>. [Accessed: February 01, 2021]
18. Al-Qattan MM. Classification of hand anomalies in Poland's syndrome. *Br J Plast Surg* 2001;54:132-6.
19. Wang E, Wenger DR, Zhang L, Zhao Q, Ji S, Li J. The mechanism of acute elbow flexion contracture in children with congenital proximal radioulnar synostosis. *J Pediatr Orthop* 2010;30:277-81.
20. Pei X, Han J. Efficacy and feasibility of proximal radioulnar derotational osteotomy and internal fixation for the treatment of congenital radioulnar synostosis. *J Orthop Surg Res* 2019;14:81.