



Quadriceps reconstruction with suture anchor and Achilles allograft combination in quadriceps tendon re-rupture after primary surgical repair: A novel technique

Erhan Okay¹, Mehmet Cenk Turgut², Abbas Tokyay³

¹Department of Orthopedics and Traumatology, Ministry of Health, Göztepe Prof. Dr. Süleyman Yalçın City Hospital, Istanbul, Turkey

²Department of Orthopedics and Traumatology, Ministry of Health, Erzurum City Hospital, Erzurum, Turkey

³Department of Orthopedics and Traumatology, Yüzüncü Yıl University Faculty of Medicine, Van, Turkey

Quadriceps ruptures are one of the knee extensor mechanism pathologies, accounting for 3% of all tendon injuries.^[1] These ruptures mainly occur as a result of atraumatic conditions such as systemic diseases (i.e., gout, rheumatoid arthritis, chronic renal failure) and drug use (i.e., statins and steroids).^[2,3] Although rare, these ruptures can be traumatic in origin, which makes the diagnosis more difficult.^[3] Both repair and healing of quadriceps tears become more challenging in chronic conditions due to the massive retraction of the proximal part of rupture, which may obviate the need for tendon reconstructions.^[4] Gap-filling techniques have better outcomes than primary repair in these cases.^[5]

Received: January 18, 2021

Accepted: April 30, 2021

Published online: May 28, 2021

Correspondence: Mehmet Cenk Turgut, MD, Erzurum Şehir Hastanesi Ortopedi ve Travmatoloji Kliniği, 25240 Yakutiye, Erzurum, Türkiye.

E-mail: m.cenkturgut@hotmail.com

Doi: 10.52312/jdrs.2021.14

Citation: Okay E, Turgut MC, Tokyay A. Quadriceps reconstruction with suture anchor and Achilles allograft combination in quadriceps tendon re-rupture after primary surgical repair: A novel technique. Jt Dis Relat Surg 2021;32(3):i-vi.

©2021 All right reserved by the Turkish Joint Diseases Foundation

This is an open access article under the terms of the Creative Commons Attribution-NonCommercial License, which permits use, distribution and reproduction in any medium, provided the original work is properly cited and is not used for commercial purposes (<http://creativecommons.org/licenses/by-nc/4.0/>).

ABSTRACT

Quadriceps ruptures are one of the pathological conditions of the knee extensor mechanism, accounting for 3% of all tendon injuries. These injuries cause substantial disability of the extensor mechanism. Primary repair is the treatment of choice in acute presentation. In the setting of chronic conditions, the treatment becomes more challenging. Available surgical options include lengthening procedures, and reconstruction with autograft or allografts. The traditional Scuderi and Codivilla techniques are challenging to perform in degenerative or traumatic retracted ruptures. There is no standard effective treatment in these patients, which yields the best clinical and biomechanical outcomes. An 18-year-old male patient with quadriceps rupture after a primary repair was managed with allograft reconstruction using suture anchors. At six years of follow-up the patient gained a full range of motion with excellent clinical outcomes. He returned to his previous work. In conclusion, quadriceps reconstruction using suture anchor and Achilles allograft combination is a feasible technique in neglected cases who present with quadriceps tendon rupture after primary surgical repair.

Keywords: Achilles allograft, quadriceps tendon re-rupture, suture anchor.

Numerous reconstruction techniques have been proposed to reinforce and approximate both ends of quadriceps rupture, including Codivilla V-Y lengthening, Scuderi, transpatellar reconstruction using autograft, and augmentation techniques. A growing number of studies have attempted to determine the optimal reconstruction technique restoring quadriceps biomechanics with fewer complications.^[6] Currently, there is no standard effective treatment in this difficult condition.^[4,7] Herein, we present a failed, neglected, and traumatic quadriceps rupture that previously underwent primary quadriceps repair and, then, successfully treated with suture anchor

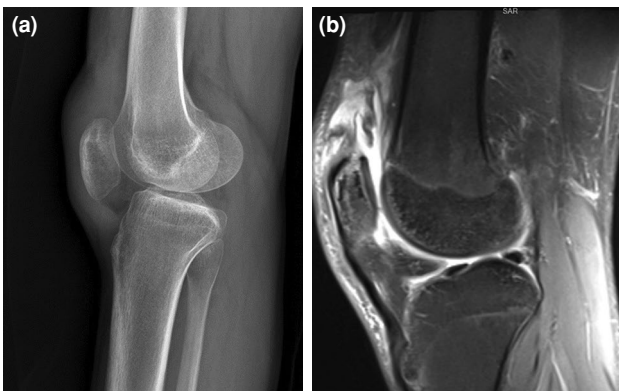


FIGURE 1. (a) Preoperative lateral knee radiograph showing the absence of osseous pathology with patella baja compatible with a quadriceps rupture. (b) Preoperative sagittal magnetic resonance imaging section showing massive retracted quadriceps rupture.

reconstruction using Achilles allograft. This case represents the first description of a novel technique using suture anchor and non-irradiated Achilles allograft in revision quadriceps tendon repair.

CASE REPORT

An 18-year-old male patient presented to the emergency clinic with a penetrating injury to the right leg due to a heavy glass fall while working, resulting in immediate pain and inability to ambulate. Upon examination of 5×3-cm laceration, quadriceps rupture was identified and managed by primary repair. At the first month of follow-up, he felt down and was presented to us with extensor insufficiency after two months of the previous trauma. On physical examination of the quadriceps tendon, a positive lag sign was observed. The patient was unable to extend his knee. His main complaint was limping which interfered with his daily living activities. The neurological examination findings were normal. He had no systemic condition or history of drug use. Radiographs showed no

osseous pathology (Figure 1a). Magnetic resonance imaging (MRI) confirmed a rupture with a substantial gap at the mid-tendon-musculotendinous junction of quadriceps muscle which was suspected to occur through the failure of previous quadriceps repair (Figure 1b).

Upon shared decision-making with the patient, all options, including the Scuderi technique, Codivilla V-Y lengthening, and reconstruction allograft or autograft combined with augmentation, were considered for surgical planning. Despite re-approximation and multiple attempts, we observed a stiff tendon making the repair difficult by traditional lengthening techniques. The gap was approximately 6 cm in size, which did not allow any lengthening procedures. In this case, traditional techniques such as the Scuderi technique and Codivilla V-Y lengthening, were technically challenging in degenerative or chronic retracted tendons, as described by Rocha de Faria et al.^[3]

Under spinal anesthesia, a 15-cm longitudinal incision medial to previous surgical incision was performed over the right knee from the superior pole of the patella (Figure 2a). This incision provides an enhanced exposure to evaluate healthy and degenerated muscle structures. The proximal and distal portions of rupture were identified (Figure 2b, c). The tourniquet was opened during debridement and reconstruction. Necrotic tissue was identified and, then, debrided. Adhesions were released to approximate proximal and distal portions of the rupture. Despite re-approximation, the gap was measured as 6×3 cm, making the repair difficult by traditional lengthening techniques. The autograft option was considered suboptimal due to post-traumatic adhesions and poor tissue quality. Also, the patient rejected the use of autograft. Depending on the surgeon and patient's ultimate decision (autograft vs. allograft), reconstruction with Achilles allograft

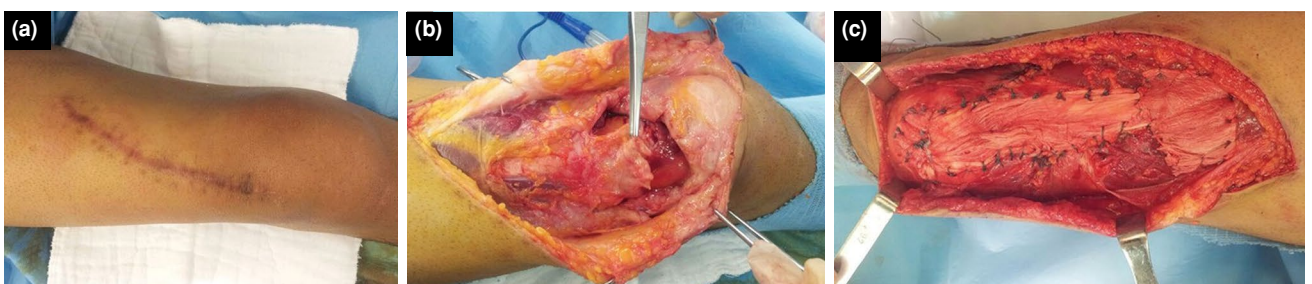


FIGURE 2. Intraoperative view of the surgical area. (a) Before the operation. (b) Identification of rupture. (c) Final intraoperative view showing upper layer of the allograft. Both layers were sutured to adjacent tissues.

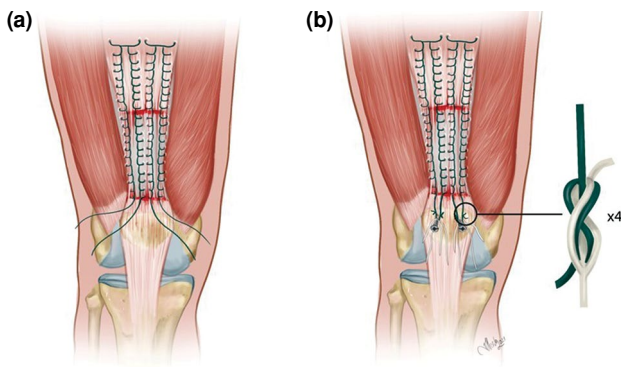


FIGURE 3. Representative drawing of the technique. (a) Suture configuration after placement of allograft. (b) Final view after placement of suture anchors to the superomedial side of the patella.

was preferred. Bone block in Achilles allograft was removed. Proximal and distal edges of the graft were prepared to fit either part of the rupture. The graft was 10 cm in length and 3 cm in diameter. The size of the distal stump was 1×2 cm. The graft was folded over its length covering the gap (6×3 cm) in a double-layered fashion. Graft reconstruction was made by the end-to-end repair using the Krackow technique with No. 2 non-absorbable braided sutures (Ethibond®; Ethicon Inc., Somerville, NJ, USA) to maintain construct stability along with the graft (Figure 3a). These sutures bypassed the proximal and distal extents of the double layers of allograft and native healthy tendon proximally. Two 5-mm titanium anchors for each (Ti-Screw Anchor™; Biomet, Warsaw,

IN, USA) loaded with two No. 2 sutures (MaxBraid™; Biomet Sports Medicine, Warsaw, IN, USA) were placed on the superior pole of patella 2 cm apart from each other. The Krackow suture's limbs were pulled distally and tied with the sutures of anchors on the allograft using surgical knot (Figure 3b). The allograft was tensioned with the knee in full extension. The entire procedure of reconstruction was applied in knee extension to avoid laxity. Finally, the graft was sutured primarily to the adjacent tissue (Figure 2c).

A good patellofemoral alignment in both planes was confirmed by comparing the operated knee with the contralateral side. Stability was checked with the stress test at 40 to 60 degrees of flexion. Intraoperative fluoroscopy was used to ensure the optimal patellar position. Based on the intraoperative evaluation, no augmentation technique was considered. Following hemostasis, the wound was closed by layers. A drain was used to prevent hematoma.

The knee was maintained in full extension for four weeks in a cast. Quadriceps exercises were initiated. Passive range of motion was commenced four weeks after surgery. At six weeks postoperatively, active range of motion and full weight-bearing were allowed. Six years after surgery, control MRI showed graft incorporation (Figure 4a). Control X-ray demonstrated patella baja deformity (Figure 4b); however, the patient had 135 degrees of flexion and less than 10 degrees of extension, compared to the healthy side (Figure 5a, b). He was able to do a double-leg semi-squat at 135 degrees of flexion (Figure 5c-d). He was a worker in the glass industry. He lifted

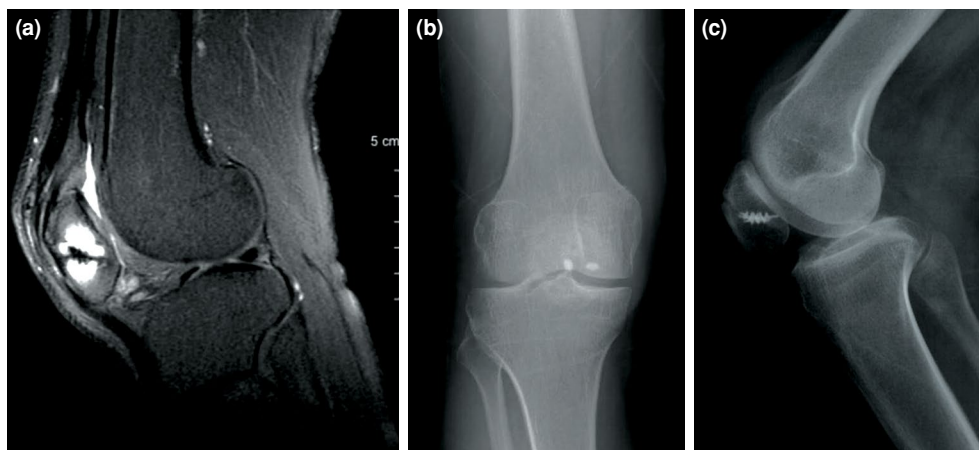


FIGURE 4. Postoperative control MRI at six years of follow-up. (a) Sagittal MRI. (b) Anteroposterior and (c) lateral radiographs of the knee. Graft incorporation is evident. The patient had patella baja not interfering with physical activities.
MRI: Magnetic resonance imaging.

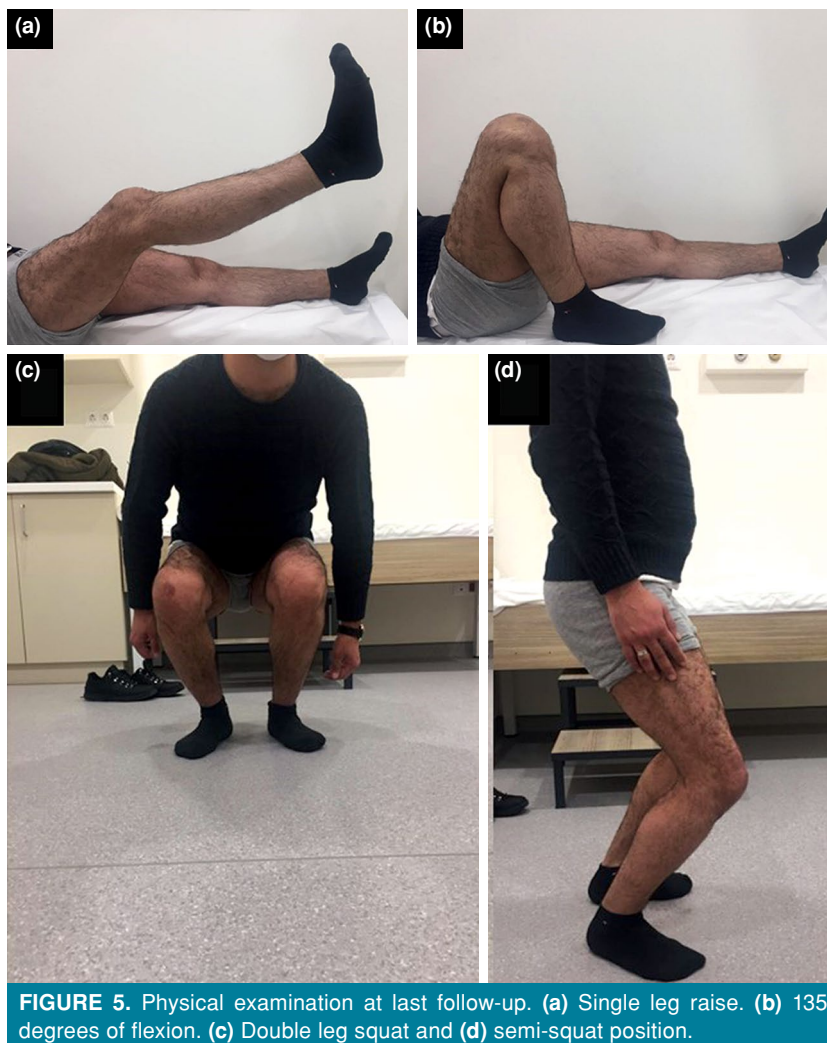


FIGURE 5. Physical examination at last follow-up. (a) Single leg raise. (b) 135 degrees of flexion. (c) Double leg squat and (d) semi-squat position.

heavy-cut glass pieces. After surgery, he returned to his previous work. The Lysholm's score was 98 points. Repeated MRI at the last follow-up demonstrated graft incorporation.

A written informed consent was obtained from the patient.

DISCUSSION

The most important finding of the present case is that allograft reconstruction using suture anchors may be a viable surgical technique in chronic retracted quadriceps ruptures with poor tissue quality. In primary ruptures with less than 6-cm gaps, repair with suture anchors results in satisfactory outcomes; however, in chronic retracted ruptures, gap-filling techniques are needed. In this regard, allografts are utilized in the reconstruction of extensor mechanism injuries.^[8-11]

After total knee arthroplasty, quadriceps injuries are highly correlated with poor outcomes. A primary repair cannot restore the extensor mechanism.^[10] In their case series including 17 reconstructions, Wise et al.^[11] obtained durable outcomes with minimal extension deficit after an average of 65.4 months of follow-up. Lamberti et al.^[12] performed bilateral allograft reconstruction in a 51-year-old female patient with renal disease due to chronic spontaneous rupture of the left quadriceps tendon and right patellar tendon. They used full extensor mechanism allograft, including the tibial tubercle, patellar tendon, patellar bone, and quadriceps tendon and observed excellent clinical outcome at 57 months of follow-up. Kunze et al.^[4] presented a technique in large quadriceps tendon defects using a trapezoidal Achilles tendon allograft plug which did not rely on soft tissue fixation. The patient performed a high-level sportive activity 20 weeks after surgery. The authors also

underlined the lack of a superior reconstruction in the repair of these defects and warned about improper orientation of anchors and drilling the bone tunnels in this technique. Our technique was different, as we did not establish patellar tunnels, bearing the risk of bony wall fractures and damage to the articular surface of patella. Instead, we used suture anchors to fix the allograft to the patellar bone. In their technical note, Paez and Rebolledo^[4] used suture anchor to repair chronic quadriceps tendon injury using V-Y quadricepsplasty with Achilles allograft augmentation. They did not present their case and emphasized that tears retracted more than 6 cm were difficult to manage with the lengthening procedure. Differently, we used Achilles allograft as a gap-filler rather than augmentation to a lengthening procedure.

It is emphasized that allografts provided satisfactory results, when proper technique is applied with the tension of allografts in extension.^[13] In their case series with extensor mechanism injuries, Forslund et al.^[8] introduced a transpatellar repair technique with calcaneal allograft bone block for chronic ruptures and, at thirteen months postoperatively, the patient returned to his previous work status. The authors suggested allografts as the best option in chronic and revision cases. In a recent study involving 14 patients with extensor mechanism injuries, Karas et al.,^[9] demonstrated satisfactory outcomes in one patient who underwent transpatellar revision repair with Achilles allograft. At 34 months of follow-up, the patient had no extension lag with a full range of motion.

Our patient is a unique case in terms of a rupture via a traumatic mechanism seen in a high-demand young patient which causes work loss and compensation claims. Additionally, tendon-to-tendon healing was observed in the present case, which makes it difficult to compare with transpatellar techniques, including some complications (patellar stress fractures and intraarticular damage).^[4,6]

Regarding autografts, post-traumatic adhesions and poor tissue quality may preclude the harvest of optimal autograft. Also, the autografts have been used combined with transpatellar techniques, which require an optimal tunnel position and tunnel size matched to the autograft.^[5] In case of autograft failure, Achilles allograft can be considered an alternative in revision. Also, in our case, the use of autografts possibly needs extensive harvesting, which would lead to morbidity. There is also the risk of saphenous nerve injury and premature amputation of tendons.^[7] Finally, although early postoperative mobilization is suggested, passive exercises are prohibited until

four weeks to enhance soft tissue healing over the allograft to avoid graft attenuation and delay in tendon healing.^[1] It is unknown whether early mobilization would accelerate postoperative recovery in our technique and should be investigated in large cohorts. There are some disadvantages of Achilles allografts including non-physiological stiffness, risk of infection, disease transmission, problems regarding availability in some countries, and the increased cost. Despite these drawbacks, quadriceps reconstruction using the Achilles allograft and suture anchor is a feasible technique in the setting of failed quadriceps ruptures, particularly in ruptures located most commonly in the musculotendinous junction.^[5,14] Its benefits such as no need for harvesting the tendon and absence of donor site morbidity should be weighted against previously mentioned disadvantages. The decision for allograft should be made intraoperatively, when traditional techniques have failed to re-approximate the rupture ends.

In conclusion, the use of suture anchor and Achilles allograft combination in quadriceps reconstruction can be considered an alternative technique in delayed quadriceps ruptures. Nevertheless, large case series are needed to confirm the use of Achilles allografts in well-selected patients and to identify the patient group with an increased risk of complications.

Declaration of conflicting interests

The authors declared no conflicts of interest with respect to the authorship and/or publication of this article.

Funding

The authors received no financial support for the research and/or authorship of this article.

REFERENCES

- Langenhan R, Baumann M, Ricart P, Hak D, Probst A, Badke A, et al. Postoperative functional rehabilitation after repair of quadriceps tendon ruptures: A comparison of two different protocols. *Knee Surg Sports Traumatol Arthrosc* 2012;20:2275-8.
- Pengas IP, Assiotis A, Khan W, Spalding T. Adult native knee extensor mechanism ruptures. *Injury* 2016;47:2065-70.
- Rocha de Faria JL, Barroso de Matos M, de Araújo Barros Cobra HA, Cavanellas N, Branco de Sousa E, Barretto JM, et al. Surgical treatment of chronic rupture of the quadriceps using a modified Pulvertaft weave technique. *Arthrosc Tech* 2019;8:e1163-e1169.
- Kunze KN, Burnett RA, Shinsako KK, Bush-Joseph CA, Cole BJ, Chahla J. Trapezoidal Achilles tendon allograft plug for revision quadriceps tendon repair with a large tendon defect. *Arthrosc Tech* 2019;8:e1031-e1036.
- Maffulli N, Papalia R, Torre G, Denaro V. Surgical treatment for failure of repair of patellar and quadriceps tendon rupture with ipsilateral hamstring tendon graft. *Sports Med Arthrosc Rev* 2017;25:51-5.

6. Petri M, Dratzidis A, Brand S, Calliess T, Hurschler C, Krettek C, et al. Suture anchor repair yields better biomechanical properties than transosseous sutures in ruptured quadriceps tendons. *Knee Surg Sports Traumatol Arthrosc* 2015;23:1039-45.
7. Jimenez A, Bedeir YH, Hasselfeld KA, Hasselfeld KA, Branam BR. Novel repair of a quadriceps tendon rupture after a total knee arthroplasty using gracilis and semitendinosus autografts. *Knee* 2020;27:1446-50.
8. Forslund J, Gold S, Gelber J. Allograft reconstruction of a chronic quadriceps tendon rupture with use of a novel technique. *JBJS Case Connect* 2014;4:e42-e2.
9. Karas V, Sherman S, Hussey K, Baker C 3rd, Bach B Jr, Cole B, et al. Allograft reconstruction for extensor mechanism injuries. *J Knee Surg* 2014;27:489-96.
10. Maffulli N, Spiezia F, La Verde L, Rosa MA, Franceschi F. The management of extensor mechanism disruption after total knee arthroplasty: A systematic review. *Sports Med Arthrosc Rev* 2017;25:41-50.
11. Wise BT, Erens G, Pour AE, Bradbury TL, Roberson JR. Long-term results of extensor mechanism reconstruction using Achilles tendon allograft after total knee arthroplasty. *Int Orthop* 2018;42:2367-73.
12. Lamberti A, Loconte F, Spinarelli A, Baldini A. Bilateral extensor mechanism allograft reconstruction for chronic spontaneous rupture: A case report and review of the literature. *JBJS Case Connect* 2019;9:e0058.
13. Nazarian DG, Booth RE Jr. Extensor mechanism allografts in total knee arthroplasty. *Clin Orthop Relat Res* 1999;(367):123-9.
14. Paez CJ, Rebolledo BJ. Suture anchor repair with V-Y plasty and Achilles allograft augmentation for chronic quadriceps tendon injury. *Arthrosc Tech* 2020;9:e1033-e1038.