



Low-dose vancomycin-loaded cement spacer for two-stage revision of infected total hip arthroplasty

Ömür Çağlar, MD¹, Mazhar Tokgözoğlu, MD¹, Rahmi C. Akgün, MD², Bülent Atilla, MD¹

¹Department of Orthopedics and Traumatology, Hacettepe University Faculty of Medicine, Ankara, Turkey

²Department of Orthopedics and Traumatology, Başkent University Faculty of Medicine, Ankara, Turkey

Total hip arthroplasty (THA) is one of the most successful procedures achieving the mobility of the patient with a dramatic pain relief. However, infection after THA continues to be a major problem. The infection rate after primary hip arthroplasty is reported to be between 0.7-3%. Periprosthetic joint infection is the third most common cause of failure after THA, representing 14.8% of all hip revisions.^[1-3]

The treatment of an infected arthroplasty still continues to evolve and optimal treatment strategy is yet to be determined. Regarding the treatment protocols in the literature, wide debridement with retention of the components, intravenous antibiotics suppression, one- or two-stage revision arthroplasty and girdle-stone resection have been reported with various success rates.^[4-8]

For chronic infections, the most commonly recommended treatment is implantation of an antibiotic-loaded spacer as a temporary implant

Received: May 12, 2020

Accepted: June 20, 2020

Published online: September 11, 2020

Correspondence: Ömür Çağlar, MD. Hacettepe Üniversitesi Tıp Fakültesi Ortopedi ve Travmatoloji Anabilim Dalı, 06100 Sıhhiye, Ankara, Türkiye.

E-mail: ocaglar@hacettepe.edu.tr

DOI: 10.5606/ehc.2020.76108

Citation: Çağlar Ö, Tokgözoğlu M, Akgün RC, Atilla B. Low-dose vancomycin-loaded cement spacer for two-stage revision of infected total hip arthroplasty. Jt Dis Relat Surg 2020;31(3):449-455.

©2020 All right reserved by the Turkish Joint Diseases Foundation

This is an open access article under the terms of the Creative Commons Attribution-NonCommercial License, which permits use, distribution and reproduction in any medium, provided the original work is properly cited and is not used for commercial purposes (<http://creativecommons.org/licenses/by-nc/4.0/>).

ABSTRACT

Objectives: This study aims to evaluate the success rate in terms of eradication of infection and long-term outcomes of two-stage revision arthroplasty with spacers loaded with low-dose vancomycin alone for the treatment of an infected hip arthroplasty.

Patients and methods: The records of 42 two-stage exchange arthroplasty patients (16 males, 26 females; mean age 61 years; range, 30 to 80 years) treated between January 1999 and January 2009 were included in this retrospective study. In the first stage, following removal of the prosthesis and debridement, a spacer consisting of 1 g of vancomycin per 40 g of cement was placed in the infected joint space. Patients received six weeks of intravenous antibiotics according to intraoperative cultures. After cessation of systemic antibiotic treatment, with normal C-reactive protein and erythrocyte sedimentation rate levels, second stage surgery with cementless components was performed.

Results: The mean follow-up duration was seven (range, 3 to 13) years. Two patients (4.7%) developed re-infection after two-stage reimplantation and one patient underwent a resection arthroplasty after repeated debridements. Five years of survival was 92.9% with Kaplan-Meier survival analysis.

Conclusion: For chronic infected total hip revisions, two-stage revision arthroplasty with low-dose vancomycin impregnated cement spacers have comparable re-infection and success rates. Low-dose vancomycin promotes effective infection control and reduces antibiotic toxicity.

Keywords: Antibiotic-loaded cement spacer, periprosthetic infection of the hip, two-stage revision, vancomycin.

known as two-stage revision protocol.^[9] Cement spacers help to achieve higher eradication rates of infection while maintaining the mobility of the patient and adequate soft tissue tension around the joint.^[10-14] However, the optimum dose of a specific antibiotic to be mixed with bone cement has not been precisely determined yet. There are large variations for the doses that are between 2.4 g of tobramycin with 1 g of vancomycin per 40 g of cement to 4.6 g of tobramycin with 4 g of vancomycin per 40 g of cement.^[15] In this point of view, efficient and safe

antibiotics concentration is mandatory in the loaded spacer. The well-defined high doses of antibiotics administration in the literature have indefinite release properties that may alter potential antibiotic-related side effects. Although not common, kidney or hepatic toxicity and severe allergic reactions are some of these complications of the high dose antibiotic-loaded spacers, worthy of notice.^[16]

Although these are relatively rare cases, reducing the current recommended high dose of antibiotics within the cement spacers should be an option particularly in the patients with pre-existing medical co-morbidities. Considering these, since 1999, low-dose vancomycin-added bone cement protocol has been used in our clinic. In this study, we aimed to evaluate the success rate in terms of eradication of infection and long-term outcomes of two-stage revision arthroplasty with spacers loaded with low-dose vancomycin alone for the treatment of an infected hip arthroplasty.

PATIENTS AND METHODS

The records of 42 patients (16 males, 26 females; mean age 61 years; range, 30 to 80 years) with infected THA who were treated by two-stage exchange revision with low-dose vancomycin-loaded spacer were analyzed. Patients treated between January 1999 and January 2009 at Hacettepe University Faculty of Medicine with clinical, laboratory and radiological data with a minimal follow-up duration of three years after reimplantation were included in the retrospective study. There were no patients prone to infection such as having a history of malignancy or being on immunosuppressive drug therapy during the study period. The study protocol was approved by the Hacettepe University Faculty of Medicine Ethics Committee (January 2015, number: GO15/16-29). A written informed consent was obtained from each patient. The study was conducted in accordance with the principles of the Declaration of Helsinki.

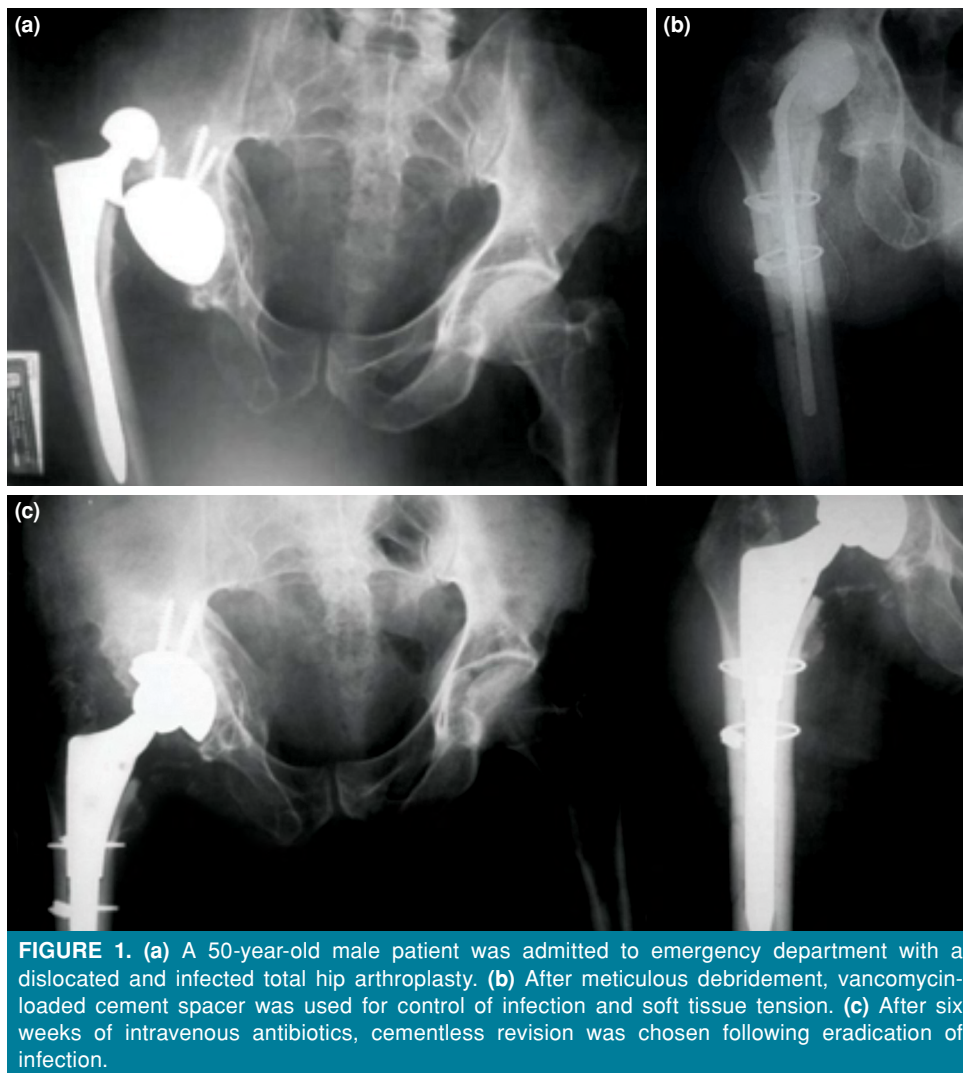
Periprosthetic infection was diagnosed according to the following signs: a draining sinus tract, a positive synovial fluid culture or periprosthetic tissue culture positivity, intraoperative purulence, histopathologic criteria of acute inflammation [at least 10 polymorphonuclear leucocytes per low-power magnification field ($\times 400$)] on light microscopy.^[2,17] The diagnosis of prosthesis infection was typically based on combination of the factors. Patients with negative cultures were regarded as infected when there was a purulent wound discharge or draining sinus. We used serial plain radiographs for the evaluation and routine follow-up of our

patients. Compared to prior X-rays, early loosening, signs of osteolysis, endosteal scalloping, or periosteal reaction as focal lysis around the component were also suggestive for infection. Magnetic resonance imaging was ordered to see the abscess formation at periprosthetic tissue in cases with positive laboratory findings. A C-reactive protein (CRP) (0-0.8 mg/dL) level persistently above 1 mg/dL and erythrocyte sedimentation rate (ESR) (0-20 mm/h) greater than 30 mm/h were considered to be highly suggestive for prosthetic infection on otherwise healthy patient when combined with unexplained chronic pain at the involved hip.

All operations were performed in lateral decubitus position using posterior-lateral approach. The first stage consisted of removal of the prosthesis, meticulous debridement of all infected and necrotic tissues, irrigation with at least 9 L saline solution and afterwards implantation of the hand-made antibiotic-loaded spacer. All of the spacers consisted of 1 g of vancomycin added to 40 g of polymethyl methacrylate cement powder and mixed well before pouring the liquid. Two packs of cement were routinely used: one for the head of the spacer and the other for the stem. Cements were used according to the size of the remaining defect after implant removal and the discarded cement was not taken into account.

After the first stage, intravenous antibiotics were administered for at least six weeks postoperatively according to isolated organism by means of intraoperative cultures. The patients were encouraged to walk toe-touch on crutches until they received the final prosthesis. Active ambulation and range of motion exercises were encouraged. The systemic antibiotics treatment and the follow-up of the patients were performed with the consultation of the infection control committee. All patients were hospitalized during the intravenous (IV) antibiotics period usually six weeks after the spacer application. The ESR and CRP levels were checked once a week. The course of the levels was supposed to decrease during the follow-up time. If the levels were still high for CRP after three weeks and ESR after six weeks or the levels were increasing despite debridement and IV antibiotic treatment, aspiration of the joint could be considered. If these tests were within normal levels after the sixth week, then the patients were discharged and followed bi-weekly by the same laboratory investigation for another six weeks but this time without antibiotics.

The second stage of the procedure was performed when all the laboratory parameters (CRP, ESR) used for infection criteria were constantly remaining at normal levels. Cementless fixation was the choice for



all patients in the second stage for the femoral side. On the acetabular reconstruction, cementless fixation was aimed whenever possible (Figure 1).

However, if the existing bone defects did not provide secure primary fixation, then we used reconstruction cages with all polyethylene cemented acetabular components. Acetabular reconstruction was performed with cages in 12 patients and in that situation vancomycin was added (1 g/40 g) in the cement.

The patients were followed-up by clinical examinations and laboratory screening (ESR and CRP) at six weeks, three months, six months, one year and yearly thereafter. The functional status of the patients was evaluated before the operation, during the interim period and the follow-up visits with Harris Hip Score (HHS). Radiographic evaluation was also performed with anteroposterior and lateral views of the hip.

Statistical analysis

All statistical analysis was performed using the SPSS version 11.5 software (SPSS Inc. Chicago, IL, USA). The distribution of continuous variables was evaluated by the Shapiro-Wilk test. Descriptive statistics for continuous variables were shown as mean \pm standard deviation or median (minimum-maximum) and for categorical variables were shown as the number of patients and percentage (%). Kaplan-Meier survival analysis was used for the evaluation of the survival. Revision of the prosthetic components or recurrence of infection was regarded as the end point.

RESULTS

The median follow-up duration was seven (range, 3 to 13) years. The mean interval between the first stage and the final implantation was 153

(range, 45 to 330) days. Three patients underwent second stage without having a holiday period which usually took an additional six weeks as a part of our protocol. These patients had mechanical problems with the spacers (two dislocation and one breakage) leading to immobilization of the patients with a painful joint that forced us to perform an early second stage. The infection was under control with normal infection parameters after adequate administration of antibiotics with isolated microorganism, and then the revision surgery was scheduled on an urgent basis for those patients. On the other hand, four patients who underwent a second debridement due to resistant infection before reimplantation had the longest interim period between two stages.

The laboratory parameters (CRP, ESR) preoperatively and before the second stage of the procedure, used as infection criteria, are documented in Table I. Five patients without any clinical sign of infection who had high CRP levels after 6 weeks of IV antibiotic treatment were treated according to the protocol.

At the time of the presentation and during the first stage, multiple cultures were taken for microbiological analysis. No organisms were isolated in 35% of the cases, whereas at least one microorganism was detected in 42% of the cases. Causative microorganisms are shown in Table II.

After the first stage, despite continuous antibiotics administration, persistent infection was observed in five (11.9%) patients. Those patients underwent a second debridement and a spacer exchange; four of them fulfilled the requirement criteria and were regarded as infection free after the second debridement and at their follow-up prior to reimplantation. One patient (2.3%) with persistent infection continued to have high laboratory tests despite a second debridement, refused further debridement, and therefore underwent a Girdlestone procedure.

Two patients (4.7%) had failed due to recurrent infections following reimplantation and underwent a resection arthroplasty as a salvage solution. Thus five-year survival after the final implantation was 92.9% with Kaplan-Meier survival analysis for the rest of the patients. To date, 39 of 42 patients in this series were successfully treated with low-dose antibiotics protocol (Table III).

Clinical evaluation revealed good functional outcomes: the mean preoperative HHS of 48.8 increased to 83.8 at the last follow-up visit. Radiographic investigations revealed stable prosthesis without major radiolucency or migration in 39 cases. The remaining three patients had either resistant or recurrent infections with early loosening of the components and progressive osteolysis.

| | Preoperative (n=42) | | Postoperative (n=42) | |
|---------------------------------------|---------------------|---------|----------------------|---------|
| | Median | Min-Max | Median | Min-Max |
| Erythrocyte sedimentation rate (mm/h) | 76 | 23-124 | 15 | 2-46 |
| C-reactive protein (mg/dL) | 7 | 2-48 | 0.6 | 0.1-2.2 |
| Follow-up (year) | - | - | 7 | 3-13 |

Min: Minimum; Max: Maximum.

| Isolated microorganism | n | % | Mean±SD |
|-----------------------------------|----|------|-----------|
| Not isolated | 15 | 35.7 | 64.8±6.8 |
| More than one microorganism | 9 | 21.4 | 59.6±12.6 |
| <i>Staphylococcus epidermidis</i> | 8 | 19.0 | 62.5±12.7 |
| Others* | 8 | 19.0 | 54.3±16.7 |
| <i>Enterococcus faecalis</i> | 2 | 4.76 | 68.5±2.5 |

SD: Standard deviation; * *Staphylococcus hominis*, *Staphylococcus lugdunensis*, *Klebsiella pneumoniae*, *Pseudomonas aeruginosa*, *Proteus mirabilis*, *Enterococcus faecium*, *Enterobacter aerogenes*, and *Enterococcus casseliflavus*.

TABLE III
Results of low-dose two-stage treatment of periprosthetic infection

| | n | % | |
|---------------------------------|----|------|--|
| Persistent infection | 5 | 11.9 | Persistent, 4 of them were infection free after second debridement |
| Re-infection after second stage | 2 | 4.7 | Resection arthroplasty |
| Reimplantation failure | 1 | 2.3 | |
| Five years of survival | 39 | 42 | Survival analysis (92.9%) |

Postoperatively, two (4.7%) patients had dislocation and one of them required an open reduction and subsequent acetabular revision due to component malposition. Two (4.7%) patients had sciatic nerve palsy after the second stage that healed spontaneously after one year.

DISCUSSION

Prosthetic joint infection is a serious complication of THA and to overcome this devastating complication, two-stage exchange arthroplasty has been accepted as the gold standard. The successful treatment of an infected THA consists of eradication of the infection while maintaining optimal function of the joint. In this context, the reported success rates for two-stage exchange protocol range between 65% and 96% in the literature.^[18,19] The success rate (92.9%) from this study is in accordance with the previous literature.

In a recent systematic review, comparing single-stage to two-stage exchange arthroplasty, the mean pooled proportion of recurrence of infection was 9% [95% confidence interval (CI): 8-11] in two-stage hip exchange (3,679 cases, 74 studies).^[20] In accordance to this data, in a meta-analysis by Kunutsor et al.,^[21] the re-infection outcome following two-stage revision of the infected hip prosthesis was reported as 7.9% (95% CI: 6.2-9.7). Our results indicate much lower rates (4.7%) of re-infection than previously reported.

Isiklar et al.^[13] implanted 4 g to 6 g of vancomycin-loaded spacer during the interim period of two-stage exchange arthroplasty. All of the patients were infection free after two years of follow-up, while longer follow-up has not been reported. Cabrita et al.^[22] reported a success rate of 89.1% in their study with only vancomycin-loaded cement spacer.

In a recent article by Wang et al.,^[19] reimplantation rate after two-stage exchange arthroplasty was retrospectively evaluated. Among 616 patients (237 hips, 379 knees), 111 (18%) did not receive reimplantation with a minimum follow-up of one year.

The most common reasons for reimplantation failure were unwillingness to proceed with reimplantation, undergoing salvage procedures, and patients who were medically unfit for reimplantation. In our study, the reimplantation failure rate was only 2.3%. Only one patient underwent salvage procedure after multiple debridements. Our results showed lower rates of reimplantation failure than one of the larger series from the literature.^[19]

Spacers are available commercially as pre-formed implants or they can be prepared manually in the operating room by the surgeons. The release of antibiotics from bone cement usually follows a biphasic pattern, with high early release in the first 24 hours from the surface of the spacer then followed by a gradual release over the following days.^[23,24] The elution of the antibiotics from bone cement in high concentrations is an important step in healing. The above reported success rates of two-stage revision hip arthroplasty are established by high levels of local antibiotic concentrations, typically vancomycin and aminoglycosides, from the cement spacers after an adequate debridement and prosthesis removal. The suggested dosage is 3.6 g antibiotic per 40 g of bone cement.^[25,26] To our knowledge, this is the first study reporting two-stage revision arthroplasty with single low-dose antibiotic-loaded spacer. In our study, the dose of antibiotics used in spacers (1 g vancomycin per 40 g of bone cement) is very low compared to the previous data. Our results indicate that such low doses are as effective as previously applied high concentrations in terms of success and re-infection rates.

Although high concentration of antibiotics in the surgical area in the first few days after implantation is a desired effect for tissue healing, the safe and effective concentrations of local antibiotics to abstain from serious complications have not been published yet. The reported cases of acute renal failures during treatment of an infected total knee or hip arthroplasty with cement spacers containing high dose antibiotics are of concern. The cement

spacers containing gentamycin, vancomycin, or combinations of these antibiotics have contributed significantly to acute renal failure.^[27,28] Despite the reports without any toxic effects, numerous papers have been published regarding the systemic side effects.^[16]

Likewise in our department, before low-dose vancomycin protocol, three of our patients had postoperative renal failure and one had red man syndrome due to vancomycin allergy, after two-stage revision protocols with vancomycin typically more than 2 g per patch. Two of the patients were not able to survive from renal failure. Afterwards, we have adopted the low-dose protocol for safety and since then we did not encounter any such complications.

A concern may arise on our protocol with empirical and routine selection of vancomycin as an antibacterial agent while disregarding the microbiologic data. Preoperative isolation of the etiologic agent of periprosthetic infections is universally known to be a problem due to various factors and our negative culture rate remained around 30% during the study period in clinically proven infected cases according to the given criteria. We have chosen vancomycin because it is known as a potent agent against *Staphylococcus (S.) aureus* and *S. epidermidis* that are the predominant organisms of infection after THA.^[4] It has been reported that 96% of the causing bacteria was found to be sensitive to vancomycin.^[29] In a recent study, we have tested the cement loaded with 1 g of vancomycin with the bacteria assayed from infected arthroplasty patients in laboratory setting with plain cement. The low-dose loaded cement was effective in more than 77.5% of the cases including gram-negative bacillus. The cement was effective in all of the cases with *S. species*.^[30]

Few experimental data described the *in vivo* release of antibiotics beyond the first 48 hours of prosthesis implantation. We presume that the majority of the loaded antibiotics were released within the first two days after the implantation and this explains the high incidence of antibiotic toxicity during that period.^[16,31] Initial high release is ultimately important to eliminate surface colonization of bacteria and allow host fibroblasts to win the “race for surface” and we think that 1 g of vancomycin is also sufficient for this goal. Afterwards, systemic antibiotics therapy took place to eradicate the re-colonization of the bacteria at neighboring tissues and further local release becomes less important.^[31,32]

There are some limitations that need to be acknowledged regarding the present study. First,

we were unable to isolate the causative organism in each case for definitive diagnosis. However, one of the advantages of implementing a two stage revision protocol is the high success rates of the procedure in both culture negative and positive patients.^[33] Second, immediate postoperative serum concentrations of vancomycin might have been detected with blood samples in order to determine systemic overload. Third, we have not calculated the exact amount of antibiotic dose locally administrated in the second stage and each patient has received a variable amount of vancomycin according the cement mantle implanted within each bone defect.

In conclusion, in the literature, the recommendations for antibiotic impregnation of cement spacers are based solely on the clinical experience. We infer that the success rate and long-term outcomes of two-stage revision arthroplasty with spacers loaded with low-dose vancomycin alone are comparable to arthroplasty with high dose/combined antibiotic-loaded spacers. Low-dose antibiotics therapy promotes effective infection control and may reduce antibiotic toxicity.

Declaration of conflicting interests

The authors declared no conflicts of interest with respect to the authorship and/or publication of this article.

Funding

The authors received no financial support for the research and/or authorship of this article.

REFERENCES

- Huerfano E, Bautista M, Huerfano M, Bonilla G, Llinas A. Screening for Infection Before Revision Hip Arthroplasty: A Meta-analysis of Likelihood Ratios of Erythrocyte Sedimentation Rate and Serum C-reactive Protein Levels. *J Am Acad Orthop Surg* 2017;25:809-17.
- Ting NT, Della Valle CJ. Diagnosis of Periprosthetic Joint Infection-An Algorithm-Based Approach. *J Arthroplasty* 2017;32:2047-50.
- Ong KL, Kurtz SM, Lau E, Bozic KJ, Berry DJ, Parvizi J. Prosthetic joint infection risk after total hip arthroplasty in the Medicare population. *J Arthroplasty* 2009;24(6 Suppl):105-9.
- Garvin KL, Hanssen AD. Infection after total hip arthroplasty. Past, present, and future. *J Bone Joint Surg [Am]* 1995;77:1576-88.
- Barberán J, Aguilar L, Carroquino G, Giménez MJ, Sánchez B, Martínez D, et al. Conservative treatment of staphylococcal prosthetic joint infections in elderly patients. *Am J Med* 2006;119:993.e7-10.
- Romanò CL, Manzi G, Logoluso N, Romanò D. Value of debridement and irrigation for the treatment of periprosthetic infections. A systematic review. *Hip Int* 2012;22 Suppl 8:S19-24.
- Sukeik M, Haddad FS. Periprosthetic joint infections after total hip replacement: an algorithmic approach. *SICOT J* 2019;5:5.

8. Nguyen M, Sukeik M, Zahar A, Nizam I, Haddad FS. One-stage Exchange Arthroplasty for Periprosthetic Hip and Knee Joint Infections. *Open Orthop J* 2016;10:646-53.
9. Leonard HA, Liddle AD, Burke O, Murray DW, Pandit H. Single- or two-stage revision for infected total hip arthroplasty? A systematic review of the literature. *Clin Orthop Relat Res* 2014;472:1036-42.
10. Haddad FS, Muirhead-Allwood SK, Manktelow AR, Bacarese-Hamilton I. Two-stage uncemented revision hip arthroplasty for infection. *J Bone Joint Surg [Br]* 2000;82:689-94.
11. Masri BA, Panagiotopoulos KP, Greidanus NV, Garbus DS, Duncan CP. Cementless two-stage exchange arthroplasty for infection after total hip arthroplasty. *J Arthroplasty* 2007;22:72-8.
12. Fehring TK, Calton TF, Griffin WL. Cementless fixation in 2-stage reimplantation for periprosthetic sepsis. *J Arthroplasty* 1999;14:175-81.
13. Isiklar ZU, Demirörs H, Akpınar S, Tandogan RN, Alparslan M. Two-stage treatment of chronic staphylococcal orthopaedic implant-related infections using vancomycin impregnated PMMA spacer and rifampin containing antibiotic protocol. *Bull Hosp Jt Dis* 1999;58:79-85.
14. Kılınç S, Tunç T, Pazarıcı Ö, Sümer Z. Research into biocompatibility and cytotoxicity of daptomycin, gentamicin, vancomycin and teicoplanin antibiotics at common doses added to bone cement. *Jt Dis Relat Surg* 2020;31:328-34.
15. Atıcı T, Şahin N, Çavun S, Özakin C, Kaleli T. Antibiotic release and antibacterial efficacy in cement spacers and cement beads impregnated with different techniques: In vitro study. *Eklem Hastalik Cerrahisi* 2018;29:71-8.
16. Anagnostakos K. Therapeutic Use of Antibiotic-loaded Bone Cement in the Treatment of Hip and Knee Joint Infections. *J Bone Jt Infect* 2017;2:29-37.
17. Della Valle CJ, Scher DM, Kim YH, Oxley CM, Desai P, Zuckerman JD, et al. The role of intraoperative Gram stain in revision total joint arthroplasty. *J Arthroplasty* 1999;14:500-4.
18. Rava A, Bruzzone M, Cottino U, Enrietti E, Rossi R. Hip Spacers in Two-Stage Revision for Periprosthetic Joint Infection: A Review of Literature. *Joints* 2019;7:56-63.
19. Wang Q, Goswami K, Kuo FC, Xu C, Tan TL, Parvizi J. Two-Stage Exchange Arthroplasty for Periprosthetic Joint Infection: The Rate and Reason for the Attrition After the First Stage. *J Arthroplasty* 2019;34:2749-56.
20. George DA, Logoluso N, Castellini G, Gianola S, Scarponi S, Haddad FS, et al. Does cemented or cementless single-stage exchange arthroplasty of chronic periprosthetic hip infections provide similar infection rates to a two-stage? A systematic review. *BMC Infect Dis* 2016;16:553.
21. Kunutsor SK, Whitehouse MR, Blom AW, Beswick AD; INFORM Team. Re-Infection Outcomes following One- and Two-Stage Surgical Revision of Infected Hip Prosthesis: A Systematic Review and Meta-Analysis. *PLoS One* 2015;10:e0139166.
22. Cabrita HB, Croci AT, Camargo OP, Lima AL. Prospective study of the treatment of infected hip arthroplasties with or without the use of an antibiotic-loaded cement spacer. *Clinics (Sao Paulo)* 2007;62:99-108.
23. Moojen DJ, Hentenaar B, Charles Vogely H, Verbout AJ, Castelein RM, Dhert WJ. In vitro release of antibiotics from commercial PMMA beads and articulating hip spacers. *J Arthroplasty* 2008;23:1152-6.
24. Hendriks JG, van Horn JR, van der Mei HC, Busscher HJ. Backgrounds of antibiotic-loaded bone cement and prosthesis-related infection. *Biomaterials* 2004;25:545-56.
25. Lu J, Han J, Zhang C, Yang Y, Yao Z. Infection after total knee arthroplasty and its gold standard surgical treatment: Spacers used in two-stage revision arthroplasty. *Intractable Rare Dis Res* 2017;6:256-61.
26. Jacobs C, Christensen CP, Berend ME. Static and mobile antibiotic-impregnated cement spacers for the management of prosthetic joint infection. *J Am Acad Orthop Surg* 2009;17:356-68.
27. Dovas S, Liakopoulos V, Papatheodorou L, Chronopoulou I, Papavasiliou V, Atmatzidis E, et al. Acute renal failure after antibiotic-impregnated bone cement treatment of an infected total knee arthroplasty. *Clin Nephrol* 2008;69:207-12.
28. van Raaij TM, Visser LE, Vulto AG, Verhaar JA. Acute renal failure after local gentamicin treatment in an infected total knee arthroplasty. *J Arthroplasty* 2002;17:948-50.
29. Fulkerson E, Valle CJ, Wise B, Walsh M, Preston C, Di Cesare PE. Antibiotic susceptibility of bacteria infecting total joint arthroplasty sites. *J Bone Joint Surg [Am]* 2006;88:1231-7.
30. Guray BA. Effect of Low-Dose Vancomycin, Gentamicin and Boric Acid Containing Bone Cement on bacteria cultured from Periprosthetic Joint Infection Patients [Thesis]. Ankara: Hacettepe University Faculty of Medicine; 2012.
31. Kelm J, Regitz T, Schmitt E, Jung W, Anagnostakos K. In vivo and in vitro studies of antibiotic release from and bacterial growth inhibition by antibiotic-impregnated polymethylmethacrylate hip spacers. *Antimicrob Agents Chemother* 2006;50:332-5.
32. Gristina AG. Biomaterial-centered infection: microbial adhesion versus tissue integration. *Science* 1987;237:1588-95.
33. Ibrahim MS, Twaij H, Haddad FS. Two-stage revision for the culture-negative infected total hip arthroplasty: A comparative study. *Bone Joint J* 2018;100-B(1 Suppl A):3-8.